

MORPHOMETRIC STUDY OF BICIPITAL GROOVE IN SOUTH INDIAN POPULATION AND ITS CLINICAL IMPLICATIONS

Arunkumar K R ^{*1}, Manoranjitham R ², Delhi Raj U ³, Shalini R ⁴.

^{*1,4} Assistant Professor, Department of Anatomy, Dhanalakshmi Srinivasan Medical College & Hospital, Siruvachur, Perambalur, Tamil Nadu, India.

² Professor, Department of Anatomy, Dhanalakshmi Srinivasan Medical College & Hospital, Siruvachur, Perambalur, Tamil Nadu, India.

³ Tutor, Department of Anatomy, Dhanalakshmi Srinivasan Medical College & Hospital, Siruvachur, Perambalur, Tamil Nadu, India.

ABSTRACT

Background: The bicipital groove (BG) or intertubercular sulcus lies between the greater and lesser tubercles on the proximal end of humerus. This groove acts as a useful landmark for proper placement of lateral fin of a prosthesis in shoulder replacement surgery. The variations of BG may lead to various pathologies of biceps tendon which is one of the common causes of shoulder pain. Hence this study is undertaken to examine the various morphometric parameters of BG in South Indian population.

Materials and Methods: The study was conducted on 98 dry human humeri (48 right side and 50 left side) belonging to south Indian race. The length, depth and width of BG were measured with digital vernier calliper. The opening and medial wall angles of BG were measured with help of scale and goniometer.

Results: The mean length of medial wall, lateral wall, width and depth of BG were 23 ± 4 mm, 31 ± 4 mm, 8.4 ± 0.1 mm and 5 ± 1 mm respectively. The average medial wall angle and opening angles of BG were $48.72 \pm 9.37^\circ$ and $82.9 \pm 20.5^\circ$ respectively. The supratubercular ridge of Meyer was observed in 26.5 % of humerus.

Conclusion: We hope that this study will be an important reference for anthropologists, clinical anatomists and for scientific research.

KEY WORDS: Bicipital Groove, Intertubercular Sulcus, Supratubercular Ridge, Morphometry, Humerus.

Address for Correspondence: Dr. Arunkumar KR, Assistant Professor, Department of Anatomy, Dhanalakshmi Srinivasan Medical College & Hospital, Siruvachur, Perambalur 621 113. Tamil Nadu, India. **E-Mail:** drarunb4u@gmail.com

Access this Article online

Quick Response code



DOI: 10.16965/ijar.2016.173

Web site: International Journal of Anatomy and Research
ISSN 2321-4287
www.ijmhr.org/ijar.htm

Received: 11 Mar 2016 Accepted: 04 Apr 2016
Peer Review: 11 Mar 2016 Published (O): 30 Apr 2016
Revised: None Published (P): 30 Apr 2016

INTRODUCTION

The humerus or the arm bone which extends from shoulder to elbow is the longest of long bones in the upper extremity [1]. The proximal end of humerus consists of head, lesser and greater tubercles and neck. Head is spheroidal and articulates with glenoid cavity of scapula to form gleno-humeral joint. Lesser tubercle or

tuberosity projects forward from the proximal end of humerus just beyond the head. Greater tubercle or tuberosity occupies the lateral part of proximal end whose convex lateral surface projects beyond the acromion and forms rounded contour of shoulder [2].

The intertubercular sulcus or bicipital groove (BG) is an indentation between lesser and

greater tubercles in the upper end of humerus and it continues below for about 5 cm on the anteromedial surface of the shaft of humerus [3]. This groove accommodates the long head of biceps brachii tendon (LHBT) covered by synovial sheath and ascending branch of anterior circumflex humeral artery. The sulcus presents lateral and medial walls and floor. It is bridged by the transverse humeral ligament [4] / muscle fibers of subscapularis, supraspinatus and pectoralis major [5, 6]. The lateral lip of BG receives the bilaminar insertion of pectoralis major, medial lip the teres major and floor the latissimus dorsi. The bicipital groove along with the transverse humeral ligament provides stability and aids in the smooth functioning of long head of biceps brachii and also prevents the subluxation of LHBT during the supination, flexion, and screwing biochemical movements [7]. The dimensions of the intertubercular sulcus may possibly influence the functions of surrounding structures, leading to some pathological conditions [8].

The bicipital groove forms the important landmark for placement of prosthesis in shoulder joint replacement surgery. Hence the knowledge of BG gains significance in prosthetic sizing, positioning and designing [9]. Some studies have analysed that the BG serves as a landmark for humeral head replacement in fractures of proximal end of humerus [10]. The knowledge of morphometry of BG is significant as the abnormalities of bicipital tendon and its synovial sheath have been implicated in the variety of causes shoulder pain and disability [11,12]. Few authors have studied the morphology of proximal end of humerus in various regions of the world [13-15]. Hence this study aimed at examining the various morphometric data pertaining to BG in south Indian population.

MATERIALS AND METHODS

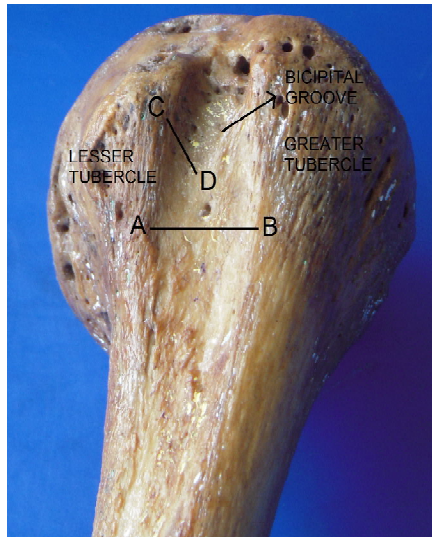
The study was done on 98 dry humeri consisting of 48 right humeri and 50 left humeri belonging to the osteological section of Anatomy department of Dhanalakshmi Srinivasan medical college, Perambalur, Tamilnadu, India, after getting approval from the Institutional ethical committee. The age and sex

of the bones were not determined. The bones with external deformities were excluded from the study. The lengths of the humeri were measured with the help of osteometric board. The length of the lateral wall and medial walls, width and depth of BG were measured with a digital vernier calliper. The anteroposterior and transverse widths were measured at the surgical neck of humerus. The depth of BG was measured at the midpoint of lesser and greater tubercles. The opening angle (OA) and medial wall angles (MWA) were measured with help of goniometer and scale. All these data were noted down separately for both right and left humeri. The presence of supratubercular ridge of humerus was also been examined. Supratubercular ridge was described by Meyer in 1928 [16]. It is defined as a bony protuberance extending proximally from the lesser tuberosity more than the half the distance to the head of the humerus. It allows the tendon of long head of biceps a more gradual change in direction when it enters the bicipital groove by raising and forcing it laterally. It prevents the medial displacement of bicipital tendon.

RESULTS

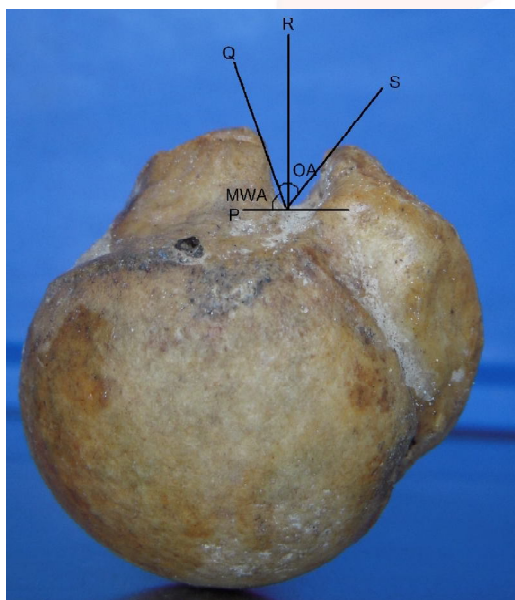
The data were presented as mean \pm standard deviation as shown in Table 1. The mean length of medial wall of BG on right side was 23 ± 3 mm and that on left side was 24 ± 5 mm. The mean length of lateral wall of BG on right side was 30 ± 2 mm and on left side was 32 ± 6 mm. The mean length of humerus on right side (30.68 cm) was almost same as that on the left side (30.38 cm). The average transverse width and antero posterior width of right humeri was 24.9 mm and 22.0 mm respectively and on left humeri was 21.4 mm and 24.2 mm respectively. The average length of BG corresponds to 27.2% of the total length of humerus and average width of BG is 47.4% of the average width of humerus. The mean depth of BG was 26.2% of the mean antero-posterior width of humerus. The average medial wall angle of BG is 48.7° . The mean opening angle of BG was 82.9° . The supratubercular ridge was observed in 26.5% of humeri, out of these 18.1% were seen on right humeri.

Fig. 1: Showing Width and Depth of Bicipital Groove.



AB – Maximum width of Bicipital Groove.
CD – Depth of Bicipital groove.

Fig. 2: Showing Opening Angle (OA) and Media Wall Angle (MWA).



PQ – Medial Wall Angle and QRS – Opening Angle.

Table 1: Various measurements of BG in present study.

Parameters	Wafae et al. 2010 [16]	Cone et al 1983 [19]	Abboud et al. 2010 [20]	Murlimanju et al 2012 [17]	S. Rajani et al. 2013 [18]	Present study
Length (mm)	81	NA	NA	84.6	84	83
Width (mm)	10.1	8.8	NA	8.5	8	8.4
Depth (mm)	4	4.3	5.1	4.4	6	5
MWA (°)	NA	56	47	NA	48.91	48.72
OA (°)	NA	NA	81	NA	82.2	82.9
MWL	NA	NA	NA	NA	23	23
LWL	NA	NA	NA	NA	32	31

BG – Bicipital groove, MWL – medial wall length, LWL – lateral wall length.

Table 2: Comparison of Morphometric data of BG among previous studies.

Parameters	Mean \pm SD in mm		
	Right	Left	Total
MWL	23 \pm 3	24 \pm 5	23 \pm 4
LWL	30 \pm 2	32 \pm 6	31 \pm 4
Width	8.7 \pm 01	8.3 \pm 04	8.4 \pm 01
Depth	5 \pm 1	6 \pm 1	5 \pm 1
Medial Wall Angle (°)	47.12 \pm 7.81	49.63 \pm 10.41	48.72 \pm 9.37
Opening Angle (°)	83.9 \pm 16.4	82.58 \pm 24.3	82.9 \pm 20.54

BG – bicipital groove, MWA – medial wall angle, OA – Opening angle, MWL – medial wall length, LWL – lateral wall length. NA – Not available

DISCUSSION

Although the BG is described in many of the anatomy and orthopaedic textbooks, the morphometric data on BG is scarce. Very few studies have been carried out on BG in various parts of the world. The morphometric knowledge of BG is a subject of clinical interest. Anatomic variations in BG may give rise to sliding of the tendon of long head of Biceps brachii. The anthropometric study of BG carried out by various authors has been compared with the present study as shown in table 2. The length of BG is similar to the results of Wafae et al. [16] but less than that of the values obtained by Murlimanju [17] and Rajani [18].

The width of BG in the present study is nearly close to that of Murlimanju and Cone et al. [19]. But lower than that of Wafae et al. The depth of BG is 5mm in our study which coincides with Abboud et al [20]. but higher than the results of Wafae et al. and Cone et al. and lower than that of Rajani [18].

The depth of BG is more on the left humeri than the right humeri in our study which is same as the findings of Rajani. Lengths of the medial wall and lateral walls of BG are 23 mm and 32 mm respectively which is nearer to the results of Rajani. The medial wall angle of BG of our study is closer to Rajani and Abboud et al. but less than that of Cone et al. The opening angle of BG in the present study is nearer to the results of Abboud et al. and Rajani. The supratubercular ridge is found in 26.5% of the humeri out of which 18.1% is on right side 8.4% on left side. In the studies of Hitchcock and Bechtol [7], the supra-trochlear ridge was markedly developed in 8%

and moderately developed in 59% of cases. They reported a definite relationship between the ridge and the biceps tendinitis. Cone and his colleagues observed this in 50% of the patient's radiographs but they opined that it was not pathologically significant. Vettivel et al. found this ridge in 88% of right humeri and 57% of left humeri and concluded that this ridge is more necessary on the right side to avoid the medial displacement of tendon of long head of biceps brachii from the BG [8].

Clinical implications of morphology of BG:

Shoulder pain affects the large population of mankind especially among elderly people. The pathology of long head of biceps brachii such as tenosynovitis, impingement, and instability of tendon at the entry into the BG is the most common causative factor for shoulder pain [21-28].

Anomalies and variations of BG have been proposed as a cause for subluxation and tendinitis of long head of biceps. The depth and width of BG are important factors in the retention of LHBT. Cone et al [19] reported that wide grooves (i.e. >17mm) are often shallow, a combination which may predispose to tendon subluxation or dislocation. Finally they suggested that a groove less than 3mm deep should be viewed with suspicion in managing pathological conditions of the shoulder. De Palma [29] propounded that a shallow BG leads to chronic trauma of impingement by the overlying acromion, rotator cuff and coracoacromial arch during shoulder rotation but a deep narrow groove is likely to constrict the tendon. Flattened medial wall of BG also predisposes to medial dislocation of biceps tendon [21]. Hitchcock and Bechtol [7] found that there is a correlation between the MWA and the probability of subluxation of LHBT. But Cone [19] on the other hand did not find the correlation between low MWA and incidence of subluxation of LHBT. Vettivel et al [8] reported the correlation between the shapes of BG with hand dominance. In their observation, they documented BG was wider and had a more acute MWA on the dominant extremity. They described this difference to greater stress passing through the tendon in the dominant limb especially during manual activities. O Donoghue [30] proposed that $MWA < 30^\circ$

predisposes subluxation whereas $MWA \geq 90^\circ$ may restrict the movement of LHBT and results in tenosynovitis.

Meyer postulated that fully developed supratubercular ridge predisposes the LHBT to instability by potentially levering it out of the groove. This well-developed ridge can also increase the contact force between LHBT and transverse humeral ligament and thereby predispose to tendinitis. According to Neviaser, supratubercular ridge displaces LHBT forward thus favouring anterior displacement. Hence Supratubercular ridge could be the cause of all primary lesions of LHBT [31].

CONCLUSION

Since biceps tendon pathology has long been implicated in shoulder pain and weakness, assessment of the bicipital groove may provide important information in evaluating patients with potential abnormality of the biceps tendon. Hence we made an attempt to report the morphometric parameters of bicipital groove in South Indian population. We believe that data obtained herein will be an important reference for scientific research and for anthropologists and orthopaedic surgeons.

ACKNOWLEDGEMENTS

We gratefully acknowledge the management of our institution and all the staff members of our department for their support and cooperation.

Conflicts of Interests: None

REFERENCES

- [1]. Bryce TH. Quain's Elements of Anatomy. Volume IV. Part 1. Eleventh edition. Longmans, Green and co. London;1915:140.
- [2]. Ellis H, Healy JC, Johnson D, Williams A. Gray's anatomy. In: Standring S, editor. The Anatomical Basis of Clinical Practice. 39th edition. Spain: Churchill Livingstone; 2006:823-32.
- [3]. Joseph J. Locomotor system. In: Hamilton WJ, editor. Textbook of Human Anatomy. London: Macmillan; 1976:19-200.
- [4]. Nevaier RJ and Nevaier TJ. Lesions of musculotendinous cuff of the shoulder—diagnosis and management. American Academy of Orthopedic Surgeons Instructional Course Lectures, St. Louis, MO, USA, 1981;30:238–257,.
- [5]. MacDonald K, Bridger J, Cash C, and Parkin I. Transverse humeral ligament: does it exist? Clinical Anatomy.2007;20(6):663–667.

- [6]. Gleason PD, Beall DP, Sanders TG et al. The transverse humeral ligament: a separate anatomical structure or a continuation of the osseous attachment of the rotator cuff? *American Journal of Sports Medicine*.2006;34(1):72–77.
- [7]. Hitchcock HH and Bechtol CO. Painful shoulder observations on the role of the tendon of the long head of the biceps brachii in its causation. *The Journal of Bone and Joint Surgery*.1948;30(2):263–273.
- [8]. Vettivel S, Indrasingh I, Chandi G, and Chandi SM. Variations in the intertubercular sulcus of the humerus related to handedness. *Journal of Anatomy*.1992;180(2):321–326.
- [9]. Robertson DD, Yuan J, Bigliani LU, Flatow EL, and Yamaguchi K. Three-dimensional analysis of the proximal part of the humerus: Relevance to arthroplasty. *Journal of Bone and Joint Surgery*.2000;82(11):1594–1602.
- [10]. Itamura J, Dietrick T, Roidis N, Shean C, Chen F, and Tibone J. Analysis of the bicipital groove as a landmark for humeral head replacement. *Journal of Shoulder and Elbow Surgery*.2002;11(4):322–326.
- [11]. Booth RE. and Marvel JP. Differential diagnosis of shoulder pain. *Orthopedic Clinics of North America*.1975;6(2):353–379.
- [12]. Slatis P and Aalto K. Medial dislocation of the tendon of the long head of the biceps brachii. *Acta Orthopaedica Scandinavica*.1979;50(1):73–77.
- [13]. Ballmer FT, Sidles JA, Lippitt LB, and Matsen FA. Humeral head prosthetic arthroplasty: surgically relevant geometric considerations. *Journal of Shoulder and Elbow Surgery*.1993;2(6):296–304.
- [14]. Iannotti JP, Gabriel JP, Schneck SL, Evans BG, and Misra S. The normal glenohumeral relationships. An anatomical study of one hundred and forty shoulders. *Journal of Bone and Joint Surgery*. 1992;74(4):491–500.
- [15]. Roberts SNJ, Foley APJ, Swallow HM, Wallace WA, and Coughlan DP. The geometry of the humeral head and the design of prostheses. *Journal of Bone and Joint Surgery*.1991;73(4):647–650.
- [16]. Wafae N, Atencio Santamaría LE, Vitor L, Pereira LA, Ruiz CR, and Wafae GC. Morphometry of the human bicipital groove (sulcus intertubercularis). *Journal of Shoulder and Elbow Surgery*. 2010;19(1):65–68.
- [17]. Murlimanju BV, Prabhu LV, Pai MM et al. Anthropometric study of the bicipital groove in Indians and its clinical implications. *Chang Gung Medical Journal* 2012;35(2):155-159.
- [18]. Singh Rajani and Singh Man. Review of Bicipital Groove Morphology and Its Analysis in North Indian Population. *ISRN Anatomy*. Volume 2013:1-7.
- [19]. Cone RO, Danzig L, Resnick D, and Goldman AB. The bicipital groove: radiographic, anatomic, and pathologic study. *American Journal of Roentgenology*. 1983;141(4):781–788.
- [20]. Abboud JA, Bartolozzi AR, Widmer BJ, and DeMola PM. Bicipital groove morphology on MRI has no correlation to intra-articular biceps tendon pathology. *Journal of Shoulder and Elbow Surgery*.2010;19(6):790–794.
- [21]. Levinsohn EM and Santelli ED. Bicipital groove dysplasia and medial dislocation of the biceps brachii tendon. *Skeletal Radiology*. 1991;20(6):419–423.
- [22]. Baumann B, Genning K, B'ohm D, Rolf O, and Gohlke F. Arthroscopic prevalence of pulley lesions in 1007 consecutive patients. *Journal of Shoulder and Elbow Surgery*.2008;17(1):14–20.
- [23]. Boileau P, Ahrens PM, and Hatzidakis AM. Entrapment of the long head of the biceps tendon: the hourglass biceps—a cause of pain and locking of the shoulder. *Journal of Shoulder and Elbow Surgery*. 2004;13(3):249–257.
- [24]. Forthman CL, Zimmerman RM, Sullivan MJ, and Gabel GT. Cross-sectional anatomy of the bicipital tuberosity and biceps brachii tendon insertion: relevance to anatomic tendon repair. *Journal of Shoulder and Elbow Surgery*.2008;17(3):522–526.
- [25]. Guckel C and Nidecker A. MR arthrographic findings in tenosynovitis of the long bicipital tendon of the shoulder. *Skeletal Radiology*. 1998;27(1):7–12.
- [26]. Jost B, Koch PP and Gerber C. Anatomy and functional aspects of the rotator interval. *Journal of Shoulder and Elbow Surgery* 2000;9(4):336–341.
- [27]. Singaraju VM, Kang RW, Yanke AB et al., Biceps tendinitis in chronic rotator cuff tears: a histologic perspective. *Journal of Shoulder and Elbow Surgery*. 2008;17(6):898–904.
- [28]. Tuckman DV and Dines DM. Long head of the biceps pathology as a cause of anterior shoulder pain after shoulder arthroplasty. *Journal of Shoulder and Elbow Surgery*. 2006;15(4):415–418.
- [29]. De Palma AF. Surgical anatomy of the rotator cuff and the natural history of degenerative periartthritis. *Surgical Clinics of North America* 1963;43:1507-1520.
- [30]. O Donoghue D. Subluxating biceps tendon in the athlete. *Clin Orthop Relat Res*. 1982;164:26-29.
- [31]. Charles A Rockwood and Fredrick A Matsen. *The Shoulder*. Fourth edition. Volume 1. Saunders Elsevier, Philadelphia. 2009:1317-1321.

How to cite this article:

Arunkumar K R, Manoranjitham R, Delhi Raj U, Shalini R. MORPHOMETRIC STUDY OF BICIPITAL GROOVE IN SOUTH INDIAN POPULATION AND ITS CLINICAL IMPLICATIONS. *Int J Anat Res* 2016;4(2):2187-2191. DOI: 10.16965/ijar.2016.173