

A COMPUTERIZED TOMOGRAPHIC STUDY OF MORPHOLOGY AND PNEUMATIZATION OF CRISTA GALLI

E. Kamala ¹, U. Vijaya Shanmugam ², T. S. Gugapriya ¹, N. Vinay kumar ^{*3}.

¹ Assistant and Associate Professor, Department of Anatomy, Chennai Medical College Hospital & Research Centre, Tiruchirapalli, Tamilnadu, India.

² Associate Professor, Department of Ophthalmology, KAP Viswanatham Government Medical College, Tiruchirapalli, Tamilnadu, India.

^{*3} Associate professor, Department of Anatomy, Government Medical College, Palakkad, Kerala, India.

ABSTRACT

Introduction: Asymmetrically divided sphenoid sinuses exhibits a variety of variation in the presentation of inter sinus septum. Previous reported range of incidence of single midline inter-sphenoid sinus septum is from 18.2% to 95%. Many studies have reported differing incidences of laterally placed septum, accessory septa, multiple septa, transverse septa and no septum in the sphenoid sinuses. Termination of inter-sphenoid septum either into internal carotid canal or into optic canal had also been shown in many studies with possibilities of high risk complications related to such termination of septum. As there exists only limited data in Indian ethnicity about the variations in presentation of inter-sphenoid sinus septum compounded by the relative high frequency of occurrence of endoscopic trans sphenoid microsurgeries, this study was done to observe variations occurring in septum of sphenoid sinuses.

Materials and Methods: A retrospective CT analysis of images obtained from 114 patients diagnosed with sinusitis during a specific study period was done by two independent observers. The age of the patients ranged from 16 - 60 years of both sexes. Patients with history of prior sinus or sphenoid surgery, facial trauma, obscured sphenoid sinus pathology were excluded.

Results: Single inter sphenoid sinus septum was seen in 83.3%. Out of this Midline, right deviation, left deviation were observed in 11.4%, 33.9% and 21.9% respectively. In 16.7 % images accessory/ multiple septum were noticed. While, absent inter sphenoid septum and transverse septum were noted each in 0.8% of images studied. The termination of inter sinus septum to internal carotid canal occurred in 27.3% and into optic canal in 48% of all images studied.

Conclusion: This study concluded that the variation in the presentation of inter-sphenoid septum and its termination at internal carotid artery canal or optic canal need to be pre operatively evaluated by surgeons for considering risk of septal resection during Trans-sphenoid endoscopic surgeries.

KEY WORDS: Sphenoid Sinus, Septum, Inter-Sphenoid Septum, Paranasal Sinus.

Address for Correspondence: Dr. N. Vinay Kumar, Associate Professor, Department of Anatomy, Government Medical College, Palakkad, Kerala, India. Phone number: +919786630481

E-Mail: vinaydr1981@gmail.com

Access this Article online

Quick Response code



DOI: 10.16965/ijar.2016.227

Web site: International Journal of Anatomy and Research
ISSN 2321-4287
www.ijmhr.org/ijar.htm

Received: 04 May 2016

Peer Review: 05 May 2016

Revised: None

Accepted: 16 May 2016

Published (O): 30 June 2016

Published (P): 30 June 2016

INTRODUCTION

The flame like Crista galli which derives its name from Latin meaning cock's comb, is located on the superior surface of the ethmoid bone. It gives attachment to the falx cerebri. The crista is one among the few structures in the paranasal region that undergoes pneumatization. At 8 weeks of intrauterine life, the mesethmoidal cartilage develops from the presphenoidal cartilage. This develops into the perpendicular plate of the ethmoid bone, the central structures of the anterior skull base and the cartilaginous crista galli [1,2]. At approximately 2 months of neonatal life, the ossification starts increasing steadily up to 14 months of age. There after it starts to slow down and finishes ossifying by 2 years of life [3].

The crista galli has been classified morphologically into 3 Levels based on the position of its base with respect to the cribriform plate as follows [2]:

Level 1- totally above the level of cribriform plate.

Level 2- more than 50% of the crista galli above the level of cribriform plate.

Level 3- less than 50% of the crista galli above the level of cribriform plate.

Studies on the pneumatization of crista report two different sinuses as possible source of pneumatization. The crista galli usually gets pneumatized by either the ethmoid complex or the ethmoid cells that have migrated into the crista galli region. This claim is based on embryological reasons. However, few studies had questioned this assumption and proved that frontal sinus too pneumatizes crista galli frequently [1,4]. It is currently believed that the process of pneumatization is either by ethmoid air cell displacement or migration of frontal sinus aeration beyond its margins into the crista galli [5].

There exists a paucity of studies on the incidence of pneumatization of the crista galli. One study showed that the formation of Nasal dermoid, a congenital midline anomaly was due to pneumatized crista galli [6]. A block in the drainage of the pneumatized crista galli into the paranasal air sinuses resulting in chronic

inflammation and the development of mucocoele has been documented [7,8].

However pneumatization of crista galli as seen in Computerized Tomography scans for diagnosis and pre surgical assessment in chronic rhino sinusitis, remains under-reported till now. Hence, this study was done to classify the observed crista galli morphologically and to note the pneumatization and connection with surrounding air sinuses in chronic rhino sinusitis population.

MATERIALS AND METHODS

Computerized Tomographic images of paranasal region at the level of visualization of olfactory fossa, from 150 chronic rhino sinusitis patients of both sexes, within the age group of 18-70 years, from the archives of department of radiology were utilized for this study. Gross nasal bone abnormality and images of patients who had previous nasal surgeries were excluded from this study.

The crista galli was classified based on the position of its base in relation to the cribriform plate of ethmoid bone. The presence of pneumatization and existence of communication with adjacent paranasal sinuses were also noted.

The study was done according to Helsinki declaration developed for the medical community by the World Medical Association after obtaining Institutional ethical clearance.

RESULTS

Fig. 1: Showing Crista Galli of Level 1.

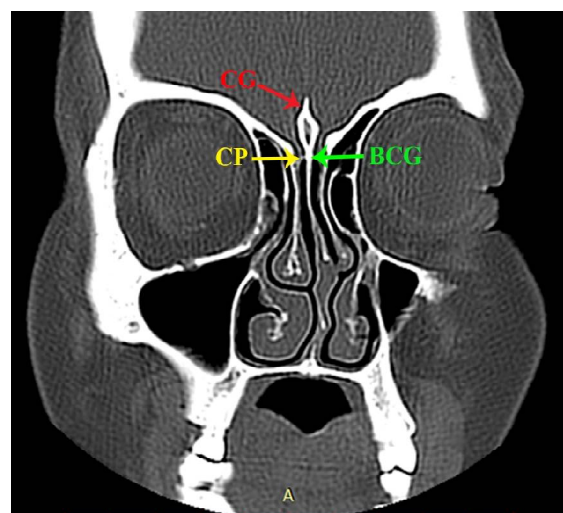


Fig. 2: Showing Crista Galli of Level 2.

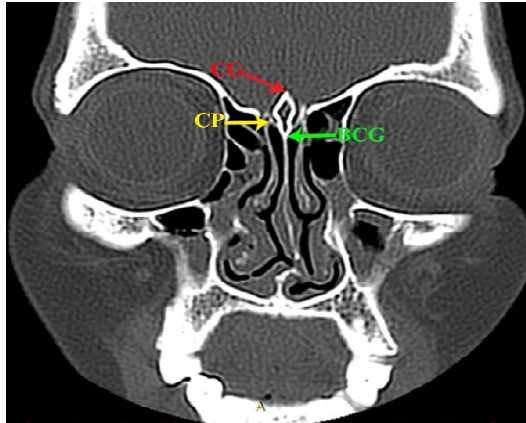


Fig. 3: Showing Crista Galli of Level 3.

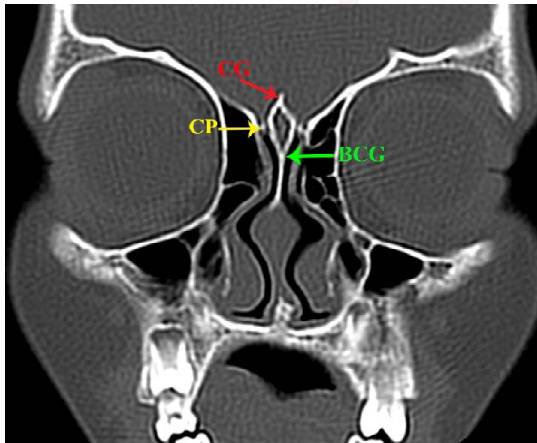


Fig. 4: Showing pneumatized Crista Galli.

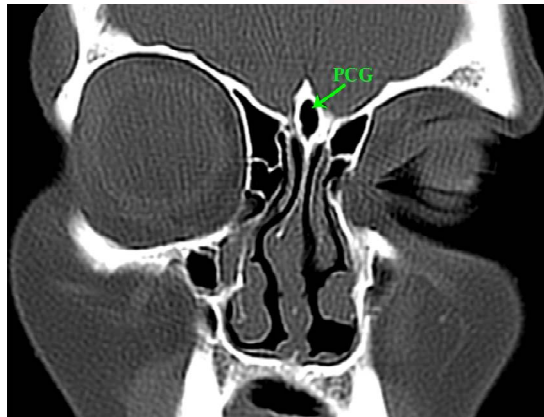
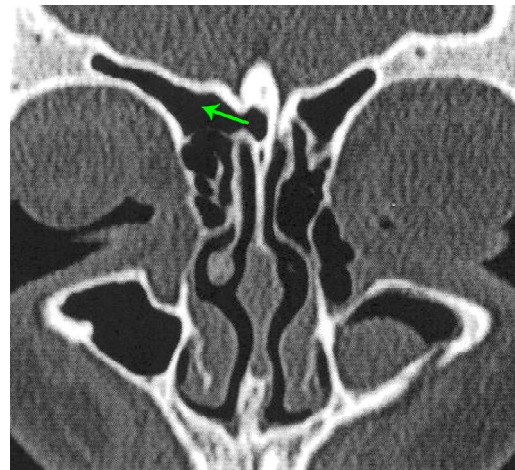


Fig. 5: Showing pneumatized Crista Galli connected with ethmoid air sinus.

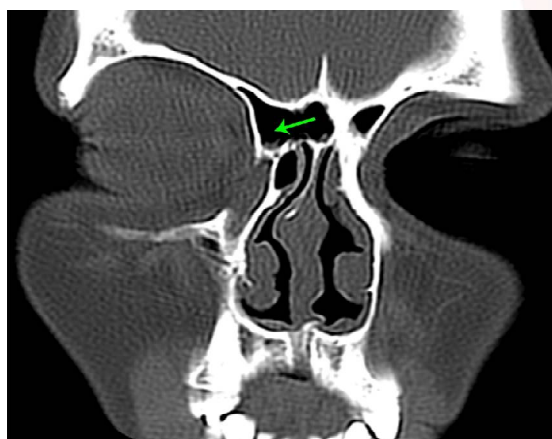

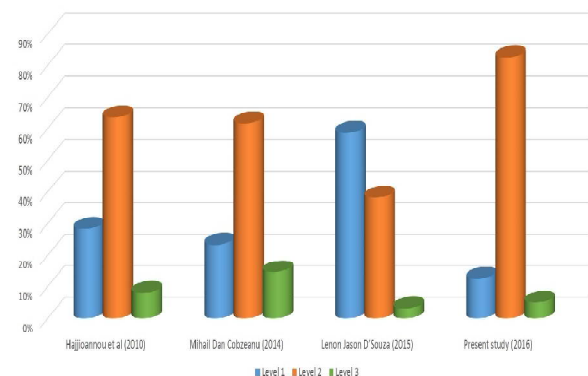
Fig. 6: Showing pneumatized Crista Galli connected with frontal air sinus.



The morphology of the crista galli in the computed tomography images showed three definite positions. Level - 1 crista galli was seen in 12.5% (Fig.1).Level 2 in 82.5% (Fig. 2) and Level 3 in only 5% of images studied (Fig. 3). Pneumatization of crista galli was seen in 12.6% of images (Fig. 4).The Pneumatized crista galli was seen in 6 males and 13 female subjects. The pneumatized crista galli was found connected to either ethmoidal or frontal air sinuses. In 20 % the ethmoid sinus and in 80% the frontal sinus was seen to pneumatize crista galli (Fig 5, 6).

DISCUSSION

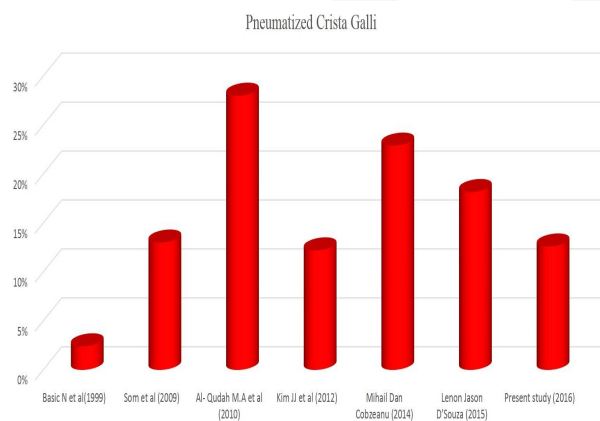
Graph 1: Distribution of the three levels of Crista Galli.



The crista galli is an endoscopic surgical landmark in frontal sinus approach and pituitary surgery. It is classified based on its' position in relation with that of the cribriform plate of ethmoid bone into three levels.² Many studies, including the present study, found that the predominant position of crista galli as Level 1, while a single study reports that Level 2 is the common position (Graph 1) [2,9,10].

The incidence of pneumatization of crista galli in relation to many associated nasal and paranasal pathologies was reported to vary from 2.4% to 28% (Graph 2) [1,9-14]. A suggestion was made to consider the pneumatized crista galli as an anatomical entity with a modified nomenclature of sinus crista galli [11]. The present study shows a substantial incidence of pneumatization and confers with the above suggestion. The authors would like to recommend the terminology as sinus crista galli for pneumatized crista galli. Need for endoscopic sinus surgery to treat the symptoms due to infective or inflammatory process in the mucosal lining of the pneumatized crista was emphasized by a study [5].

Graph 2: Incidence of Pneumatized Crista Galli.



Though the present study data shows a female predominance in pneumatization of crista galli, there exists clear paucity of gender-related data in the literature.

Few studies have acknowledged the connections of the pneumatized crista galli with the paranasal sinus without mentioning the sinus to which it is connected [1,4,10,11]. Two separate studies have stated that it is predominantly connected with frontal sinus [1,10]. The present study has also observed pneumatized crista galli predominantly connected with frontal sinus and rarely with ethmoid sinus. This observation is in contradiction to the embryological basis put forth for the occurrence of pneumatization. Hence more studies are warranted to clarify the in-situ frontal and ethmoidal connections. If both exist, the ratio between these two in the general population in comparison with sinusitis patients may elucidate the pathological co-relations of this pneumatisation

CONCLUSION

This study concludes that the presence of pneumatized crista galli and its sinus connections need to be reported by radiologist. The need for correlation between presence of pneumatization of crista galli and symptomatology is suggested by this study. Also the otolaryngologists should try to identify and consider clearing the pathological crista during endoscopic marsupialization of sinuses.

Conflicts of Interests: None

REFERENCES

- [1]. Som PM, Park EE, Naidich TP, Lawson W. Crista galli pneumatization is an extension of the adjacent frontal sinuses. *Am J Neuro-radiol.* 2009; 30:31-33.
- [2]. Hajioannou J, Owens D, Whittet HB. Evaluation of anatomical variation of the Crista galli using computed tomography. *Clin Anat.* 2010; 23:370-373.
- [3]. Belden CJ, Mancuso AA, Kotzur IM. The developing anterior skull base: CT appearance from birth to 2 years of age. *Am J Neuroradiol.* 1997; 18:811-818.
- [4]. Robinson M, Donlon D, Harrison H, Houang M, Stammberger H, Wolf G. Variations of the paranasal sinuses in Melanesians as observed by CT. *Rhinology.* 2010; 48:11-17.
- [5]. Socher JA, Santos PG, Correa VC. Endoscopic surgery in the treatment of crista galli pneumatization evolving with localized frontal headaches. *Int Arch Otorhinolaryngol.* 2013; 17(3):246-50.
- [6]. Vital D, Holzmann D. Combined endoscopic approach to the crista galli for nasal dermal sinus cysts. *J NeuroSurg B.* 2012; 73: A006.
- [7]. McLaughlin RB Jr, Rehl RM, Lanza DC. Clinically relevant frontal sinus anatomy and physiology. *Otolaryngol Clin North Am.* 2001; 34:1-22.
- [8]. Wingate J, Rechtweg JS, Grand W, Jouandet M, Balos L, Wax MK. Mucocoele of the crista galli. *J Otolaryngol.* 2001; 30:43-46.
- [9]. Mihail Dan Cobzeanu, Vasilica Baldea, Mircea Catalin Baldea, Patricia Sonia Vonica, Bogdan Mihail Cobzeanu. The anatomo-radiological study of unusual extra sinusal pneumatizations: superior and supreme turbinate, crista galli process, uncinate process. *Rom J Morphol Embryol.* 2014; 55(3):1099-1104.
- [10]. Lenon Jason D'Souza, Romina Geraldine D'Souza, Ram Shenoy Basti, Nikrish Hedge, H B Suresh. Morphometric evaluation of crista galli. *International Journal of Recent Trends in Science and Technology.* September 2015; 16(2):281-282.
- [11]. Gorazd Poje, Ranko M Iadina, Neven Stitarellic, Marcel Marjanovic Kavanaugh. Some radiological and clinical aspects of the sinus crista galli. *Rom j Rhino.* 2014; 4(13):32-36.

- [12]. Basic N, Basic V, Jukic T, et al. Computed tomographic imaging to determine the frequency of anatomical variations in pneumatization of the ethmoid bone. Eur Arch Otorhinolaryngol. 1999; 256: 69-71.
- [13]. Kim JJ, Cho JH, Choi JW, Lim HW, Song YJ, Choi SJ, Yeo NK. Morphologic analysis of crista galli using computed tomography. J Rhinol. 2012; 19(2): 91-95.
- [14]. Al- Qudah M.A. - Anatomical Variations in Sino-Nasal Region: A Computer Tomography (CT) study. J Med J. 2010; 44(3):290-297.

How to cite this article:

E. Kamala, U. Vijaya Shanmugam, T. S. Gugapriya, N. Vinay kumar. A COMPUTERIZED TOMOGRAPHIC STUDY OF MORPHOLOGY AND PNEUMATIZATION OF CRISTA GALLI. Int J Anat Res 2016;4(2):2429-2433. DOI: 10.16965/ijar.2016.227

