

A STUDY OF VARIATIONS IN THE ORIGIN OF TESTICULAR ARTERIES IN ADULT HUMAN CADAVERS WITH EMBRYOLOGICAL SIGNIFICANCE AND CLINICAL IMPORTANCE

Prathap Kumar. J ^{*1}, Kannan. S ², Shailaja Shetty ³, Radhika.P.M ¹.

^{*1} Assistant Professor, Department of Anatomy, M S Ramaiah Medical College, M S R Nagar, MSRIT post, Mathikere, Bangalore, Karnataka, India.

² Post Graduate, Department of Anatomy, M S Ramaiah Medical College, M S R Nagar, MSRIT post, Mathikere, Bangalore, Karnataka, India.

³ Professor and HOD, Department of Anatomy, M S Ramaiah Medical College, M S R Nagar, MSRIT post, Mathikere, Bangalore, Karnataka, India.

ABSTRACT

Background: The testicular artery is normally a branch of the abdominal aorta and arises about 1-2 inches below the origin of renal artery. In the present study, variations in the origin of testicular arteries and the clinical implications of these variant gonadal arteries are discussed.

Materials and Methods: Forty formalin fixed cadavers were dissected to observe for the variations in the origin of testicular arteries in the Department of Anatomy, M. S. Ramaiah Medical College, Bangalore, Karnataka, India.

Results: In 96.25% of the cases, the testicular artery was normal in origin, number and course. However, in the remaining 3.75%, variations in the origin of testicular artery were noted. i.e, testicular artery arises from renal artery in 1.25% and in 2.5% testicular artery arose from renal artery.

Conclusion: The anatomy of the testicular arteries has gained immense importance because of the technical development of operative surgery within the abdominal cavity, hence the knowledge of variations of these vessels in the renal hilar region and retroperitoneal region may greatly contribute to the success of invasive surgery and radiological procedures of this area. Precise knowledge of usual and anomalous origin of testicular arteries is essential for surgeons, anatomists, researchers and interventional radiologist.

Key words: Testicular Artery, Gonadal artery, Abdominal aorta, Renal Artery, Accessory Renal Artery, Renal Transplant, varicocele

Address for Correspondence: Dr Prathap Kumar J, Assistant Professor, Department of Anatomy, M S Ramaiah Medical College, M S R Nagar, MSRIT post, Mathikere, Bangalore-560054, Karnataka, India. **E-Mail:** dr.prathapkumar@gmail.com

Access this Article online

Quick Response code



DOI: 10.16965/ijar.2016.229

Web site: International Journal of Anatomy and Research
ISSN 2321-4287
www.ijmhr.org/ijar.htm

Received: 06 May 2016

Peer Review: 07 May 2016

Revised: None

Accepted: 07 June 2016

Published (O): 30 June 2016

Published (P): 30 June 2016

INTRODUCTION

The testicular artery is normally a branch of the abdominal aorta and arises about 1-2 inches below the origin of renal artery, Testicular

artery supplies the male gonad, i.e testis. With the increasing demand for kidney transplantation, living donor grafts and allograft with multiple renal arteries have become a necessity.

Awareness of variations of the testicular arteries becomes important during surgical procedures like varicocele and undescended testes.

In 96.25% of the cases, the testicular artery was normal in origin, number and course. However, in the remaining 3.75%, variations in the origin of testicular artery were noted. i.e, testicular artery arises from renal artery in 1.25% and in 2.5% testicular artery arose from renal artery. Variations in the origin of arteries in the abdomen, as always had been of immense interest for the surgeons, as the injury to these variant vessels can result in complications to the organs supplied by corresponding vessels. With the advent of newer radiological techniques, these variations can be identified pre-operatively and thus prevent the inadvertent complications.

The testicular arteries are two long slender blood vessels usually arise anteriorly from the abdominal aorta at the level of the second lumbar vertebra, just inferior to the origin of renal arteries. Each artery passes downwards and laterally under the parietal peritoneum into the pelvic cavity. The right testicular artery lies anterior to the inferior vena cava [1]. The testicular artery usually arises from the abdominal aorta at the level of the second lumbar vertebra, below the renal artery.

Testicular artery may originate from the renal artery or as a branch from a suprarenal or lumbar artery. In 15% of cases, the gonadal arteries arise from the renal artery, from one of the branches of the renal artery, or from a supernumerary or "accessory" renal artery. The gonadal arteries are doubled on one side, rarely on both sides. Rarely, one or both testicular arteries are absent, and the testes in this case are supplied by branches from the vesical or prostatic arteries [2]. In 5-6% of the individuals, it originates from the main or the accessory renal artery [3]. Awareness of variations of testicular arteries becomes important during surgical procedures like varicocele and undescended testis. A gonadal artery with origin from an inferior polar renal artery may be injured during the percutaneous treatment of the syndrome of pyeloureteral junction, so it becomes a major contraindication. Also, this

anatomical variation enhances the importance of the arteriography or Doppler ultrasound examination of the renal hilum [4].

Knowledge of the possible variations in the renal arterial pattern are especially important for the Nephrologist dealing with kidney retrieval and transplantation, various endourologic procedures and innumerable interventional techniques [5].

The present study has been taken up to highlight the various origins of testicular artery with their clinical importance and embryological basis and compare our observations with previous studies.

As the number of abdominal surgical interventions and radiological investigations increase, a better understanding of the variations of gonadal arteries gains importance.

MATERIALS AND METHODS

A cross-sectional study was conducted in Department of Anatomy, M S Ramaiah Medical College Bangalore. Forty formalin fixed Male cadavers aged between 50-75 years were dissected for the study and it was conducted over a period of four years, i.e., from 2012-2016. The cadavers with visible trauma, pathology or prior surgeries were excluded from the study. Routine dissection of the abdomen was carried out following the Cunningham's Manual of Practical Anatomy. After removal of lesser omentum, the proximal part of abdominal aorta and its branches were identified and periarterial sympathetic plexus was removed. After removal of stomach and pancreas, the mesentery was dissected and removed along with small intestine. The peritoneum from the posterior abdominal wall is carefully dissected and origin of testicular arteries was confirmed and it was traced. Any variations found were noted and photographed. The results were analysed and compared to previous studies.

RESULTS

In our study, 40 Cadavers were dissected. Out of 80 gonadal arteries studied, in 77 arose from abdominal aorta. Other unusual origins of testicular arteries are shown in Figures 1-4 and summarized in Table 1.

In one cadaver, Right TA arose from the Accessory RA and Left TA originated from AA in one cadaver Figure 1. In the 2nd cadaver the origin Left TA from the RA and Right TA from the AA in one cadaver Figure 2. In the 3rd cadaver origin of Left TA from the Accessory RA and Right TA from the AA Figure 3.

Fig. 1: Photograph showing the origin of Right Testicular Artery (TA) from the Accessory Renal artery (Acc. RA). AA-Abdominal Aorta; RA-Renal Artery.

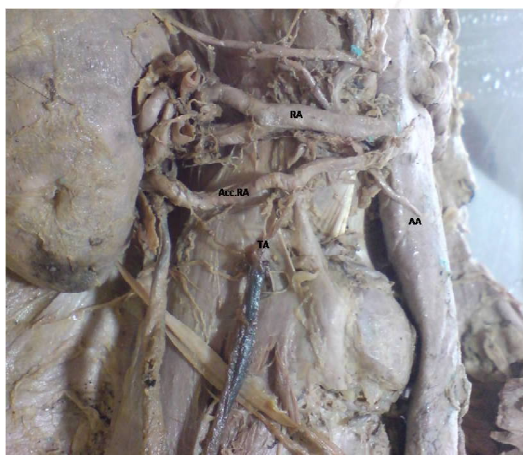

Fig. 2: Photograph showing the origin Left Testicular Artery (TA) from the Renal artery (RA). AA-Abdominal Aorta.

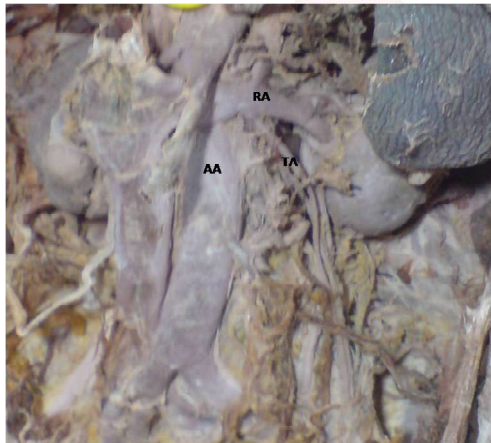


Fig. 3: Photograph showing the origin of Left Testicular Artery (TA) from the Accessory Renal artery (Acc. RA). AA-Abdominal Aorta; RA-Renal Artery.

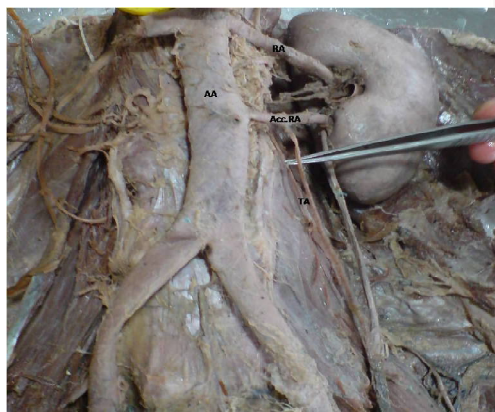


Table 1: Various site of origin of testicular arteries in the present study.

Origin	Abdominal Aorta	Right Acc. Renal Artery	Left Acc. Renal Artery	Left Renal Artery
Right TA	39/40 (97.5%)	1/40 (2.5%)	-	-
Left TA	38/40 (95%)	-	1/40 (2.5%)	1/40 (2.5%)

Table 2: Comparison of the present study of origin of testicular arteries from renal arteries with previous studies.

Authors (year)	No. of cases	Right(%)	Left(%)	Total(%)
Cauldwell and Anson (1936) [6]	232	5.6	4.3	10
Notkovich(1956) [7]	100	8.1	6.5	14.6
Pick and Anson (1941) [8]	50	10	6.1	16.1
Anson and Kurth (1955) [9]	60	3	0	3
Wadhwa and Soni (2009) [10]	30	6.6	3.3	10
Present study (2016)	80	-	2.5	2.5

DISCUSSION

The testicular arteries variations are: of their origin, course and number [11,12]. The variations of gonadal arteries are common and have been reported. The testicular artery may vary at their origin; they may be absent or may be doubled, tripled or quadrupled [13]. The origin of the inferior phrenic and suprarenal arteries from a high-origin testicular artery has also been described in the literature [11,14].

High origin of gonadal arteries from abdominal aorta has been reported in two individuals by Ozan et al.[12]. Variations in the origin, course, and branches of the testicular arteries are attributed to their embryological origin by Bhaskar PV in 2006 [15].

The first note on the embryological origin of the gonadal artery was made by Felix W in 1912 [16]. Deepthinath et al reported a double left testicular artery, in which one originated from an accessory renal artery and the other from the main renal artery [17].

The rate of anatomical variation of testicular arteries has been reported to be 4.7% and their origin was either from unusually high level of aorta or from the renal artery [18].

An additional left testicular artery has been reported by Loukas and Stewart, where the accessory left testicular artery originated from

the anterolateral wall of the descending aorta [19]. Rusu described a case of bilateral doubled testicular arteries with a left testicular arterial arch around the left renal vein [20].

Embryological significance: Felix gave embryological explanation. He stated that the developing mesonephros, metanephros, suprarenal glands and gonads are supplied by nine pairs of lateral mesonephric arteries arising from dorsal aorta. Felix divided these arteries into three groups as follows [16]:

- The first and second are cranial arteries
 - The third to fourth are middle arteries
 - The sixth to ninth are caudal arteries
- 1) Cranial group, that is located proximal to the celiac trunk of the abdominal aorta, directed posteriorly to supply suprarenal gland.
 - 2) Middle group passes towards metanephros to give rise to renal arteries.
 - 3) In the caudal group, one of the caudal arteries usually persists and differentiates into the definitive gonadal artery.

The persistence of a cranial lateral mesonephric artery results in a high-origin of the gonadal artery, probably from the suprarenal or from a more superior aortic level. The persistence of more than one arteries of the middle group results as multiple renal arteries. Thus the two renal arteries in the present study are as a result of two persisting mesonephric arteries of the middle group. Felix also stated that gonadal artery usually arises from the caudal group, but it may also arise from any of these nine mesonephric arteries.

In the present study, testicular artery arose from the accessory renal artery in 2 cases and renal artery in 1 case. The testicular artery in the present study has taken origin from the middle group of lateral mesonephric arteries [16].

Accessory renal arteries are common; they are derived from the persistence of embryonic vessels that formed during the ascent of kidney. The three sequential stages of development of kidneys are pronephros, mesonephros and metanephros, during this process the kidneys ascend from pelvic to the lumbar region. When the kidneys are situated in the pelvic cavity, they are supplied by the branches of

common iliac arteries. While the kidneys ascend to lumbar region, their arterial supply also shifts from common iliac artery to abdominal aorta. If the lower arteries fail to disappear, it can give rise to accessory renal artery.

In the present study, accessory renal artery was noted on right side in one cadaver and on the left side in another cadaver. Accessory renal arteries arise from the abdominal aorta either above or below the main renal artery and follow it to the hilum. The knowledge of these variations are important because accessory renal arteries are end arteries; therefore if an inadvertent damage to accessory renal arteries, the part of kidney supplied by it is likely to become ischaemic and necrosed [21].

The selection and persistence of a particular congenital vascular channel is dependent on various chemical agents, growth/transcription factors and haemodynamic forces [18].

The surgeons should take into account the aberrant origin and course of the gonadal arteries when operating near a renal pedicle or in the retroperitoneum. A deep knowledge of these variations and their relations to the adjacent structures is very important in avoiding the complications in operative surgery. With the advent of newer surgical and diagnostic techniques, understanding of atypical anatomical presentations gains more importance [18]. Anomalous blood vessels are always interesting from a purely scientific point of view, especially since they so often shed light on obscure problems of phylogeny and ontogeny [22]. More than one artery supplying a kidney is the most common arterial variation, and this is seen in about 24% cases [23].

Clinical Significance: Variations of the renal and testicular artery should also be considered in order to prevent acute hemorrhage due to their injury in renal hilar dissections and retroperitoneal surgical explorations. Due to the increased demand for living donor graft in renal transplants, the knowledge of such variant anatomy of the renal and gonadal arteries is an important prerequisite to successful renal transplantation [4].

With the advancement of new operative techniques within the abdominal cavity, the

anatomy of gonadal vessels has assumed much more importance. The gonadal vessels must be preserved to avoid the possible complications following damage of these vessels. Many complications may arise during laparoscopic surgery of the male abdomen and pelvis, due to unfamiliar anatomy in the operative field [23].

Knowledge of these variations will serve as a reference for avoiding clinical complications during surgery in this region [24].

CONCLUSION

The present study highlights the anatomic variation of testicular arteries and its possible embryological basis. Anatomical knowledge of the origin and course of the testicular arteries is of great importance during renal and testicular surgery. With the increasing demand for kidney transplantation, living donor grafts and allograft with multiple arteries have become a necessity [4].

The anatomy of the gonadal arteries has gained importance because of the technical development of operative surgery within the abdominal cavity, hence the knowledge of variations of vessels in the renal hilar region and retroperitoneal region may greatly contribute to the success of invasive surgery and radiological procedures of this area [25].

The awareness of such arterial variations, in relation to the renal, testicular, suprarenal and inferior phrenic arteries could be of utmost importance for the vascular surgeons and urologist and oncologist, during surgical procedures in the retroperitoneal region, in order to minimize the perioperative and postoperative morbidity related to surgical interventions and cadaveric transplantations procedures [26,27]. Thus, it becomes imperative to carefully preserve the gonadal artery in order to prevent the occurrence of any vascular troubles of the gonad.

Conflicts of Interests: None

REFERENCES

- [1]. Bannister LH, Berry MM, Collins P, eds. Gray's Anatomy. 38th ed. Edinburgh: Churchill Livingstone, 1995:1557-8, 318.
- [2]. Shoja MM, Tubbs RS, Shakeri AB, Oakes WJ; Origin of the gonadal artery- Embryological implications. Clin Anat., 2007; 20(4): 428-432.
- [3]. Bergman RA, Afifi AK, Miyauchi R. Gonadal. (Ovarian and Spermatoc or Testicular) Arteries. In: Anatomy Atlases [online]. Available at: <http://www.anatomyatlases.org/AnatomicVariants/Cardiovascular/Text/Arteries/Gonadal.shtml>. Accessed Feb 19, 2016.
- [4]. Wadhwa A. Anomalous Origin of Left Testicular Artery from Accessory Left Renal Artery: A Case Report. Sch J Med Case Rep 2014; 2(4):232-234.
- [5]. Dhar P, Lal K. Main and accessory renal arteries – A Morphological Study; Italian Journal of Anatomy & Embryology, 2005; 110(2):101-110.
- [6]. Cauldwell EW, Anson BJ. The visceral branches of the abdominal aorta: Topographical relationships. Am J Anat. 1936; 73 :27–57.
- [7]. Notkovich H. Variations of testicular and ovarian arteries in relation to the renal pedicle. Surg Gynae Obst. 1956; 103: 487–95
- [8]. Pick JW, Anson BJ. The inferior phrenic artery. Origin and suprarenal branches. Anat Rec. 1941;81:413–27.
- [9]. Anson BJ, Kurth LE. Common variations in the renal blood supply. Surg Gynae Obst. 1955; 100: 157–62.
- [10]. Wadhwa A, Soni S. A study of Gonadal Arteries in 30 Adult Human Cadaver. Clinical Medicine Insights: Reproductive Health. 2010; 41-45.
- [11]. Shinohara H, Nakatani T, Fukuo Y, Morisawa S, Matsuda T. Case with a high-positioned origin of the testicular artery. Anat Rec 1990; 226:264-6.
- [12]. Ozan H, Gümüşpalan Y, Onderoğlu S, Simpek C. High origin of gonadal arteries associated with other variations. Ann Anat 1995; 177:156-60.
- [13]. Bergman R.A, Cassell M.D, Sahinoglu K, Heidger PM Jr. Human doubled renal and testicular arteries. Ann Anat 1992;174:313-5.
- [14]. Brohi RA, Sargon MF, Yener N. High origin and unusual suprarenal branch of a testicular artery. Surg Radiol Anat 2001; 23:207-8.
- [15]. Bhaskar PV, Bhasin V, Kumar S. Abnormal branch of the testicular artery, Clin Anat, 2006, 19(6):569–570.
- [16]. Felix W., Mesonephric arteries (aa. Mesonephricae). In: Keibel F., Mall F. P. (eds), Manual of Human Embryology, vol. 2, Lippincott, Philadelphia–London, 1912, 820–825.
- [17]. Deepthinath R, Satheesha Nayak B, Mehta RB, et al. Multiple variations in the paired arteries of the abdominal aorta. Clin Anat 2006; 19:566-8.
- [18]. Pai MM, Vadgaonkar R, Rai R, Nayak SR, Jiji PJ. A cadaveric study of the testicular artery in the south indian population. Singapore Med J 2008;49: 551-555.
- [19]. Loukas M, Stewart D. A case of an accessory testicular artery. Folia Morphol (Warsz) 2004; 63:355-7.
- [20]. Rusu MC. Human bilateral doubled renal and testicular arteries with a left testicular arterial arch around the left renal vein. Rom J Morphol Embryol 2006;47:197-200.
- [21]. Nayak BS. Multiple variations of the right renal vessels. Singapore Med J 2008; 49: e153-e155.

- [22]. Gupta A, Gupta R, Singhla RK. The Accessory Renal Arteries: A Comparative Study in Vertebrates with Its Clinical Implications. J Clin Diagn Res 2011;5:970-3.
- [23]. Gupta A, Singal R, Singh D. Variations of Gonadal Artery: Embryological basis and clinical significance. Int J Biol Med Res 2011;2:1006-10.
- [24]. Diwan Y, Singal R, Diwan D, Goyal S, Singal S, Kapil M. Bilateral variations of the testicular vessels: Embryological background and clinical implications. J Basic Clin Reprod Sci 2013;2:60-2.
- [25]. Kayalvizhi I, Monisha B, Usha D. Accessory left testicular artery in association with double renal vessels: a rare anomaly. Folia Morphol. 2011; 70(4): 309–311.
- [26]. Nayak SR, Jiji PJ, D'costa S, Prabhu LV, Krishnamurthy A, Pai MM, Prakash. Multiple anomalies involving testicular and suprarenal arteries: embryological basis and clinical significance. Romanian Journal of Morphology and Embryology 2007, 48(2):155–159.
- [27]. Magotra R, Hamid S, Jabeen N, Raina S, Raina S. Anomalous left testicular artery arising from left accessory renal artery and its clinical implications. Int J Anat Res 2013;03:136-139.

How to cite this article:

Prathap Kumar. J, Kannan. S, Shailaja Shetty, Radhika.P.M. A STUDY OF VARIATIONS IN THE ORIGIN OF TESTICULAR ARTERIES IN ADULT HUMAN CADAVERS WITH EMBRYOLOGICAL SIGNIFICANCE AND CLINICAL IMPORTANCE. Int J Anat Res 2016;4(2):2434-2439. DOI: 10.16965/ijar.2016.229