International Journal of Anatomy and Research,
Int J Anat Res 2017, Vol 5(2.2):3788-90. ISSN 2321-4287
DOI: https://dx.doi.org/10.16965/ijar.2017.178

Case Report

HIGHER RIGHT KIDNEY AND PARTIAL DUPLICATION OF LEFT URETER

Chiman Kumari [1], Rohini Motwani [2], Saroj Kaler Jhajhria *[3], Neerja Rani [4], Pooja Jain [5], Khursheed Raza [6], Vidhu Dhawan [7], Seema Singh [4].

[1] Senior Resident, Department Of Anatomy, AIIMS, New Delhi, India.

[2] Assistant Professor, Department Of Anatomy, MNR Medical College & Hospital, Sangareddy (Former SR, AIIMS,New Delhi) India.

[3] Associate Professor, Department Of Anatomy, AIIMS, New Delhi, India.

[4] Assistant Professor, Department Of Anatomy, AIIMS, New Delhi,

[5] Assistant Professor, Department Of Anatomy, Government Doon Medical College, Dehradun (Former SR, AIIMS), India.

[6] Assistant Professor, Department Of Anatomy, Sridev Suman Subharti Medical College, Dehradun (Former SR, AIIMS), India.

[7] Phd Student, Department Of Anatomy, AIIMS, New Delhi, India.

ABSTRACT

During routine dissection on an adult female cadaver in the department of anatomy, AIIMS, New Delhi we report an abnormally higher level of right kidney and presence of an accessory renal artery for both the kidneys arising from anterior surface of the Abdominal Aorta. Right accessory renal artery was higher in origin. Both the accessory renal arteries entered into the lower pole of their respective kidney. Main renal arteries for both the kidneys were normal in their origin. Another important finding was the presence of duplex renal system on left side i.e. duplicated pyelocaliceal system with partially duplicated (bifid: Y shaped) ureter in the upper one third only. Right ureter was normal. Both the ureters opened in the urinary bladder with their single opening as usual. Knowledge of these developmental anomalies of the urinary system is of immense importance for not only urological conditions but also in surgeries involving renal transplant and radiological interpretation, to avoid complications and ease in management and surgical interventions.

KEY WORDS: Duplex system, Kidney, Renal artery, Ureter.

Address for Correspondence: Dr. Saroj Kaler Jhajhria, Associate Professor, Department Of Anatomy, AIIMS, New Delhi, India. **E-Mail:** sarojkaler@gmail.com

Access this Article online

Quick Response code	Web site: International Journal of Anatomy and Research ISSN 2321-4287 www.ijmhr.org/ijar.htm	
DOI: 10.16965/ijar.2017.178	Received: 08 Mar 2017 Peer Review: 09 Mar 2017 Revised: None	Accepted: 15 Apr 2017 Published (O): 31 May 2017 Published (P): 31 May 2017

INTRODUCTION

The ureter develops from the ureteric bud at about 5th week of intrauterine life. The collecting part of the kidney develops from the developing ureteric bud while the excretory part develops from the metanephric blastemal [1].

Duplication of ureter may be complete, incomplete, unilateral or bilateral. 0.8% individuals have bifid ureter, and 0.13% individuals have bilateral duplex ureter which is rare. They may fuse at any point in their course or may separately open into the urinary bladder [2].

It is more common in female, approx. 62% [3]. Bifid ureter may lead to a wide variety of clinical conditions like formation of calculi, ureterocele, uetero-vesical reflux, hydronephrosis and recurrent urinary tract infections. Accessory renal arteries (ARA) are present in 30% of population and are regarded as persistent embryonic lateral splanchnic arteries. Accessory vessels to the lower pole crossing anterior to the ureter may obstruct the ureter causing hydronephrosis [2].Therefore considering a rare occurrence of duplication, its embryological significance and clinical implications, we present a case report of higher right kidney (RK) and partial duplication of left ureter (LU) with no other associated congenital anomaly. The right kidney (RK) is situated at a lower level then the LK due to the presence of the liver in the right. Various conditions may lead to higher position of the RK than the left [8].

CASE REPORT

In routine dissection of 8 cadavers in the Department of Anatomy, AIIMS, New Delhi we observed partial duplication of LU and higher position of RK in a 63 years old female cadaver. The abdomen was exposed from the front, the viscera's retracted and the kidneys and ureters were observed in the posterior abdominal wall. Any other associated anomalies were looked for and the specimen was photographed.

In the present case, LU was partially duplicated (Bifid Ureter). The two ureters had separate pelvis coming out from the hilum separately (Figure2). They united with each other at about 3 cm from the lower pole of the LK (Figure 1). The RU was normal. Both the ureters opened into the urinary bladder normally. The RK was found higher in position than the LK by about 1cm (Figure 1, 3). ARAs were found for both the kidneys arising from the anterior surface of the AA (Figure.1). Both these arteries passed anterior to the respective ureter and entered the lower poles of their respective kidneys.Main renal arteries (RA) and Renal veins (RV) for both the kidneys were normal in their origin. There were no other gross abnormalities in the cadaver.

Knowledge of these developmental anomalies is of immense importance not only for urologists and surgeons but also for radiologists so that

Fig. 1: Posterior abdominal wall showingY-shaped bifid ureter.

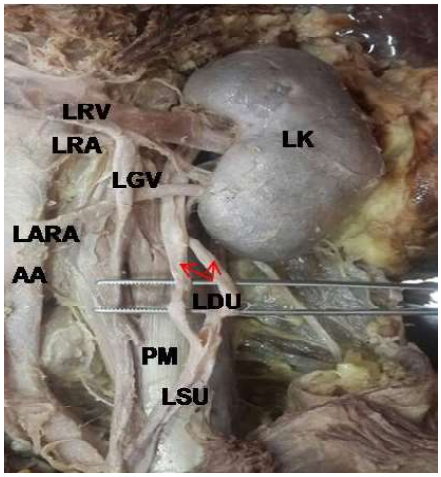

LK-Left Kidney, LRV- Left Renal Vein, LRA- Left Renal Artery, LGV-Left Gonadal Vein, LARA-Left Accessory Renal Artery, AA- Abdominal Aorta, LDU-Left Double Ureter, LSU-Left Single Ureter, PM-Psoas Major.

Fig. 2: Posterior view of the left kidney.

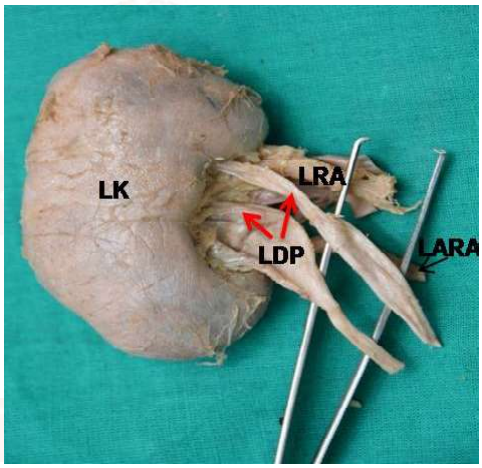

LK-Left Kidney, LDP-Left Double Pelvis, LRA-Left Renal Artery & LARA-Left Accessory Renal Artery. (Red Arrow showing Double renal pelis)

Fig. 3: Posterior abdominal wall showing Right kidney higher than the left kidney with duplicated left ureter.

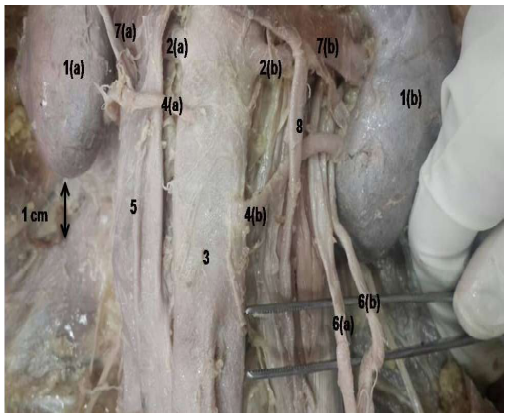

1(a)- Right Kidney, 1(b)- Left Kidney, 2(a)- Right Renal Artery, 2(b)- Left Renal Artery, 3-Abdominal Aorta, 4(a)- Right Accessory Renal Artery, 4(b)- Left Accessory Renal Artery, 5- Inferior Vena Cava, 6(a,b)- Duplicated Left Ureter, 7(a)- Right Renal Vein, 7(b)- Left Renal Vein & 8- Left Gonadal Vein.

appropriate interventions can be done before any aforementioned complications which can increase the morbidity of affected individuals. Sufficient information is still lacking regarding study of duplex system. Hence, our case report will be helpful to the clinicians to prevent any complications of urinary system and to provide appropriate treatment to the affected individuals.

DISCUSSION

Presence of duplicated ureter has been encountered by many clinicians either incidentally during cadaveric dissection or during investigating cases of urinary pathologies. It may be symptomatic or asymptomatic.

Lee *et al* reported a case of bilateral ureteric duplication in a 43 year old female who had recurrent urinary tract infections [4]. Similar finding was also reported by Karakose et al while investigating a case of acute flank pain [5]. Das et al reported bifid ureter in cadaver [11]. Again Halim *et al* reported a case of blind ending ureteral duplication in a 45 year old male (6). 0.1-3%(7) population may have a duplicated ureter.In a study done on 1625 patients, Seiichi Saito found that 81 had higher right kidney, however in each case there was some pathology either in the urinary system or some other organs or were considered congenital [8].

Out of these 81 patients, Saito found that 4 patients had congenital anomaly of which two had duplication of the pelvis. However, a duplicated ureter may cause any clinical manifestation and sometimes even used as donor ureter[12]

Presence of ARAs have also been reported by many other authors [9,10].28.3% [10] may have accessory renal artery/s reflecting the persistance of fetal arterial arrangement of the kidney.

CONCLUSION

Duplication of ureter can be detected at autopsy or as radiological finding but is associated with wide variety of clinical manifestations such as ueteroureteral reflux or ureteropelvic junction obstruction which can lead to hydronephrosis or recurrent Urinary tract infection. Co-existing anomalies may be encountered during interven-tional procedures. Hence knowledge of urinary system and Identification of the various anomalies are important prior to surgery which will contribute in understanding the various associated complications and will provide additional help in various surgical interventions.

Conflicts of Interests: None

REFERENCES

[1]. Sadler TW. Langman's Medical Embryology. 11th ed. Philadelphia: Wolters Kluwer Lippincott Williams & Wilkins;2010.

[2]. Standring S. Gray's Anatomy: The Anatomical Basis of Clinical Practice. 40th ed. Edinburgh: Churchill Livingstone/Elsevier;2008

[3]. Dinanath P, Ashwini A, Annarao G, Nagaraj S. Bilateral Complex Duplex Renal Pelves and Ureters- A Case Report. International Journal of Anatomical Variations. 2011;4:192-194.

[4]. Lee s, Kim W, Kang KP, Jeong YB, Kim YK, Jang YB, Park SK. Bilateral Incomplete Double Ureters. Nephrol Dial Transplant.. 2007;22:2720-2721.

[5]. Karakose A, Aydogdu O, Atesci YZ. Ulilateral Complete Ureteral Duplication with Distal Ureteral Stone: A Rare Entity. Can Urol Assoc J. 2013;7(7-8):e511-2.

[6]. Halim HA, Al-Awadi KA, Kahinde EO, Mahmoud AH. Blind Ending Ureteral Duplication With Calculi. Ann Saudi Med. 2005;25(4):346-348.

[7]. Prakash, Rajini T, Venkatiah J, Bharadwaj AK, Singh DK, Singh G. Double Ureter And Duplex System- A Cadaver And Radiological Study. Urol J.2011;8:145-148.

[8]. Saito S. Evaluation of Cases Where ThE Right Kidney Is Higher Than The Left Kidney. International Journal of Urology.2003;10:359-363.

[9]. Mishra A, Sharma PK, Manik P, Mishra PP. Bilateral Multiple Renal Arteries: A Case Report. OA Anatomy. 2014;2(3):22.

[10]. Gupta A, Gupta R, Singha RK. The Accessory Renal Arteries: A Comparative Study In Vertebrates With Its Clinical Implications. Journal of Clinical & Diagnostic Research. 2011;5(5):970-973.

[11]. Das S, Dhar P, Mehra RD. Unilateral Isolated Bifid Ureter- A Case Report. J Anat Soc India. 2001;50(1):43-44.

[12]. Bozkurt B, Tokac M, Dumlu EG, Yarar O, Kilc M. Modified Extravesical Ureteroneocystostomy In Cadaveric Kidney Transplantation With Duplicated Ureters: A Case Repot. J Transplant Technol Res. 2014;4:2.

How to cite this article: Chiman Kumari, Rohini Motwani, Saroj Kaler Jhajhria, Neerja Rani, Pooja Jain, Khursheed Raza, Vidhu Dhawan, Seema Singh. HIGHER RIGHT KIDNEY AND PARTIAL DUPLICATION OF LEFT URETER: A CASE REPORT. Int J Anat Res 2017;5(2.2):3788-3790. **DOI:** 10.16965/ijar.2017.178