

THE ANATOMICAL STUDY OF POPLITEAL ARTERY AND ITS VARIATIONS

Soumya Philipose ¹, J. Sujitha Jacinth ^{*2}, V. Muniappan ³.

¹ Assistant professor, Department of Anatomy, Amala Institute of Medical Sciences, Trichur, India.

^{*2} Assistant professor, Department of Anatomy, RMMCH, Annamalai University, Chidambaram, India.

² Professor and Head, Department of Anatomy, RMMCH, Annamalai University, Chidambaram, India.

ABSTRACT

Introduction & aim: Anatomical variations in the arterial system are very common. In spite of advanced invasive techniques, knowledge of variations still remains limited. One such artery showing variations is the popliteal artery. Limb-threatening sequelae ensue from its damage. The aim of the study encompasses gaining knowledge on the anatomy of Popliteal artery with respect to its commencement, termination, branching pattern & its relation with surrounding structures mainly the muscles in the Popliteal fossa with a view of helping surgeons from various fields while performing surgery in this region. Comparison with results from previous studies on the popliteal artery was also planned.

Materials and Methods: The study was carried out in 50 lower limbs of 25 well embalmed cadavers of South Indian origin irrespective of age and sex. None of the limbs showed any evidence of previous knee surgery.

Results: Popliteal artery was the continuation of femoral artery. The level of termination in relation to the Popliteus muscle was high in one case and in the middle in another case. Popliteal artery terminated into anterior tibial and posterior tibial arteries. Arterial trifurcation was unobserved. Course was found to be normal with the Popliteal vein and Tibial nerve lying lateral to the artery in the upper part of popliteal fossa and medial to it in the lower part by crossing superficial to it. Third head of Gastrocnemius or aberrant band was not found.

Conclusion: This study provides information vital to the successful accomplishment of surgical, radiological or interventional procedures to be carried out in the vicinity of the vessel.

KEYWORDS: Popliteal artery, anterior tibial artery, posterior tibial artery, popliteus muscle, third head of gastrocnemius.

Address for Correspondence: Dr. J. Sujitha Jacinth, Assistant professor, Department of Anatomy, RMMCH, Annamalai University, Chidambaram, India. **E-Mail:** sujitha_jaf@rediffmail.com

Access this Article online

Quick Response code



DOI: 10.16965/ijar.2017.435

Web site: International Journal of Anatomy and Research
ISSN 2321-4287
www.ijmhr.org/ijar.htm

Received: 30 Aug 2017

Peer Review: 30 Aug 2017

Revised: 04 Sep 2017

Accepted: 20 Oct 2017

Published (O): 01 Dec 2017

Published (P): 01 Dec 2017

INTRODUCTION

Popliteal artery is the continuation of Femoral artery after passing through the fifth osseo-aponeurotic opening of the Adductor magnus. It descends laterally to the intercondylar fossa and bifurcates at the lower border of Popliteus muscle into Anterior and Posterior tibial arteries. It may divide into terminal branches

proximal to the popliteus muscle. Anterior tibial artery then may descend anterior or posterior to the muscle. The termination was considered "high" if it divides at the upper border of the popliteus and as "low" if it divides below from the lower border of popliteus muscle. And also the Peroneal artery may branch high from the Posterior tibial artery or may even branch from

Popliteal artery separately, giving a trifurcation. In the upper part of the popliteal fossa, Popliteal vein and Tibial nerve are posterolateral to the artery, then crosses the artery and becomes superficial to it. In the lower part both are medial to the artery. The vein is adherent to the artery throughout its course [1].

The site of passage of this artery through the adductor hiatus is a common area for atherosclerotic stenosis and occlusion probably as a result of repeated injury to the vessel in the hiatus. The anatomical relationships between Popliteal artery and surrounding structures are important. Arterial entrapment by neighboring muscles and tendons may occur due to variations that occur during the developmental stages. The Popliteal artery is relatively tethered to the Adductor magnus and distally by the fascia related to Soleus and is therefore vulnerable to traction during knee surgeries for example, dislocation. It passes medially beneath the medial head of Gastrocnemius muscle; contraction of which may occlude the artery and lead to vascular insufficiency. Extrinsic vascular compression causes chronic vascular microtrauma, early arteriosclerosis and thrombus formation [2]. The entrapment of the Popliteal artery above the bifurcation level due to an anatomical anomaly is called "Popliteal Artery Entrapment Syndrome" [3]. Stuart PTA [4] first published the clinical and radiological report about this syndrome as early as 1879.

The arterial variations may be due to any embryological defects, racial variance, or even acquired in nature. Szpinda N et al [5] described that the variations of popliteal artery are related to the combination of Sciatic and Primary femoral arteries which grow into the primodium of the lower limb. Awareness of these variations is important to perform surgical procedures like femoral distal end or proximal tibial or fibular fracture surgery, total knee arthroplasty, and especially in surgical interventions performed for Popliteal artery aneurysms or percutaneous vascular reconstruction in the lower extremities. Involvement of variant arteries during surgeries can lead to arterial complications like transection, fistula formation, pseudoaneurysms and thrombosis which may lead to limb or life threatening outcomes.

The purpose of this study is to describe anatomical variations of the Popliteal artery enabling it as a guide line for orthopaedicians, vascular surgeons and radiologists to some extent.

MATERIALS AND METHODS

The study of Popliteal artery was carried out in 50 lower limbs of 25 well embalmed cadavers, in the Department of Anatomy, Amala Institute of Medical Sciences, Trichur and Department of Anatomy, Rajah Muthiah Medical College, Annamalai university, Chidambaram. The study was conducted irrespective of age and sex. Lower limbs with previous knee surgery were excluded.

The gross dissection was done by following the guidelines of Cunningham's manual of practical anatomy (vol-1) [6]. After the skin was incised the popliteal fossa was exposed through the posterior approach by identifying the muscles forming the boundaries of the fossa. The Tibial nerve, Common peroneal nerve, Popliteal vein were identified and then Popliteal artery was traced up to its terminal branches on both sides. The study was carried out under the following parameters, A. Origin, B. Level and mode of termination, C. Variation in the branches, D. Relation with Tibial nerve and Popliteal vein.

RESULTS

Origin of the Popliteal artery: The Popliteal artery was the continuation of femoral artery from the fifth osseoponeurotic opening of adductor magnus in all the 50 specimens studied.

Level of termination of the Popliteal artery: The level of termination of Popliteal artery in relation to Popliteus muscle was observed in all the specimens as shown in table1. The level of termination was found to be normal in 48 specimens (96%) where it terminated at the lower border of the Popliteus muscle as shown in fig.1. It was high in 1 specimen (2%); where the termination was at the upper border of Popliteus as shown in fig.2. It was mid termination in 1 specimen (2%); at the middle of Popliteus muscle as shown in fig.3.

Mode of termination of Popliteal artery: In all the 50 specimens studied the Popliteal

artery terminated into Anterior tibial and Posterior tibial arteries. Trifurcation of the artery was not observed.

Course of Popliteal artery: In all the 50 specimens studied, Popliteal artery entered the popliteal fossa through the fifth osseo-aponeurotic opening in the Adductor magnus. In 48 specimens, the artery had termination at the lower border of Popliteus muscle. The artery passed downward and laterally in close contact with the floor of popliteal fossa lying between two heads of Gastrocnemius and superficial to Popliteus muscle. Then it descended laterally inclining obliquely to distal border of Popliteus muscle, where it divided into Anterior tibial and Posterior tibial arteries.

Relation of Popliteal artery to Popliteal vein and Tibial nerve:

In all the specimens studied, Popliteal vein and Tibial nerve were lateral to the artery in the upper part of the popliteal fossa, then crossed the artery and was superficial to it. In the lower part, vein and nerve were medial to the artery. The vein was adherent to the artery throughout its course.

Relation of Popliteal artery to medial head of Gastrocnemius:

Popliteal artery was lateral to the medial head of Gastrocnemius in all the specimens studied. No evidence of third head of Gastrocnemius or aberrant band was noticed.

Relation of the terminal branches to Popliteus muscle in high termination of Popliteal artery:

In one specimen of high termination, Anterior tibial artery and Posterior tibial artery coursed distally anterior to Popliteus muscle.

Fig.1: Normal termination at the lower border of popliteus

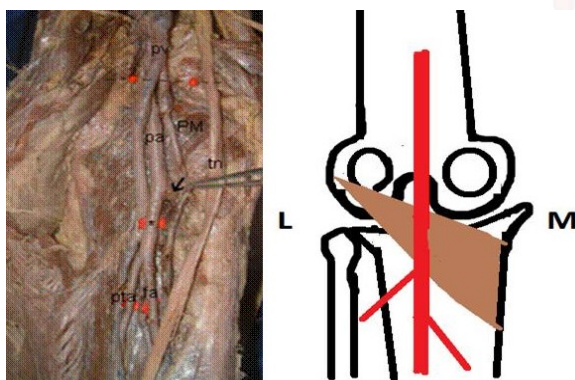


Fig.2: High termination of Popliteal Artery above the upper border of Popliteus muscle.

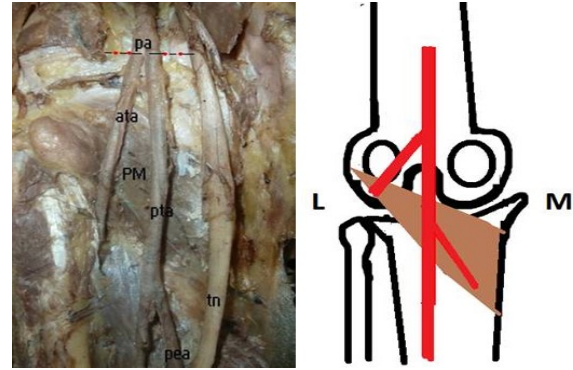
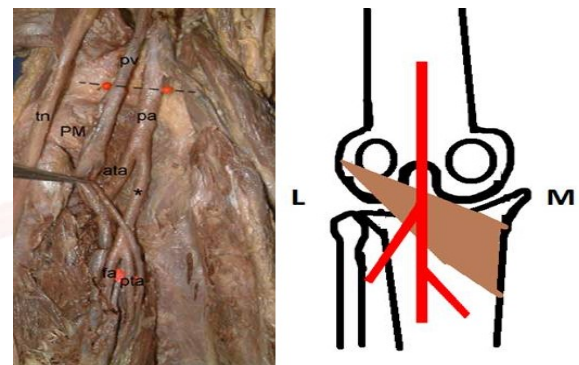


Fig.3: Mid termination of Popliteal artery.



PM - Popliteus muscle, Pa - Popliteal artery, Pv - Popliteal vein, Ata- Anterior tibial artery, Pta- Posterior tibial artery, Pea- Peroneal artery, Tn- Tibial nerve

Table 1: Level of termination of Popliteal artery (n=50).

Level of termination	No. of specimens	Percentage
Normal	48	96
High	1	2
Mid	1	2
Low	0	0
Total	50	100

DISCUSSION

Embryologically, development of Popliteal artery is complicated. Variations of this artery depend on its development. During development the embryonic vessels may persist or degenerate. Sometimes abnormal fusion may take place. The vessels of lower extremity arise from two sources; the primary limb bud artery otherwise axial or sciatic artery and femoral artery. The axial artery arises from the dorsal root of the umbilical artery and courses along the dorsal surface of the thigh, knee and leg. Below the knee it lies between the tibia and Popliteus, and in the leg it lies between the crural interosseous membrane and Tibialis posterior. It gives off a perforating artery that traverses the tarsal tunnel to form a dorsal network and ends distally

in a plantar network. The Femoral artery passes along the ventral surface of the thigh, opening a new channel to the lower limb. It arises from a capillary plexus that is connected proximally with the femoral branches of the external iliac artery and distally with the axis artery. At the proximal border of Popliteus, a new vessel sprouts from the axis artery before it splits into primitive posterior tibial and peroneal branches: these run distally on the dorsal surface of Popliteus and Tibialis posterior to gain the sole of the foot. At the distal border of Popliteus, the axis artery gives off a perforating branch that passes ventrally between the tibia and the fibula and then courses to the dorsum of the foot, forming the Anterior tibial artery and Dorsalis pedis artery.

The primitive peroneal artery communicates with the axis artery at the distal border of Popliteus and in its course in the leg. The Femoral artery gradually increases in size. Coincidentally, most of the axis artery disappears; however, proximal to its communication with the Femoral artery, the root of the axis artery persists as the Inferior gluteal artery and the Arteria comitans nervi ischiadici. The proximal parts of the primitive posterior tibial and peroneal arteries fuse: they remain separate distally. Ultimately, much of the primitive peroneal artery disappears; however, a part of the axis artery is incorporated in the permanent Peroneal artery [7].

The vascular system is known to show a wide range of anatomical variations. Variations in the branching pattern of Popliteal artery are common. The importance of this variation has been evaluated by different techniques such as dissection and angiography [8]. Due to continued increase in the cases of vascular surgery or interventional procedure in the Popliteal artery and tibial branches, the anatomical variations in this region may have an influence on the success of surgical arterial reconstruction, transluminal angioplasty, or embolectomy, and the diagnosis of arterial injury. Also failure to recognize the variation in the Popliteal artery results in unsatisfactory arterial anastomosis in patients who requires femorodistal bypass graft procedures. Therefore knowledge of the variation is important in planning and conducting various surgical or radiological procedures

pertaining to this region.

In our study, we found high termination of Popliteal artery in 2% of specimens and mid termination of the artery in another 2% of specimens. This was similar to Adachi B [9], Bergman RA et al [10]. Also in 96% of individuals, termination of Popliteal artery below the lower border of popliteus (below the tibial plateau) was observed, similar to the classification of type 1 of Lippert H et al [11] and Kim et al [12] study. High origin of Anterior tibial artery was found in our study in high termination of Popliteal artery, which was also found in Zuhail Ozgur et al [13], Trotter M et al [14], Kil SW et al [15], Yildiz et al [16] and Tindall et al [17] study. Trifurcation of Popliteal artery was not observed unlike those reported by Zuhail Ozgur et al [13], Colborn et al [18] and Day and Orme [19]. Popliteal entrapment syndrome, which may be attributed to anomaly of medial head of Gastrocnemius was not observed though various authors like Z.A. Aktan et al [19], Haidar et al [20], Gibson et al [21], DiMazro et al [22] and Elias D et al [23] have published it.

According to Adachi B [9] the term "high division of the popliteal artery" is used when the first branch arose at or above the articular surface of the tibial plateau. Clinicians and radiologists prefer to use the medial tibial plateau as a reference point because it is a remarkable point in angiography. Therefore they define the division of the Popliteal artery superior to the upper border of the medial tibial plateau as high division. This study also grouped the variations of the Popliteal artery's terminal branching and its relation to the Popliteus muscle in three types. In type 1, the Popliteal artery descended at the posterior surface of the Popliteus muscle. At the medial portion of the artery the posterior peroneotibial trunk was formed, which later branched into the Fibular artery and Posterior tibial artery, and at the lateral portion of the artery, Anterior tibial artery was formed. In type 2, the Popliteal artery descended at the posterior surface of the Popliteus muscle. It was divided medially into the Posterior tibial artery and laterally into the anterior peroneotibial trunk. The anterior peroneotibial trunk bifurcated into the Fibular artery and Anterior tibial artery at the distal

border of the Popliteus muscle. According to type 3, the Popliteal artery, bifurcated at the proximal border of the Popliteus muscle into the anterior branch which descended at the ventral surface of the Popliteus muscle and continued as Anterior tibial artery between the muscle and posterior surface of tibia, the posterior branch continued as the posterior peroneotibial trunk at the dorsal surface of the Popliteus muscle. Bergman RA et al [10] reported that high division with the anterior peroneal trunk is more frequently seen in the right extremity, while high division of the Popliteal artery with the usual pattern frequented the left side. It is also mentioned that if variation occurs on one side, one is likely to observe presence of variation on the other side also.

Lippert H et al [11] classified the branching patterns of Popliteal artery according to the level and sequence of branching of the Anterior tibial, Posterior tibial and Peroneal arteries. According to this classification, the division of the Popliteal artery (below the tibial plateau) was considered as normal level (Type 1). In Type 2, branching pattern of the Popliteal artery occurs when one of the branches arise above the tibial plateau.

Kim et al [12] angiographically classified the branching patterns of the Popliteal artery in 472 limbs. Angiographically the borders of Popliteus cannot be determined accurately, hence, the tibial plateau was used as the reference point. According to this classification, the division of the Popliteal artery was at the normal level (below the tibial plateau) in type 1 branching pattern of the Popliteal artery. In Type 2, branching pattern of the Popliteal artery was of one of the branches that arose above the tibial plateau. Type 3 branching pattern involved hypoplasia or aplasia of one or more of the infra Popliteal vessels with altered arterial supply to the foot. In a study conducted by Zuhail Ozgur et al [13], Anterior tibial artery was found to have high origin in 1.2% and was lying posterior to the Popliteus muscle. Arterial trifurcation was also observed in 3.2% of their study.

Trotter M [14] reported a ventral course of Anterior tibial artery in 42% of high-origin cases. Kil SW et al [15] noted that the course of Anterior tibial artery could be either from the ventral

or from dorsal surface of the Popliteus muscle. The risk of vascular trauma during orthopedic procedures may be increased when there is an abnormal branching of the Popliteal artery with an aberrant anterior tibial artery originating above the Popliteus muscle and coursing between the posterior tibial surface and ventral surface of the Popliteus muscle. Distal popliteal arterial variations may influence the success of femorodistal popliteal and tibial arterial reconstructions. Preoperative identification of this anatomical variant may help to avoid these complications.

Yildiz et al [16] commented that high-origin of Anterior tibial artery from the Popliteal artery was about 1.2% to 6%. These high origins are vulnerable to arterial complications, including transection, fistula formation, pseudoaneurysm, thrombosis during orthopedic procedures such as high tibial osteotomy, revision total knee arthroplasty, lateral meniscal repair, posterior cruciate ligament interventional procedure in the Popliteal artery and its tibial branches.

Tindall et al [17] observed that in all patients with high origin of the Anterior tibial artery, the artery was in direct contact with the posterior aspect of the tibia, in this variation using sharp instruments during knee procedures may be vulnerable.

Colborn et al [18] reported the splitting of the Popliteal artery into three branches in about 3% and also agenesis of the Popliteal artery. In this case, the Anterior tibial and Peroneal arteries originated distally from multiple collateral channels around the knee.

Day and Orme [19] observed 3.2% of cases of trifurcation of the Popliteal artery in their angiographic study and also hypoplastic and aplastic infra Popliteal vessels.

Z.A. Aktan et al [20] reported that the presence of an aberrant accessory head of Gastrocnemius was higher in Turkish than Japanese people. In Japanese people, the frequency rate of the third head of Gastrocnemius muscle was 5.5%. This has been reported to be high in comparison with other nationalities (2.9–3.4%) but the presence of an aberrant accessory head of Gastrocnemius was observed higher than Japanese people in Turkish people with 6.5%. In this study, the Popliteal artery was lateral to

Popliteal vein in four specimens (8.7%) and it was deep to Popliteal vein in three specimens in the popliteal fossa (6.5%).

Haidar.S et al [21] reported that most common cause of Popliteal artery entrapment syndrome is related to medial head anomaly of Gastrocnemius.

Gibson et al [22] reported an incidence of 3.8% in 86 postmortem limbs. The Plantaris tendon sometimes may be the reason for Popliteal artery entrapment syndrome.

Di Marzo L et al [23] found the Popliteal artery was coursing around the medial head of Gastrocnemius muscle which was compressing it and had the aneurysmal changes distal to the external muscular compression.

Elias D et al [24] stated that Popliteal artery entrapment syndrome refers to compression of the Popliteal artery caused by the anatomical abnormalities in the popliteal fossa. Popliteal artery might be trapped by neighbouring muscles and tendons due to variations that occur during embryologic development of muscles and arteries.

Dar AM et al [25] noticed that Popliteal artery was tethered at the Adductor magnus hiatus and distally by the fascia related to Soleus. It is therefore vulnerable to traction during knee injuries, e.g. dislocation.

The knowledge of branching pattern of the Popliteal artery is Important for surgical interventions in the Popliteal region in order to minimize undesired hemorrhage and surgical complications due to anatomical variations. Orthopaedicians doing knee joint surgery and total knee arthroplasty, surgeons correcting Popliteal artery aneurysms and radiologists performing angiographic studies should be aware of these anatomical variations. These variations are compared with the earlier data and it is concluded that variations in branching pattern of the Popliteal artery are frequent rather than exceptions.

CONCLUSION

Clinically, Popliteal artery entrapment syndrome should be kept in mind when the patient has intermittent leg pain, coldness or pallor in the lower limb. Early detection of the condition is

absolutely essential. Computed Tomography, Angiography and Magnetic Resonance Image gives the detailed anatomy of the popliteal region well enough to reveal the cause of arterial entrapment. Early planning of Magnetic Resonance angiography, helps prevent delay in diagnosis. If the patient has Popliteal artery entrapment syndrome, the most common aetiology is anomaly of medial head of gastrocnemius. The contralateral popliteal artery should also be examined as there is a 28% probability of variation to occur on the opposite side.

Despite improvements in vascular surgical techniques, Popliteal vascular injuries and Popliteal artery aneurysms continue to be potentially dangerous lesions with high percentage of leg amputations. The material reported here includes a review of the basic anatomic relationship of the Popliteal artery with its surrounding structures and its variation in the branching pattern. Awareness of these variations is crucial for evaluation of the lower extremity arteriograms and has clinical implications for vascular surgeons and interventional radiologists. Thus the present study is an attempt to add to the existing knowledge of the Popliteal artery and its variations in the branching pattern.

Conflicts of Interests: None

REFERENCES

- [1]. Standring S, Gray's anatomy. The anatomical basis of clinical practice: 40th ed. Elsevier. Churchill Livingstone; 2008. p. 1408, 1409.
- [2]. Lee McGregor's, Synopsis of surgical anatomy: 12th ed. 1986: 244-245.
- [3]. Atilla S, Ilgit ET, Akpek S, Yucel C, Tali ET, Isik S. MR imaging and MR angiography in popliteal artery entrapment syndrome. Eur Radiol. 1998 8 (6): 1025 – 1029.
- [4]. Stuart PTA. Note on a variation in the course of popliteal artery. J Anat Physiol. 1879 13: 162 .
- [5]. Szpinda M. Digital – image analysis of the angiographic patterns of the popliteal artery in patients with aorto – iliac occlusive disease (Leriche syndrome). Ann Anat. 2006; 188(4): 377- 382.
- [6]. Romanes G J. Cunningham's manual of practical anatomy. In: popliteal fossa Vol. 1. 15th ed. Oxford, Oxford Medical Publications; p. 160-162
- [7]. A.K. Datta, Essentials of Human Embryology, 5th ed. 2005; 196
- [8]. Kurtoglu Z and Uluutku MH. A Combined Variation of the Arteries and Nerve in a Leg. Turk J. Med. Sci., (1999) 29(6): 723-727.

- [9]. Adachi B. Das Arterien system der japaner, band 2. Kyoto, Kenkyusha:1928;198 – 201.
- [10]. Bergman RA, Thompson SA, Afifi AK, Afifi AK, Saadeh FA. Popliteal vein.eds. Compendium of Human Anatomic Variations, Text, Atlas and World Literature. 2nd ed. Baltimore, Munich: Urban and Schwarzenberg; 1988:93.
- [11]. Lippert H, Pabst R. Arterial variations in man: Classification and Frequency. Munchen: J.F Bergman Verlag;1985 ;82.
- [12]. Kim HK, Shin MJ, Kim SM, Lee SH ,Hong HJ, Popliteal artery entrapment syndrome : morphological classification utilizing MR imaging .Skeletal Radiol. 2006 ; 35(9): 648 – 658.
- [13]. Zuhail Ozgur, Hulya Ucerler, Z Asli Aktanlkiz. Branching patterns of the Popliteal artery and its clinical importance. Surg Radiol Anat 2009;31:357-362.
- [14]. Trotter M. The level of termination of popliteal artery in the White and the Negro. Am J Phys Anthropol. 1940; 27: 109- 118.
- [15]. Kil SW, Jung GS. Anatomical variations of the popliteal artery and its tibial branches: analysis in 1242 extremities . Cardiovasc intervent Radiol.2009;32(2);233-240.
- [16]. Yildiz S.A. High–origin anterior tibial artery and its current clinical importance.International journal of anatomical variations 2010; 3:180-182.
- [17]. Tindall AJ,Shetty AA,James KD, Middleton A, Fernando KW. Prevalance and surgical significance of a high origin anterior tibial artery. J Orthop Surg(Honh Kong). 2006;14:13-16.
- [18]. Colborn G L, Lumsden A B, Taylor B S, Skandalakis J E . The surgical anatomy of popliteal artery,The American Surgeon.1994; 60:238 – 246.
- [19]. Day CP, Orme R. Popliteal artery branching patterns – An Angiographic study. Clin Radiol. 2006;61(8):696 – 699.
- [20]. Aktan Ikiz ZA, Ucerler H, Ozgur Z.Anatomic variations of popliteal artery that may be a reason for entrapment. Surg Radiol Anat.2009;31(9):695-700.
- [21]. Haidar S , Thomas K, Miller S. Popliteal artery entrapment syndrome in a young girl. Pediatric Radiol .2005;35(4):440 – 443.
- [22].Gibson MHL, Mills JG, Johnson GE, Downs AR.Popliteal entrapment syndrome. Ann Surg 1977;185:341 – 348.
- [23]. Di Marzo L, Cavallaro A . Popliteal vascular entrapment.World J Surg. 2005: 29:S43-S45.
- [24]. Elias D .A, White L.M, Rubenstein J.D, et al. Clinical evaluation and MR imaging features of popliteal artery entrapment and cystic adventitial disease.AJR.2003;180(3):627–632.
- [25]. Dar AM, Ahanger AG, Wani RA, Bhat MA, Lone GN, Shah SH . Popliteal artery injuries: the Kashmir experience. J Trauma 2003;55(2):362- 365.

How to cite this article:

Soumya Philippose, J. Sujitha Jacinth, V. Muniappan. THE ANATOMICAL STUDY OF POPLITEAL ARTERY AND ITS VARIATIONS. Int J Anat Res 2017;5(4.3):4679-4685. DOI: 10.16965/ijar.2017.435