

A STUDY OF NEURONAL PROFILE OF INFERIOR OLIVARY NUCLEAR COMPLEX IN FOETAL AND ADULT HUMAN MEDULLA

B.Narasinga Rao^{1*}, M. Pramila Padmini².

Professor & HOD¹, Assistant Professor².

Department of anatomy, Maharajah's Institute of Medical Sciences, Nellimarla, Andhra Pradesh, India.

ABSTRACT

Introduction: ION receives proprioceptive impulses from spino-olivary tract and conveys the fibers to the cerebellum through olivo-cerebellar tract. There is paucity of data in human olivary complex, hence the present study is done. **Materials and Methods:** Study was conducted with 15 adult brains and 25 fetuses of different gestations were perfused with 10% formalin and processed for histological examination. **Observations:** Rounded cells have been seen infiltrating the entire field. at 16 weeks of gestation. Segregation of neurons into principal, medial, and dorsal accessory olivary nuclei at 20 wks gestation. **Discussion:** Neuron differentiation into oval, round, multipolar types has begun at 40 wks gestation. Neurons in the olivary subdivisions are grouped in separate clusters as per Ramon y Cajal, 1909; Scheibel and Scheibel, 1955, Bowman and King, 1973. Multipolar neurons dominated in adult inferior olivary nucleus. **Conclusion:** The greater development of neurons is a consequence of finer regulation of various movements of hands and finger associated with movement of head and eyes.

KEY WORDS: CEREBELLUM; INFERIOR OLIVARY NUCLEUS; MEDULLA; NEURON.

Address for Correspondence: B.Narasinga Rao, Professor & HOD, Department of Anatomy, Maharajah's Institute of Medical Sciences, Nellimarla, Vizianagaram, Andhra Pradesh, India.

Ph. No.: +919441851199. **E-Mail:** rao.bhattam@gmail.com.

Access this Article online

Quick Response code



Web site: International Journal of Anatomy and Research
ISSN 2321-4287
www.ijmhr.org/ijar.htm

Received: 10 July 2013

Peer Review: 10 July 2013 Published (O):22 July 2013

Accepted: 17 July 2013 Published (P):30 Sep 2013

INTRODUCTION

Inferior olivary nucleus (ION) is closely associated with the cerebellum, meaning that it is involved in control and coordination of movements [1], sensory processing and cognitive tasks likely by encoding the timing of sensory input independently of attention or awareness [2,3,4]. Lesions to the ION have been associated with a decreased ability to perform highly specialized motor tasks, such as improving one's accuracy in hitting a target with a ball [5].

Olivary nuclear complex is associated with spino cerebellar part and hence phylogeny of inferior olivary nuclear complex is closely associated with evolution of cerebellum [6].

This nuclear complex has a point to point relationship with cerebellar cortex [7]. The development of this complex is associated with the evolution of cerebellum. Medial and dorsal accessory olivary nuclei have been described in all the phyla starting with fish. Medial olivary nucleus is well developed in all those animals that are good swimmers due to great development of trunk and tail musculature. Although many studies have established the connections of the inferior olivary complex, there have been relatively few studies on the morphology of this nuclear complex. Hence the present study is attempted.

MATERIALS AND METHODS

15 adult brains and 25 fetal brains of different gestations were perfused with 10% formalin at the department of anatomy, MIMS Medical College, Vizianagaram. After removal of brains, brain stem was separated. Olive was identified lateral to pyramids of medulla. Rapid dehydration technique of mason was adopted. Tissues were embedded in paraffin. 5 micron thickness paraffin sections were cut and after clearing and dehydration sections were stained with H&E stain. Most of the fetuses collected were of 16, 24 week and full term fetuses. Fetuses of earlier weeks could not be collected, hence the study was limited to 16, 20 and 40 weeks fetuses and adults of unknown age group. The data collected was subjected to study.

OBSERVATIONS

Ion in human fetuses at 16 wks gestation:

Inferior olivary and accessory nuclei are not discernable to the eye since no subdivision is apparent at 16 weeks of gestation. Rounded cells have been seen infiltrating the entire field. The cells are arranged in linear clusters. No dendrites are seen.(fig.1). In this field at 16 weeks gestation in addition to linear clusters of rounded neurons, round clusters are also seen (fig.2). Localization of rounded and linear clusters of neurons are distinct(fig.3). Fiber tracts have been seen.

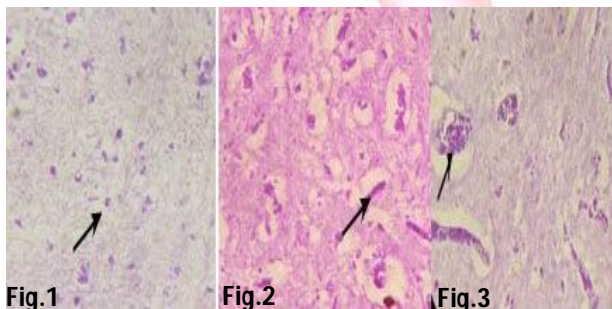


Fig.1 showing rounded neurons at 16 wks gest. 10x10, H&E.

Fig.2 showing linear clusters of rounded neurons at 16 wks gest. 10x40, H&E.

Fig.3 showing localization of neurons at 16 wks gest. 10x40, H&E.

Ion In Foetal Brain 20 weeks gestation:

Inferior olivary complex showed segregation of rounded neurons into principal, medial, and dorsal accessory olivary nuclei. (fig.4).Neurons retained rounded shape. No dendrites are seen.

Fiber tracts are well laid down in the designated principle olivary nucleus. Segregation of three components of inferior olivary complex with migrating neurons from the hilum of the principle nucleus is observed.

Ion at 40 wks gestation:

Dendrites also are observed and there is varicosity of the dendrites in older cells. An increase in the diameter of the cell is also observed. However rounded neurons having less dense population are also seen. Neuron differentiation into oval, round, multi-hedric types has begun(fig.5).

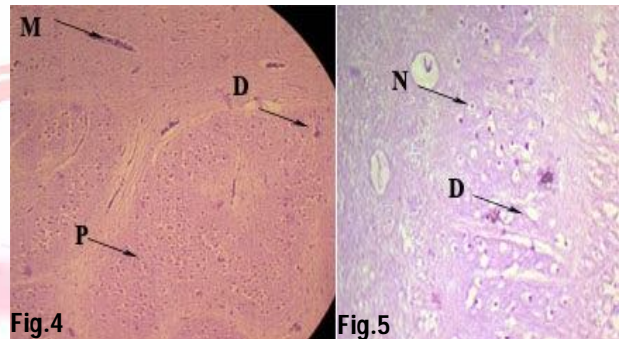


Fig.4

Fig.5

Fig.4 showing differentiation of principal, medial and dorsal olivary nucleus at 20 wks gest. 10x10, H&E.

Fig.5 showing neurons and dendrites at 40 wks gest. 10x40, H&E.

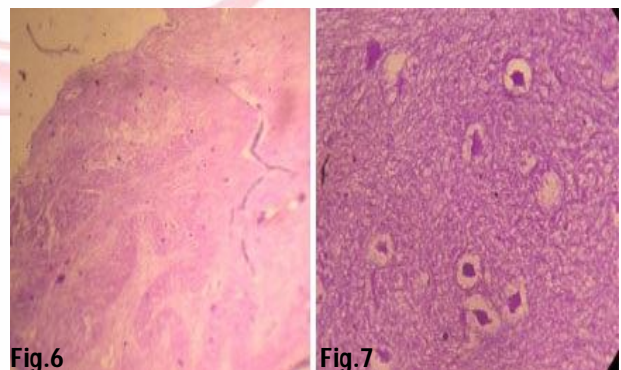


Fig.6

Fig.7

Fig.6 showing ION as crenated bag in adults. 10x10, H&E.

Fig.7 showing domination of multiolar neurons in adult ION 10x40, H&E.

Ion in adult brain:

A hollow irregularly folded crenated mass of grey matter is seen(fig.6). It is "u" shaped with open part of the "u" directed medially forming the hilum. The nucleus has dorsal and ventral limbs. The dorsal and medial accessory olivary nuclei are also seen. Multi polar neurons of round, oval, multipolar outlines are observed. Dendritic branching is also seen.

In any given field, the multipolar neurons were dominated. Dendrites have emerged out circumferentially and ramified circling round neuronal soma. This pattern is seen in the principle medial and dorsal olivary nuclei. In this type of neuron the dendrite ramification is less and the dendrite have radiated away from the cell body. About 3 to 4 dendrites were seen (fig.7).

DISCUSSION

The light microscopic study of inferior olivary complex (ION) of opossum reported that ion was not discernable on 13th post conception day [8]. Homogenous mass appeared on the 3rd post natal day. Further growth, subdivision and attaining 3/4th of the adult size was observed by 68th post natal day. Similar observations were also made in ground squirrels[9]. Neurons in the olivary subdivisions seem to be grouped in separate clusters, with their dendritic fields usually being restricted to a particular subdivision [10,11,12].

A study of nucleus olivaris inferior of the European bison found 90% of neurons present are multipolar cells and 10% of neurons present are pear-shaped and rounded cells [13].

CONCLUSION

In the present study at 16 weeks of gestation the full complement of inferior olivary complex is not discernable in the caudal part of medulla oblongata. However the caudal part is infiltrated with rounded neurons which are migratory. Later there is rearrangement of cells into linear and rounded clusters without any dendrites. By 20th week the subdivision of ion complex has appeared with a clear demarcation of fiber tracts interspersing in between. In full term foetuses the cells of ion complex have been differentiated into different types as seen in adults.

In adult brains the principle nucleus is seen as crenated, folded and "u" shaped mass with the dorsal and medial accessory olivary nuclei having rounded, oval, and multi-hedric (multi-polar cells) with a preponderance of multi-hedric neurons in all the components of inferior olivary nucleus.

Inferior Olivary Nucleus receives proprioceptive impulses from spino-olivary tract and conveys the fibers to the cerebellum through olivo-cerebellar tract.

The greater development of neurons is a consequence of finer regulation of various movements of hands and fingers associated with movement of head and eyes, a complexity called "occulo cephalo gyric movement". This is not having any connection with flocculus since flocculus is concerned with vestibular functions of lateral line organs and ion is concerned with spino-cerebellar system.

REFERENCES

1. Medical neurosciences <http://www.neuroanatomy.wisc.edu/virtualbrain/BrainStem/06Olive.html>.
2. Xu D, Liu T, Ashe J, Bushara KO. Role of the olivo-cerebellar system in timing. *J Neurosci* 2006; 26: 5990-5.
3. Liu T, Xu D, Ashe J, Bushara K. Specificity of inferior olive response to stimulus timing. *J Neurophysiol* 2008; 100: 1557-61.
4. Wu X, Ashe J, Bushara KO. Role of olivocerebellar system in timing without awareness. *Proc Natl Acad Sci U S A* 2011.
5. Martin TA, Keating JG, Goodkin HP, Bastian AJ, Thach WT. Throwing while looking through prisms. I. Focal olivocerebellar lesions impair adaptation. *Brain* 1996; 119: 1183-1198.
6. Holmes G, Stewart TG (1908) On the connection of the inferior olives with the cerebellum in man. *Brain* 31:125-137.
7. Williams, P.L., Bannister, L.H. Berry, M.M., Collins, P., Dyson, M., Dussek, J.E. and Ferguson, M.W.J. : *Gray's Anatomy*, 38th ed., Churchill Livingstone, Edinburgh, pp. 1027-1065. (1995).
8. Maley BE, King JSEarly development of the inferior olivary complex in pouch young opossums. II. An electron microscopic study. *J Comp Neurol*. 1980 Dec 15;194(4):741-60.

9. Pastirova.A , Wladimir Ovtsharoff. The Inferior Olivary Complex Advances in Anatomy Embryology and Cell Biology Volume 155, 2000, pp 51-66.
10. Ramon y Cajal S (1909-1911) Histologie du Systkme Nerveux de l'Homme et des Vertkbr&. Vols. I and II. Paris: Maloine. Reprinted Madrid: Consejo Superior de Investigaciones Cientificas, 1952.
11. Scheibel ME, Scheibel AB. The inferior olive: a Golgi study. J Comp Neurol, 1955;102:77-132.
12. Bowman MI-I, King JS. The conformation, cytology and synaptology of the opossum inferior olivary nucleus. Comp Neurol. 1955;148:491-524.
13. Szteyn S Types of neurons in nucleus olivaris inferior of the European bison. J Hirnforsch. 1988;29(3):353-6.

How to cite this article:

B.Narasinga Rao, M. Pramila Padmini. A study of neuronal profile of inferior olivary nuclear complex in foetal and adult human medulla. Int J Anat Res, 2013;02:36-39.