

Case Report

Missing common Hepatic Artery and variant Right Hepatic Artery: An incidental finding on CT imaging

Nikhil Aggarwal¹, Garima Sehgal², Kaweri Dande^{*3}, Punita Manik⁴.

¹ Senior Resident, Department of Anatomy, King George's Medical University, Lucknow, Uttar Pradesh, India. ORCID: 0000-0002-4653-7060

² Professor Jr. Grade, Department of Anatomy, King George's Medical University, Lucknow, Uttar Pradesh, India. ORCID: 0000-0002-4987-5487

^{*3} Senior Resident, Department of Anatomy, King George's Medical University, Lucknow, Uttar Pradesh, India. ORCID: 0000-0003-0450-3484

⁴ Professor and Head, Department of Anatomy, King George's Medical University, Lucknow, Uttar Pradesh, India. ORCID: 0000-0001-9942-250X

ABSTRACT

During abdominal surgery, the blood supply to the liver and other abdominal organs plays a vital role. The knowledge regarding hepatic artery variations is crucial for various surgical and radiological procedures concerning the liver and dutiful to be reported. We aim to report a case of variant origin of the right hepatic artery to contribute to the existing knowledge pool to improve surgical safety. The present case describes a variant hepatic vascularization encountered on 3D volume-rendered CT imaging of a 60-year-old male admitted to the hospital emergency for recurrent abdominal pain. The common hepatic artery was absent. The right hepatic artery was observed to arise from the superior mesenteric artery, while the left hepatic artery arose directly from the coeliac artery. Awareness of such abnormalities is critical to minimize morbidity and prevent operational complications in hepatic surgery or liver transplantation.

KEY WORDS: hepatic artery, CT scan, variations, anatomy, superior mesenteric artery, liver.

Corresponding Author: Dr. Kaweri Dande, Senior Resident, Department of Anatomy, King George's Medical University, Lucknow, Uttar Pradesh, India. **E-Mail:** kdande03@gmail.com

Access this Article online	Journal Information
Quick Response code 	International Journal of Anatomy and Research ISSN (E) 2321-4287 ISSN (P) 2321-8967 https://www.ijmhr.org/ijar.htm DOI-Prefix: https://dx.doi.org/10.16965/ijar 
	Article Information
	Received: 13 May 2023 Peer Review: 18 May 2023 Revised: 03 Jun 2023
	Accepted: 01 Jul 2023 Published (O): 05 Sep 2023 Published (P): 05 Sep 2023
DOI: 10.16965/ijar.2023.155	

INTRODUCTION

Variations in the arterial branching patterns of the abdominal aorta have always been a subject of interest for anatomists and radiologists. This awareness is of considerable importance regarding liver transplantations, radiological procedures, abdominal open/laparoscopic surgeries, and operating peri-hepatic areas for any traumatic injuries. Description of the arterial hepatic anatomy begins from the coeliac artery (CA), which

originates from the abdominal aorta and gives rise to the splenic artery, left gastric artery (LGA), and the common hepatic artery (CHA). After giving rise to the gastroduodenal artery, the common hepatic artery (CHA) continues as the proper hepatic artery (PHA), which then separates into the right hepatic artery (RHA) and the left hepatic artery (LHA). They supply the respective hepatic lobes via several intra-hepatic branches [1, 2] (**Figure 1**). Incidence of such "normal" hepatic arterial anatomy ranges

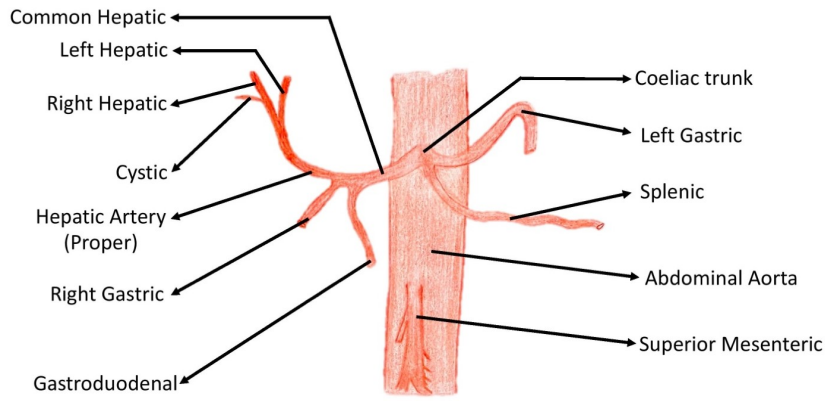


Fig. 1: A hand-drawn sketch depicting the normal branching pattern of hepatic arteries.

between 50-80% [3, 4, 5, 6, 7, 8, 9]. However, several anatomical variants have been identified to date. Needless to say, a computed tomography (CT) scan is of immense diagnostic value for any such vascular anomaly and is also essential for relevant surgical planning.

CASE REPORT

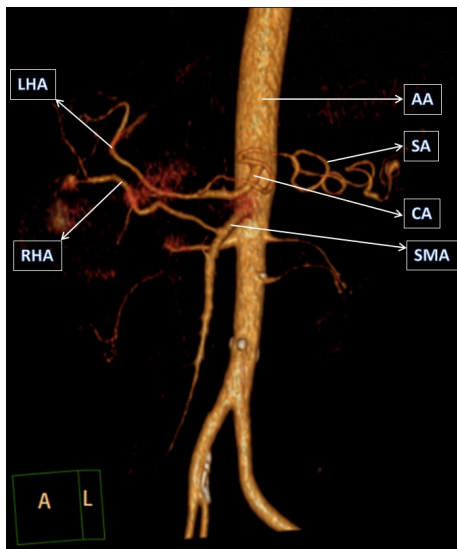


Fig. 2: 3D volume rendered CT image showing abdominal aorta and its anterior visceral branches [AA- abdominal aorta , SA- splenic artery, CA- coeliac artery , SMA- superior mesenteric artery , LHA- left hepatic artery, RHA- right hepatic artery]

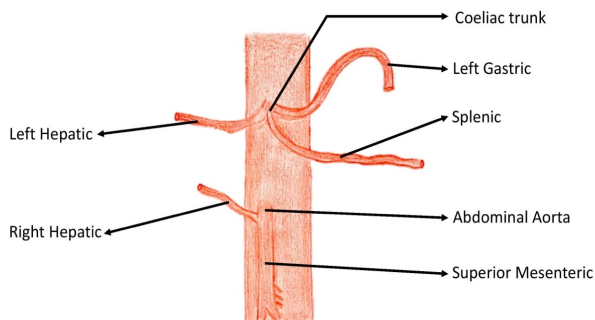


Fig. 3: A hand-drawn sketch depicting the variation in the hepatic arterial system as observed in the present case. The common hepatic artery was absent, and the RHA was observed to arise from the SMA, while the LHA arose directly from the coeliac trunk.

A 61 years old male was taken to the hospital emergency because he was suffering from recurrent abdominal pain. The patient was examined using CT as the radiological modality at the Department of Radiodiagnosis, King George’s Medical University (KGMU), Lucknow. A variation of the hepatic artery was detected on a three-dimensional (3D) volumetric reconstruction (**Figure 2**). It was demonstrated that the RHA arose from SMA, while the LHA arose directly from the coeliac trunk. No common hepatic artery was present (**Figure 3**). RHA was identified and confirmed because it served as the sole arterial supply to the right lobe. No signs of aneurysmal dilation were seen in the aorta. The liver appeared normal. The case was classified as type III according to Michels’s [10] 1966 internationally recognized classification and Hiatt’s [11] 1994 modification of that system (**Table 1**) [12].

Table 1: Anatomical variations of the hepatic arterial system: Michel’s and Hiatt classifications [10, 11].

S. No.	Variation in Hepatic Artery	Michel’s Classification	Hiatt Classification
1	Normal anatomy	Type 1	Type 1
2	Replaced LHA arising from LGA	Type 2	Type 2
3	Replaced RHA arising from SMA	Type 3	Type 3
4	Co-existence of Type 1 & 2	Type 4	Type 4
5	Accessory LHA arising from LGA	Type 5	Type 2
6	Accessory RHA arising from SMA	Type 6	Type 3
7	Accessory LHA arising from LGA & Accessory RHA arising from SMA	Type 7	Type 4
8	Accessory LHA arising from LGA & Replaced RHA arising from SMA	Type 8	Type 4
9	CHA arising from SMA	Type 9	Type 5
10	RHA & LHA arising from LGA	Type 10	NOD
11	CHA directly arising from Aorta	NOD	Type 6

LHA= Left Hepatic Artery, LGA= Left Gastric Artery, RHA= Right Hepatic Artery, SMA= Superior Mesenteric Artery, CHA= Common Hepatic Artery, NOD= Not Otherwise Described

DISCUSSION

The term “replaced hepatic artery” refers to the artery which substitutes the normal in its absence. “Accessory hepatic artery” is used for an artery that is present in addition to the normal one, which nevertheless is equally essential and may possess a specific distribution in each case [13, 2]. During the hepatic lobe resections/transplant surgeries, it is almost impossible to ascertain whether an artery is replaced or accessory; however, it is worth noting that a part of a lobe of the liver may be supplied by the accessory artery or the whole lobe via a replaced artery. This is crucial as any iatrogenic ligation could cause a segment or whole liver lobe necrosis [14, 15]. Choi TW et al. also observed variations of hepatic arteries, with a reported prevalence of 13%–48% [16].

When preparing for hepatobiliary surgery, liver transplant and donor procedures, trans arterial treatment, and other endovascular techniques, knowledge of anatomical changes in the hepatic arteries of patients can be quite useful. Interventional radiologists who perform hepatic arterial embolization or chemoembolization must be familiar with the various anatomic patterns of hepatic arteries to diagnose and treat bleeding foci or malignancies in the liver supplied by abnormal hepatic arteries.

Sukumaran TT et al. examined 35 cadavers; changes in the origin and course of the hepatic artery were found in 3 of the 35 cases, or 8.5%. [17]. The most frequently seen anatomical variation was an accessory or replaced RHA, which arose from the superior mesenteric artery (SMA), with a prevalence of 10-20% [17]. RHA is an essential entity that may get involved in surgical mishaps during any hepatobiliary surgery like pancreaticoduodenectomy or cholecystectomy.

Furthermore, there is substantial evidence that hepatic artery stenosis and thrombosis in liver transplant recipients is more [18]. The RHA variation may be suspected in OT by the presence of a relatively superficial portal vein (PV), indicating the absence of a hepatic artery from its orthodox origin that otherwise

normally ascends in front of PV [2]. Such variations may prove to be life-saving as well. For instance, replaced RHA could be spared from infiltration in bile duct cancer patients as it is further away from the bile duct, making tumor excision more feasible [2]. Hence, it is vital to report and increment the knowledge pool of hepatic arterial variations, leading to better awareness of the surgeons dealing with such hepatobiliary procedures.

CONCLUSION

The knowledge pool of hepatic artery variations has recently broadened with emerging diagnostic and radiological advances. Iatrogenic injuries or surgical mishaps from failure to appreciate the detailed arterial anatomy of the hepatobiliary system may cause serious medico-legal consequences. So, as awareness of these variants is of key importance in preventing fatal intra-as well as postoperative complications, it is righteous and dutiful to report any such variations if found.

ABBREVIATIONS

CT- Computed Tomography
CA- Coeliac Artery
LGA- Left Gastric Artery
CHA- Common Hepatic Artery
PHA- Proper Hepatic Artery
RHA- Right Hepatic Artery
LHA- Left Hepatic Artery
SMA- Superior Mesenteric Artery
PV- Portal Vein

Author-Co-Author Contribution

NA- Design of study, Concept, Implementation of study protocol, Manuscript preparation and Submission of article;
GS- Design of study, Concept, CT Image analysis and Interpretation;
KD- Coordination and Manuscript review and revision, Literature survey, Hand-sketch images;
PM- Review Manuscript and Manuscript revision

Conflicts of Interests: None

REFERENCES

- [1]. Sridhar P, Vasanti A, Vaishaly B. Variations in origin and branching pattern of hepatic arteries and their clinical significance. *Eur. J. Anat.* 2019;23(4):279-87.

- [2]. Standring S. Gray's anatomy. 42nd edition. Churchill Livingstone: Elsevier. 2021;1211-1212.
- [3]. Abdullah SS, Mabrut JY, Garbit V, et al. Anatomical variations of the hepatic artery: study of 932 cases in liver transplantation. *Surg Radiol Anat.* 2006;28:468-73.
- [4]. Covey AM, Brody LA, Maluccio MA, Getrajdman GI, Brown KT. Variant hepatic arterial anatomy revisited: digital subtraction angiography performed in 600 patients. *Radiology.* 2002;224:542-7.
- [5]. De Santis M, Ariosi P, Calo GF, Romagnoli R. Hepatic arterial vascular anatomy and its variants. *Radiol Med (Torino).*2000;100:145-51.
- [6]. Gruttadauria S, Foglieni CS, Doria C, Luca A, Lauro A, Marino IR. The hepatic artery in liver transplantation and surgery: vascular anomalies in 701 cases. *Clin Transplant.*2001;15:359-63.
- [7]. Jones RM, Hardy KJ. The hepatic artery: a reminder of surgical anatomy. *J R Coll Surg Edinb.* 2001;46:168-70.
- [8]. Peschard F, El Hajjam M, Malafosse R, et al. A common hepatic artery passing in front of the portal vein. *Surg Radiol Anat.*2006;28:202-5.
- [9]. Volpe CM, Peterson S, Hoover EL, Doerr RJ. Justification for visceral angiography prior to pancreaticoduodenectomy. *Am Surg.*1998;64:758-61.
- [10]. Michels NA. Newer anatomy of the liver and its variant blood supply and collateral circulation. *Am J Surg.* 1966;112:337-47.
- [11]. Hiatt JR, Gabbay J, Busuttil RW. Surgical anatomy of the hepatic arteries in 1000 cases. *Ann Surg.* 1994;220:50-2.
- [12]. Ugurel MS, Battal B, Bozlar U, Nural MS, Tasar M, Ors F, Saglam M, Karademir I. Anatomical variations of hepatic arterial system, coeliac trunk and renal arteries: an analysis with multidetector CT angiography. *Br J Radiol.*2010;83(992):661-7.
- [13]. Michels NA. Blood supply and anatomy of the upper abdominal organs. Philadelphia: JB Lippincott. 1955.
- [14]. Arnold MM, Kreel L, Lo YF, Law H. Are the hepatic arteries "end arteries"? *Invest Radiol.*1991;26:337-42.
- [15]. Weiglein AH. Variations and topography of the arteries in the lesser omentum in humans. *Clin Anat.*1996;9:143-50.
- [16]. Choi TW, Chung JW, Kim HC, Lee M, Choi JW, Jae HJ, et al. Anatomic Variations of the Hepatic Artery in 5625 Patients. *Cardiothoracic Imaging.* 2021;3(4).
- [17]. Sukumaran TT, Joseph S, Ramakrishnan S, Mathew AJ. Anatomical variations of the hepatic artery in its extrahepatic journey: a cadaveric study with its clinical implications. *Anat Cell Biol.* 2022 Sep 30;55(3):269-276.
- [18]. Moon JJ, Widjicks CA, Williams JM. Right hepatic artery branching off the superior mesenteric artery and its potential implications. *IJAV.* 2009;2:143-5.

How to cite this article:

Nikhil Aggarwal, Garima Sehgal, Kaweri Dande, Punita Manik. Missing common Hepatic Artery and variant Right Hepatic Artery - An incidental finding on CT imaging. *Int J Anat Res* 2023;11(3):8659-8662. DOI: 10.16965/ijar.2023.155