

ARTHRITIS OF THE SUBTALAR JOINT ASSOCIATED WITH SUSTENTACULUM TALI FACET CONFIGURATION

K.S. Nemade ^{*1}, M.M. Meshram ², A. P. Kasote ³, N. Y. Kamdi ⁴.

^{*1} Assistant Professor, Department of Anatomy, Government Medical College, Nagpur, Maharashtra, India.

² Professor & Head, Department of Anatomy, Government Medical College, Nagpur, Maharashtra, India.

³ Associate Professor, Department of Anatomy, Government Medical College, Nagpur, Maharashtra, India.

⁴ Associate Professor, Department of Anatomy, Government Medical College, Nagpur, Maharashtra, India.

ABSTRACT

Variation in the articular facet of the sustentaculum tali have been described by many authors. Most researchers view these differences in facet configuration as anatomical variations of no functional significance. Bruckner (1987), for the first time argued that these facet configurations affect joint stability.

The purpose of this study was to determine the talar facet configuration of calcanei in India, measure the angle between the anterior and middle facet planes of these calcanei, and assess the relation between the above parameters and the degenerative changes in the subtalar joints. Study was conducted in 220 calcanei of unknown age & sex. The facet patterns observed were fused anterior and middle facets (Type I), three separate facets (Type II), absence of the anterior facet (Type III) and three merged facets (Type IV).

Osteoarthritic changes studied are lipping, eburnation on visual inspection and subchondral sclerosis on radiographs.

Present study reveals that the talar facet configuration of calcanei and the angle between the anterior and middle facets influence the stability of the subtalar joints and development of osteoarthritis.

KEY WORDS: Talar facet, Calcanei, Subtalar arthritis, Forefoot pain.

Address for Correspondence: Dr. K. S. Nemade, Flat no. 301, Swami Samartha vihar-3, plot no. 88, Ekmat Nagar, Nagpur 440034, Maharashtra, India. Mobile No.: +919623619311.

E-Mail: knkirti84@gmail.com

Access this Article online

Quick Response code



DOI: 10.16965/ijar.2014.525

Web site: International Journal of Anatomy and Research
ISSN 2321-4287
www.ijmhr.org/ijar.htm

Received: 21 Jul 2014

Peer Review: 21 Jul 2014 Published (O): 30 Nov 2014

Accepted: 10 Nov 2014 Published (P): 31 Dec 2014

INTRODUCTION

Evolution of bipedalism has resulted in many changes in human foot. One of the most important changes is development of arches of foot. Among these arches, medial longitudinal arch is most important arch. Subtalar joint is the main joint of this arch. This joint involves three facets

on calcaneum— anterior, middle and posterior. Out of these, anterior and middle facets are located on sustentaculum tali and posterior facet is located on dorsal surface.

Variation in these articular facets have been described by many authors [1,2,3,4,5,6]. These facet configurations are present in foetal

calcanei and are not developmental responses to physical activities [5]. Most of the researchers view these differences in facet configuration as anatomical variations of no functional significance. But, Bruckner argued that these facet configurations affect joint stability & responsible for early arthritic changes in some type [6] which is also supported by some other authors [7].

Subtalar instability is a major podiatric problem for foot & ankle surgeons. In children, it can lead to severe flatfoot with growing pain & quick fatigue while walking & running. It can lead to many orthopedic problems affecting ankle, knee, hip & lower back & have clinical presentations like anterior or posterior tibial tendonitis, planter fasciitis, forefoot pain etc. [8,9].

Hence the present study has been carried out to study variation in sustentaculum tali facet configurations in vidarbha and to evaluate the proposed relationship between subtalar joint morphology and the frequency of osteoarthritic changes in sustentaculum tali facet configurations i.e. subtalar joint stability.

MATERIALS AND METHODS

Total 220 calcanei of unknown age and sex were studied in present study. These were classified according to sustentacular talar facet into three groups.

Type I- Sustentaculum tali with single facet and It had two subtypes.

Type Ia- Sustentaculum tali with long continuous facet (Figure 1)

Type Ib- Transitional figure 8 forms with fused anterior & medial facets (Figure 2)

Type II- 2 facets with distinct groove separating anterior & medial facets (Figure 3)

Type III- Sustentacular tali with medial facet only & no anterior facet (Figure 4)

The configuration in which all talocalcaneal facet fused in one single facet was not observed After classifying calcanei, angle of sustentacular talar facet was determined. For this, The calcaneus was placed on its medial side on a piece of paper so that the medial border of the sustentaculum tali facets contacted the paper and the planes of the facets were perpendicular

to the surface of the paper The contour of the facets was traced with a pencil. The angle measured with a protractor. Repeated observations were made on the same series of bones indicated that the average error of this measurement is about 2° (Figure 5) [7].

Visual inspection of articular surface was made to find arthritic changes consisting periarticular remodeling & eburnation. Calcanei showing lipping were subjected to radiological examination to find subchondral sclerosis.

Arthritis was scored as present if any of these osseous changes was found on the sustentaculum tali facets, posterior talocalcaneal facet or tarsal canal. (Figure 6 and 7).

Fig. 1: Type Ia- long continuous facet.



Fig. 2: Type Ib- transitional figure 8 forms with fused anterior and medial facet.



Fig. 3: Type II- 2 facets with distinct groove separating anterior & medial facet.



Fig. 4: Type III- sustentacular tali with medial facet only & no anterior facet.



Fig. 5: Measurement of angle of intersection of sustentacular tali facet.



Fig. 6: Calcanei showing lipping at sustentacular tali facet.

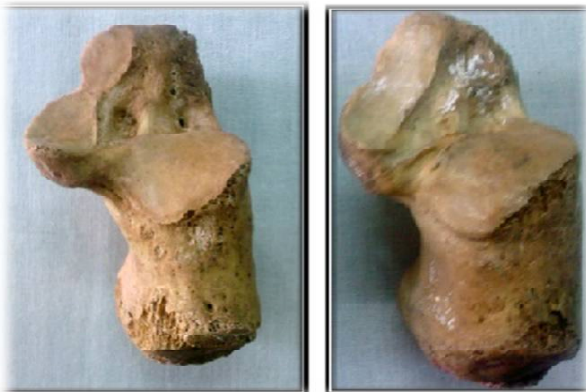

Fig. 7: Showing normal calcaneum (Rt. Side) and calcaneum with subchondral sclerosis at sustentaculum tali (Lt. side).

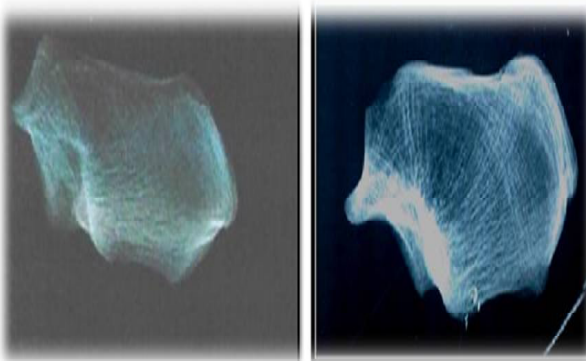
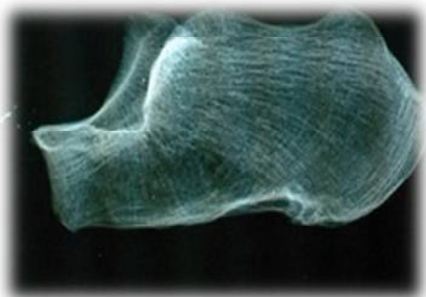


Fig. 8: Calcaneum showing subchondral sclerosis at posterior facet.



OBSERVATIONS AND RESULTS

Out of total 220 calcanei studied, 144(65.45%) calcanei had long continuous facet (Type Ia and Ib), 56(25.45%) calcanei had 2-facet configuration (Type II) and 20 (9.09%) calcanei had single facet configuration (Type III). The average angle of intersection was 140° for calcanei with long continuous facet, 128.16° for calcanei with 2-facet configuration and 126.12° for calcanei with single facet configuration. Range and S.D. of angle of intersection is given in Table no.1. These angles of intersection were compared by one way ANOVA. P value for this was 0.000 i.e. HS. Multiple comparisons was done by Bonferron test and result of which was HS (table no.1).

Out of 220 calcanei, total 146 showed arthritic lipping. Out of these 146 calcanei, 110 (76.39%) belonged to Type I, 16 (28.57%) belonged to Type II and 10 (50%) belonged to Type III. X2 test for an association between the presence of lipping and facet configuration was highly significant ($X^2 = 40.36$, $P < 0.01$; Table no. 1). Out of 146 calcanei showing arthritic lipping, subchondral sclerosis was seen in 102(70.83%) calcanei of Type I group, 10 (17.86%) calcanei of Type II group and 8 (40%) calcanei of Type III group. A x2 test for an association between the presence of subchondral sclerosis and facet configuration was highly significant ($X^2 = 47.51$, $P < 0.01$; Table 1). It was also seen that the calcanei showing arthritic changes had significantly larger sustentaculum tali facet angle than the calcanei with smaller angle.

Table 1: Total number and percentages of facet types, arthritic lipping, degrees of intersecting angles.

Facet type	Long continuous facet	2 separate facet	Medial facet only	Statistical analysis
n = 220	144	56	44	
Percentage	65.45	25.45	9.09	
Arthritic lipping				
n= 146	110	16	10	Chi sq.=40.36
Percentage	76.39	28.57	50	P < 0.01 (HS)
Subchondral sclerosis	102	10	8	Chi sq.=47.51
Percentage	70.83	17.86	40	P < 0.01 (HS)
Intersecting angle				
Average	140.6	128.16	126.12	
Minimum	111	89	101	
Maximum	167	145	151	
S. D.	10.62	12.59	11.86	

DISCUSSION

According to the present study, Type I configuration is most common configuration in Indians. Arthritic changes like lipping and subchondral sclerosis are significantly less in calcanei belonging to Type II Group than others. Thus results of present study indicates that subtalar joint stability depends on sustentacular tali facet morphology and is consistent with Buckner's hypothesis that joints with the 2-facet configuration are comparatively more stable [6]. However, Buckner has included calcanei having medial facet only configuration in Type I Group and not studied them as a separate group [6]. Results of present study are also consistent with the findings of Francine-Drayer Verhagen and Madhavi et.al [7,10].

In 2-separate facet configuration, talus and calcaneum articulate at two different locations. Articular surfaces are separated by a groove and this result in the formation of V shaped articular surface with an average angle of 128.16°. This limits medial rotation of talar head and minimizes the strain on it during heel strike. In contrast to this, in Type I group, intersecting angle is obtuse which puts more strain on talar head during medial rotation. Eventually, talar head exerts continuous and excessive pressure on spring ligament which connects sustentaculum tali with navicular leading to ligament laxity in this configuration. Laxity of ligaments and muscles is thought to be responsible for mobile or unstable feet [4,11,18].

Stability of the subtalar joint also depends on

the height of the longitudinal arch, which is determined by the inclination of the subtalar joint axis [14,16]. A high arch represents a more stable structure and is commonly referred to as a 'rigid' or cavus foot [6,12,16]. Bruckner measured inclinations of subtalar joints, and found that joints with the 2-facet configuration have a higher subtalar joint axis than the other configurations [6]. This can be explained by the analysis of intersecting angle of these facets. Relative to the rounded, continuous facet, the 2-facet configuration has an anterior facet that is slanted upwards and raises the total subtalar joint axis. On the other hand, the continuous facet is horizontally inclined, which results in a lower arch and a less stable foot [4,6,18].

In Type III calcanei, intersecting angle and arthritic changes are midway between other two groups. Here, as there is only medial facet, talar head is inadequately supported which allows excessive anterior and inferior rotation of the talus during weight bearing. This results in a valgus position of the calcaneus and a downward tilt of the talar head [4,16]. The vastly increased pressure on the anterior subtalar joint capsule causes ligamentous laxity [17]. CT scans also show that the planus foot (hypermobility or flat foot) has no anterior sustentaculum tali facet [19]. These are the possible explanation of these changes in this group.

CONCLUSION

According to the present study, Type I sustentaculum tali facet configuration is most commonly observed among Indians. Present study supports the view that certain morphological variations of the sustentaculum tali predispose people to the development of arthritic changes in the subtalar joint. Present study also concludes that people with the long continuous facet (type I) & medial facet only (type III) configuration have greater risk for subtalar joint instability than individual with the 2-facet configuration (type II).

Conflicts of Interests: None

REFERENCES

- [1]. Campos F.F, Pellico G.L. Talar articular facets (facies articulares talaris) in human calcanei. Acta Anatomica 1989; 134:124-127.

- [2]. EL-Elshi. Variations in the talar articular facets in Egyptian calcanei. *Acta Anatomica*.1974; 89: 134-138.
- [3]. Gupta S.C., Gupta C.D., Arora A.K. Pattern of talar articular facets in Indian calcanei. *Journal of Anatomy* 1977; 124: 651-655.
- [4]. Kapandji I.A. *The Physiology of the Joints*, vol. 2, Lower Limb Churchill Livingstone; New York 1970.
- [5]. Bunning PSC, Barnett C.H. A comparison of adult foetal talocalcaneal articulations. *Journal of Anatomy*1965; 99: 71-76. Bruckner J. Variations in the human subtalar joint. *Journal of Orthopaedic and Sports Physical Therapy* 1987; 8: 489-494.
- [6]. Bruckner J. Variations in the human subtalar joint. *Journal of Orthopaedic and Sports Physical Therapy* 1987; 8: 489-494.
- [7]. Francine drayer-verhagen. Arthritis of the subtalar joint associated with sustentaculum tali facet configuration. *J. Anat* 1993; 183: 631-634.
- [8]. John E. et al. Sprains- residual instability of subtalar, Lisfranc joint and turf toe. *Clin. Sports Medicine* 2004; 23: 97-121.
- [9]. Lowell Weil. Emphasizing careful assessment of the etiology and underlying contributing factor to subtalar joint instability. *Podiatry today* 2007; 20:5.
- [10]. Madhavi et. al. South Indian calcaneal talar facet configurations and osteoarthritic changes. *Clin Anat* 2008 ;21(6):581-6.
- [11]. Harrington I.J. Biomechanics of joint injuries. In *Biomechanics of Musculoskeletal Injury* E. Gozna; Williams & Wilkins1982: 31-69.
- [12]. Glancy J. Orthotic control of ground reaction forces during running (a preliminary report). *Orthotics and Prosthetics* 1984; 38:12-40.
- [13]. Laidlaw P.P. The os calcis. *Journal of Anatomy* 1905; 39: 161-177.
- [14].Mann R.A. Overview of foot and ankle biomechanics. In *Disorders of the Foot and Ankle: Medical and Surgical Management* E. H. Wickland Jr; Philadelphia W. B. Saunders 1991: 385-408.
- [15]. Norkin C.C. *Joint Structure and Function* F. A. Davis; Philadelphia 1983.
- [16]. Perry J. *Anatomy and biomechanics of the hindfoot*. *Clinical Orthopaedics and Related Research* 1983; 177: 9-16.
- [17]. Rose G.K. Pes planus. In *Disorders of the Foot and Ankle: Medical and Surgical Management* E. H. Wickland Jr; Philadelphia W. B. Saunders 1991: 892-919.
- [18]. Samilson R.L., Dillin W. Cavus, cavovarus and calcaneocavus. *Clinical Orthopaedics and Related Research* 1983; 177: 125-132.
- [18].Smith R. W. Computerized sectional imaging: computed tomography and magnetic resonance imaging of the foot and ankle. In *Disorders of the Foot and Ankle: Medical and Surgical Management* E. H. Wickland Jr; Philadelphia: W. B. Saunders 1991: 155-205

How to cite this article:

K.S. Nemade, M.M. Meshram, A. P. Kasote, N. Y. Kamdi. ARTHRITIS OF THE SUBTALAR JOINT ASSOCIATED WITH SUSTENTACULUM TALI FACET CONFIGURATION. *Int J Anat Res* 2014;2(4): 684-688.
DOI: 10.16965/ijar.2014.525