

## Case Report

# HYPEROSTOSIS OF THE FRONTAL, TEMPORAL, AND SPHENOID BONES: CASE REPORT AND REVIEW OF LITERATURE

Austin Huy Nguyen <sup>1</sup>, Mallory Moore <sup>1</sup>, and William Hunter III <sup>\*2</sup>.

<sup>\*1</sup> Creighton University School of Medicine, Omaha, Nebraska.

<sup>\*2</sup> Department of Pathology, Creighton University School of Medicine, Omaha, Nebraska.

## ABSTRACT

Hyperostosis of the internal table of the frontal bone is not an uncommon phenomenon. However, such hyperostosis of the temporal and/or sphenoid bone is rarely discussed in the available literature, especially in the absence of meningioma. We report a case of hyperostosis of the frontal, temporal, and sphenoid bones found during routine cadaveric dissection of an 81 year-old female. Histology revealed thickening and increased density of the lamellar bone. The periosteum was unaffected. Possible etiology is discussed.

**KEY WORDS:** Calvarial hyperostosis, hyperostosis frontalis interna, sphenoid bone, temporal bone, meningioma.

**Address for Correspondence:** Dr William Hunter III, Department of Pathology, Creighton University School of Medicine, 2500 California Plaza, Omaha, NE 68178. **E-Mail:** hunter@creighton.edu

## Access this Article online

### Quick Response code



DOI: 10.16965/ijar.2014.485

**Web site:** International Journal of Anatomy and Research  
ISSN 2321-4287  
[www.ijmhr.org/ijar.htm](http://www.ijmhr.org/ijar.htm)

Received: 04 Aug 2014

Peer Review: 04 Aug 2014 Published (O):31 Jan 2015

Accepted: 27 Aug 2014 Published (P):31 Mar 2015

## INTRODUCTION

Hyperostosis of the endocranial plate has been characterized as non-neoplastic benign lesions [1] with remodeling into a more cancellous phenotype [2]. An affected frontal bone, termed hyperostosis frontalis interna (HFI), comprises a majority of cases with particular prevalence in post menopausal females. HFI is usually an incidental finding and is not known to cause clinical disease [2], although excessive growth can be symptomatic upon brain tissue compression and/or cranial nerve entrapment [3]. Hyperostosis of the sphenoid bone or other bones comprising the floor of the cranium are rare and are generally seen unilaterally in association with intraosseous meningiomas [4,5]. Presently, we discuss a rare case involving hyperostosis of the sphenoid and temporal bones found during routine gross anatomy laboratory cadaveric dissection. This

hyperostosis was not found in association with evident or reported meningioma. Possible etiology is further discussed

## CASE REPORT

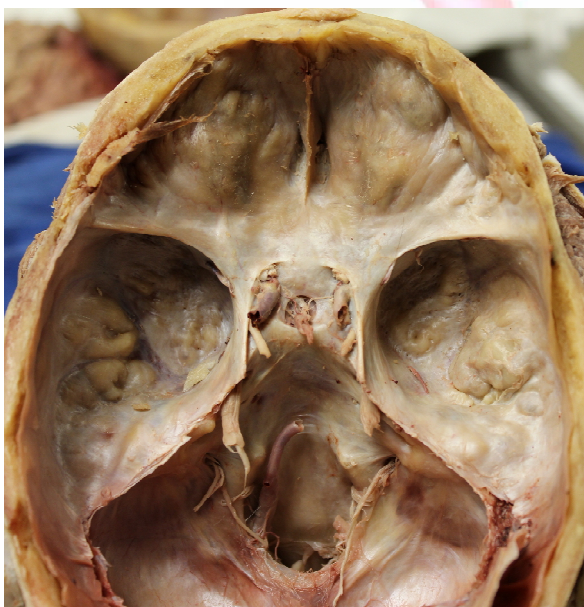The patient was an 81 year-old Caucasian female with a past medical history of osteoporosis, Alzheimer's disease, arthritis, cholelithiasis and a surgical history of hysterectomy and partial hip replacement. Death was reportedly caused by complications secondary to Alzheimer's disease.

Gross inspection of the skull revealed a frontal thickness of 11.3 mm measured in the non-hyperostotic area. This was dramatically thicker than the average female frontal bone of 6.678 mm (SD =1.123, Range = 4.490-11.260 mm) found in a study of cranial thickness in relation to age, gender, and body build [6]. The occipital bone, measured at 8.8 mm, was slightly thicker

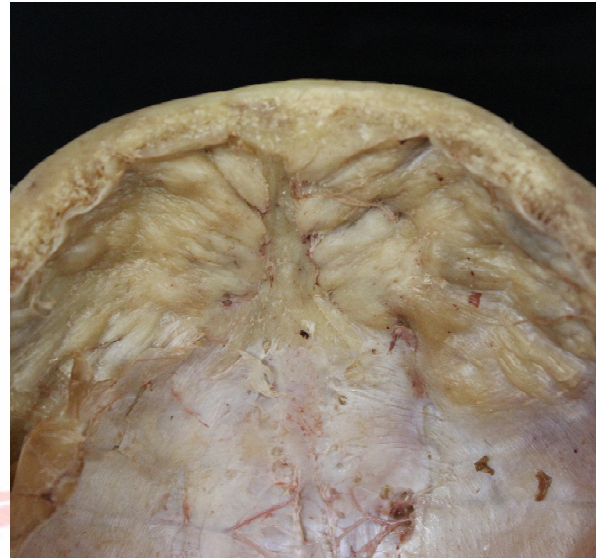
than the average of 7.603 (SD = 2.013, Range = 4.570-12.740 mm) [6]. Hyperostosis was observed (Figure 1 and 2) in the frontal bones with sparing of the midline, the sphenoid bone (average diameter of 19.6 mm), and the temporal bones (average diameter of (left) 23.0 mm and (right) 24.5 mm). The hyperostosis was bilateral and symmetrical, except the temporal bone, which was observed to have more prominence on the right side. The growths were characterized by smooth, ossified ridges and nodules protruding from the internal table of the cranium. Hyperostotic infringement into the maxillary, and sphenoid sinuses were not apparent. Hyperostosis was not present on the external surface of the skull. No significant anomalies of the dura were observed. The cerebrum presented with enlarged sulci and diminished gyri, most notably in the temporal lobes, as is characteristic of Alzheimer's disease. Coronal sectioning of the brain revealed enlargement of the ventricles. No abnormalities were observed in the cerebellum under gross inspection.

Portions of the hyperostotic tissue were fixed in 10% formalin, decalcified, embedded in paraffin and sectioned to prepare hematoxylin and eosin stained slides. Microscopically thickened compact bone was observed. No histological bony abnormalities were seen.

**Fig. 1: Superior view.** Hyperostotic growths were observed bilaterally in the sphenoid and temporal bones as smooth, ossified ridges and nodules protruding from the internal table of the cranium.



**Fig. 2: Inferior view of anterior skull cap.** The hyperostotic growths continued along the frontal bones, bilaterally. The midline was spared.



## DISCUSSION

Hyperostoses in general are non-neoplastic benign lesions with obscure pathogenesis. Moore [7] characterized this thickening as an overgrowth or deposit of cancellous bone. Furthermore, no inflammatory process is associated. Occurrence in the skull is rare (3% to 6% of cases) [1] with a majority occurring at the frontal bone, or HFI. According to a study by Moore [7] involving examination of 6,650 human skulls, 74.1% of hyperostotic cases occurred specifically in the frontal bone, with the remainder being thickening of the overall calvaria or frontoparietal hyperostosis. Herskovitz et al. [8] classified HFI into different types based on other bone involvement, degree of severity, and phenotype. HFI in particular is associated with post-menopausal women, reported to be 40% to 60% incidence rate in this population [2]. Primary hyperostosis of the sphenoid and temporal bones are rare, with sphenoid hyperostosis generally being secondary to meningiomas. While remodeling of the inner table of bones other than the frontal can be associated with other diseases such as Paget's and osteosarcoma [9], these pathologies were ruled out in the present case based on reported history and histological examination.

While hyperostosis has been characterized as benign and not causal to clinical disease [2], excessive growth can present with clinical



symptoms depending on extent and location. Overgrowth could potentially cause intracranial hypertension [1], localized headache [10], and cranial nerve entrapment [3].

The etiology of hyperostosis is unclear. The clearest association is with postmenopausal females [9]. Much evidence has been posited toward numerous attempts at explaining this pathology. Metabolic causes seem to be the most supported, including possible connections with leptin [11] and obesity [7]. The association between hyperostosis and meningiomas is well known [12]. Whether the bony change is due to tumor invasion or reactionary change, however, remains controversial [13]. Extradural meningiomas, has been discussed as a possible cause of hyperostosis in the skull with multiple possible mechanisms. These may be subclassified into intraosseous meningiomas if the tumor does not involve either the inner or outer table of the skull [10]. Head trauma has been discussed [14] as potentially causing entrapment of arachnoid cap cells in fracture sites and leading to meningioma formation [15]. The present patient, however, presented with no evidence of or reported history of head trauma. Crawford *et al.* [10] discusses a developmental origin of these hyperostoses in which during fusion of the cranial sutures, arachnoid cells become entrapped causing later intraosseous meningiomas. However, this hypothesis is not coherent with the present case in which the sphenosquamosal suture is spared. Furthermore, a majority of the primary sphenoid extradural meningiomas found in the literature are unilateral [16,17,4,10]. The current patient presented with bilateral sphenotemporal hyperostosis. Ultimately, malignancy as a cause was ruled out by histological examination.

No pathological findings were made during histological examination, other than thickening of the lamellar bone. We conclude that these sphenotemporal hyperostoses are similar in character to the more common HFI, generally asymptomatic, slow growing, benign lesions.

In summary, HFI is a common phenomenon presenting in elderly postmenopausal women. Generally, HFI is a unique, benign lesion with unclear cause but may be related to metabolic or hormonal influences. Based on past reported

history and histological and gross examination, we conclude that the sphenotemporal hyperostoses found in the present patient are a rare case not associated with extradural meningioma and are similar in character to HFI.

**Acknowledgement: None**

**Conflicts of Interests: None**

## REFERENCES

- [1]. Luccarelli G, Fornari M, Savoirdo M: Angiography and computerized tomography in the diagnosis of aneurysmal bone cyst of the skull. *Journal of Neurosurgery* 1980;53:113-116.
- [2]. She R, Szakacs J: Hyperostosis Frontalis Interna: Case Report and Review of Literature. *Annals of Clinical and Laboratory Science* 2004;34(2):206-208.
- [3]. Waterval JJ, van Dongen TM, Stokroos RJ, BeDondt BJ, Chenault MN, Manni JJ: Imaging features and progression of hyperostosis cranialis interna. *American Journal of Neuroradiology* 2012;33:453-461.
- [4]. Ferdousi MA, Sharif MM, Bahar H, Mohiuddin AS, Hossain ATMM, Banu SG: A rare case of intraosseous meningioma of the sphenoid bone - A case report. *Ibrahim Medical College Journal* 2012;6(2):73-75.
- [5]. Ravi N, Yi WX, Lu L, Ping HJ, Hao DZ: Primary extradural meningioma arising from the calvarium. *South African Journal of Radiology* 2013;17(2):70-71.
- [6]. Lynnerup N: Cranial thickness in relation to age, sex and general body build in a Danish forensic sample. *Forensic Science International* 2001;117:45-51.
- [7]. Moore S: Calvarial hyperostosis and the accompanying symptom complex. *Archives of Neurology and Psychiatry* 1936;35(5):975-981.
- [8]. Hershkovitz I, Greenwald C, Rothschild BM, Latimer B, Dutour O, Jellema LM, Wish-Baratz S: Hyperostosis frontalis interna: An anthropological perspective. *American Journal of Physical Anthropology* 1999;109(3):303-325.
- [9]. Talarico EF, Prather AD, Hardt KD: A Case of Extensive Hyperostosis Frontalis Interna in an 87 year-old Female Human Cadaver. *Clinical Anatomy* 2008;21:259-268.
- [10]. Crawford TS, Kleinschmidt-DeMasters BK, Lillehei KO: Primary intraosseous meningioma. *Journal of Neurosurgery* 1995;83:912-915.
- [11]. Ruhli FJ, Henneberg M. Are hyperostosis frontalis interna and leptin linked? A hypothetical approach about hormonal influence on human microevolution. *Medical hypotheses* 2002; 58(5):378-381.

- [12]. Pieper DR, Al-Mefty O, Hanada Y, Buechner D: Hyperostosis associated with meningioma of the cranial base: secondary changes or tumor invasion. *Neurosurgery* 1999;44(4):742-746.
- [13]. Goyal N, Kakkar A, Sarkar C, Agrawal D: Does bony hyperostosis in intracranial meningioma signify tumor invasion? A radio-pathologic study. *Neurology India* 2012;60(1):50-54.
- [14]. Sato K, Kubota T, Kawano H: Chronic diploic hematoma of the parietal bone. *Journal of Neurosurgery* 1994;80:1112-1115.
- [15]. Zhu M, Wang X, Shi C, Shen H, Lin Z: Primary diffuse intraosseous meningioma. *Chinese Medical Journal* 2013;126(7):1390-1391.
- [16]. Luetjens G, Krauss JK, Brandis A, Nakamura M: Bilateral sphenoorbital hyperostotic meningiomas with proptosis and visual impairment: A therapeutic challenge. Report of three patients and review of the literature. *Clinical Neurology and Neurosurgery* 2011;113:859-863.
- [17]. De Jesus O, Toledo MM. Surgical management of meningioma en plaque of the sphenoid ridge. *Surgical Neurology* 2001;55:265-269.

**How to cite this article:**

Austin Huy Nguyen, Mallory Moore, and William Hunter III. HYPEROSTOSIS OF THE FRONTAL, TEMPORAL, AND SPHENOID BONES: CASE REPORT AND REVIEW OF LITERATURE. *Int J Anat Res* 2015;3(1):817-820. **DOI:** 10.16965/ijar.2014.485