

VARIATIONS IN THE FORMATION AND RELATION OF MEDIAN NERVE

Amrita Bharti ^{*1}, Vaishali Mohan Paranjpe ², Makarand V Apte ³.

^{*1} Assistant professor, Dr. D. Y. Patil Medical College, Pimpri, Pune, Maharashtra, India.

² Associate professor, Dr. D. Y. Patil Medical College, Pimpri, Pune, Maharashtra, India.

³ Associate professor, D. Y. Patil Dental School, Lohegaon, Pune, Maharashtra, India.

ABSTRACT

Background: The variations related to the formation of median nerve by more than two roots are relatively less common as compared to the other types of variations of median nerve. The relation of its relation with brachial artery may have potential clinical implications especially during surgeries and nerve blocks.

Materials and Methods: The routine dissection of 10 adult cadavers including 7 males and 3 females in the Department of Anatomy during undergraduate training was carried out to detect the variations in the structure, formation and relation of Median nerve.

Results and Findings: There was a variation observed in the formation of median nerve and its relation with the brachial artery in two adult cadavers. In one male cadaver(C1), there was variation in the formation of the median nerve by more than two roots and in second female cadaver (C2), there was a variation in both formation and its relation with the brachial artery. However, in each of these cadavers the distribution of the median nerve was normal in arm, forearm and palm. There was normal pattern of formation, relation and course of Median nerve in rest of the cadavers. The arterial pattern in the arm (axillary and brachial arteries) was also found to be normal. In each case the opposite upper limb was also dissected completely to exclude bilateral abnormality. In both the cadavers, the anomaly was unilateral. Photographs of abnormalities were taken for proper documentation of the variations.

Conclusion: These variations have been explained by some embryological flats available. These variations of formation and relation of median nerve are clinically important for physicians, surgeons and anesthetists because symptoms of median nerve compression due to these variations are often confused with radiculopathy and carpal tunnel syndrome. The knowledge of these variations of median nerve is important to the surgeons and anesthetists' for carrying out surgical procedures and nerve blocks in axilla and arm.

KEY WORDS: Median nerve, Brachial artery, Brachial plexus variations.

Address for Correspondence: Dr Amrita Bharti, Assistant Professor, Dr. D. Y. Patil Medical College, Pimpri, Pune, Maharashtra, India. **E-Mail:** amrita_bhartii@yahoo.co.in

Access this Article online

Quick Response code



DOI: 10.16965/ijar.2015.215

Web site: International Journal of Anatomy and Research
ISSN 2321-4287
www.ijmhr.org/ijar.htm

Received: 15 Jul 2015

Accepted: 13 Aug 2015

Peer Review: 15 Jul 2015

Published (O): 31 Aug 2015

Revised: None

Published (P): 30 Sep 2015

INTRODUCTION

The median nerve is formed by lateral root and medial root of lateral cord and medial cord of brachial plexus respectively in the axilla. The root value of median nerve is (C5, 6, 7, 8, T1). The medial root derived from the medial cord,

carries the fibers from C8, T1 after crossing axillary artery from medial to lateral, joins with the lateral root from the lateral cord, anterior to the third part of axillary artery [1]. The median nerve runs on the lateral side of brachial artery in the arm. Thereafter it crosses the brachial

artery from front to reach the medial aspect and descend further in the arm. It enters cubital fossa as the medial most structure and descends down in the forearm to supply anterior compartment of forearm. It also supplies thenar muscles, two lumbricals and skin of the hand. The aim of this study was to detect variations in the formation, relations and course of median nerve in a study of a small sample size of cadavers.

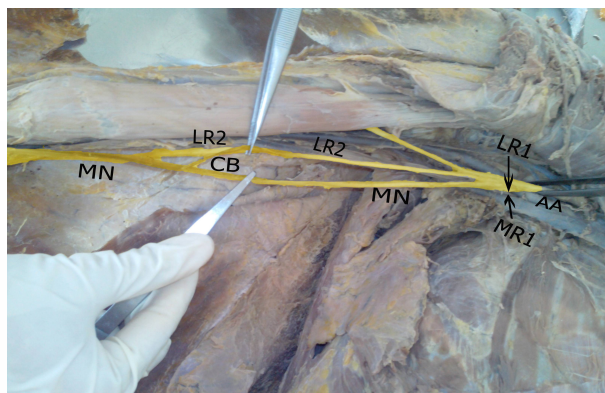
MATERIALS AND METHODS

The routine dissection of 10 cadavers, including 7 males and 3 females were performed during undergraduate teaching of students in the department of anatomy to find out the variations of the formation, course and relation of the median nerve. Dissection was done on both the upper limbs of the cadavers. Variations were observed in two of the cadavers. It was properly cleaned and photographed for proper documentation.

RESULTS AND FINDINGS

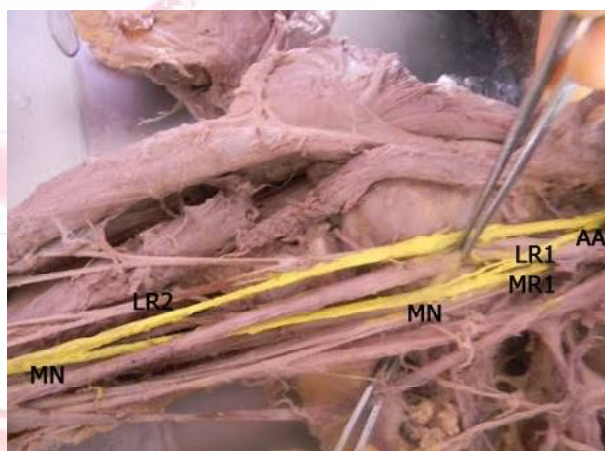
In one adult male cadaver (cadaver 1), unilateral variation was noticed in the formation of median nerve by three roots in right upper limb. There was a normal formation of the median nerve by union of two roots at the lower border of axilla, one from lateral cord (LR1) and the other from the medial cord (MR1). The median nerve lies medial to the axillary artery and then runs medial to the brachial artery. The lateral cord was giving a musculocutaneous branch piercing the coracobrachialis and another branch which unites the median nerve in the distal part of arm. This additional branch from the lateral cord can be called an additional lateral root (LR2). Additional lateral root was descending lateral to the brachial artery and joins the median nerve on its lateral aspect just above the cubital fossa. It also gives a communicating branch to the median nerve from this additional root (CB). Thereafter it crosses the median nerve and descends into the cubital fossa medial to the brachial artery. It follows a normal course in the forearm and palm. This is shown in fig 1. In another adult female cadaver (cadaver 2) variation was noticed in the formation and relation of median nerve with the brachial artery in the right axilla as shown in fig 2.

Fig. 1: Showing a Course of median nerve and communicating branches.



AA-Axillary Artery, LR1-Lateral Root 1, MR1-Medial Root 1, MN-Median Nerve, LR2-Lateral Root 2, CB-Communicating Branch.

Fig. 2: Showing formation and relation of median nerve with the brachial artery in the right axilla.



AA-Axillary Artery, LR1-Lateral Root 1, MR1-Medial Root 1, MN-Median Nerve, LR2-Lateral Root 2

The median nerve received two roots from the lateral cord. The proximal small lateral root joined medial root in the axilla forming the median nerve (LR1). Again in the middle of the arm a second larger root joined the median nerve (LR2). The median nerve crossed the brachial artery in the arm from behind instead of coming in front, thus showing a variation in its relation with the brachial artery. Rest of the course, branches and relation of median nerve towards the cubital fossa and in the forearm was normal on both the sides. The variation was unilateral with no such findings on the contralateral side.

DISCUSSION

There are many variations of brachial plexus formation and its relations mentioned in Henry Hollinshed 1969 [2]. The formation of median nerve by three roots from lateral cord and one

root from medial cord was found by Uzan et al. 2001 [3]. In the present case there are two roots from lateral cord in both the cadavers and one root from the medial cord. There is also a communicating branch from the second root to the median nerve. There were three cases of unilateral variations of formations of median nerve reported by Satyanarayan et al. 2009 [4]. He mentioned in his first case about the formation of median nerve on the medial side of axillary at a higher level. In the present study cadaver 1 (C1) shows the formation of median nerve on medial side of axillary artery anteriorly. Later it continued in the arm behind the brachial artery, where it received a communicating branch from lateral cord of brachial plexus.

As in the present case cadaver 2 (C2) where median nerve is behind the brachial artery and in case of cadaver 1 (C1), it receives a communicating branch. In his second case formation of median nerve was by three roots, two from the lateral cord and one from medial cord. This corresponds with the present study where cadaver 1 and cadaver 2 show a variation in the formation by two roots from lateral cord and one from the medial cord. In the third case median nerve was formed by four roots, three roots from lateral cord and one from medial cord. In the present case median nerve gets three roots out of which one is a communicating branch of lateral root 2(LR2).

In the present study cadaver 1 median nerve is formed medial and lies medial to the 3rd part of axillary artery. The roots of the median nerve did not join in 2.3%, both the roots travelled separately anteromedial to the axillary and brachial arteries. Nayak 2007 [5] described presence of two bands running between medial and lateral root of median nerve which compressed axillary artery. In present case cadaver 2 shows a variation in the formation of median nerve by two roots from lateral cord and one from the medial cord. The median nerve crossed the brachial artery in the arm from behind instead of coming in front, thus showing a variation in its relation with the brachial artery. Jahanshahi et al. 2003[6] described absence of musculocutaneous nerve and muscles supplied by musculocutaneous nerve were supplied by Median nerve. In present case

there is no variation with the musculocutaneous nerve. The additional root LR 2 does not supply any muscle in the arm. Nene et al. 2010 [7] described the formation of median nerve by two roots from lateral cord and one root from medial cord. Darwish et al. 2009 [8] has reported multiple variations in brachial plexus found bilaterally. The radial nerve formed by two roots, musculocutaneous nerve absent on right side, median nerve formed by four roots.

The medial root of median nerve may be compressed in the present case between the axillary artery and anterior circumflex humeral artery or by the compression of median nerve by the expanding lesions of the axillary artery [2,6]. In present case the medial root of median nerve may be compressed by a branch of axillary artery or any expanding lesions of axillary artery. Therefore this variation may be an example of high median nerve entrapment. The knowledge of the high median nerve entrapment is important for the clinicians. The knowledge of these types of variations is more important in radical neck dissection and in other surgical operation of the axilla.

Development and innervation of limbs: An approach to explain the variations:

In a developing foetus, by 30th day, the ventral column motor axons come out from spinal cord. This occurs in a craniocaudal direction. A growth cone is formed at the growing tip of axons decide the growth towards the target organ. There are filopodia present on the growth cone that grows towards target organs attracted by the molecular markers secreted from surrounding tissues. The target organs (muscles, joints, skin) secrete tropic substances which are identified by the growing axons and determine the location and innervation of the target organs. As a result of some unusual path of development of growth cone filopodia of ventral column motor axon from C5, C6, C7 spinal segments. Variations in the formation and relations may have taken place as in the present study. However the target organs were correctly identified by these growth cones and hence correct innervation of target organs has taken place.

CONCLUSION

Axilla is explored during various surgical, anaesthetic, orthopaedic and radiological procedures

of upper limb, therefore knowledge of variation with respect to brachial plexus, its branches its relations with axillary artery and brachial artery is very important for medical professionals involved in treatment, surgeries and anaesthetic blocks in axilla or upper limb. The medical professionals explore the axilla for treatment, intervention or for dissection as a part of medical undergraduate and post graduate curriculum. There must be full awareness of the origin of variation in collateral branches from the posterior aspect of the Brachial plexus and their configuration are important in interpreting diagnostic images, nerve blocks, traumatic damage and surgical procedures. The high median nerve entrapment symptoms may be used in differential diagnosis of unexplained clinical symptoms like sensory loss, pain, wakefulness and paresis. The knowledge of such rare median nerve variations is thus important for anatomists, anesthetists, radiologists and surgeons.

Conflicts of Interests: None

REFERENCES

- [1]. Grays anatomy 2000. The Anatomical Basis of Medicine and Surgery .38th Edition Edinburgh, London, New york, Philadelphia, Sydney, Toronto: Churchill Livingstone. pp.1266-1272.
- [2]. Henry Hollinshed W 1969, Anatomy for Surgeons, 2nd Edition. Volume 3. NewYork, Evanston, San Francisco, London: Harper and Row.
- [3]. Uzan A, Seelig LL Jr. A variation in formation of median nerve: communicating branch between musculocutaneous and median nerve in man. Folia Morphocol (Warsz), 2001;60:99-101.
- [4]. Satyanartayan N, Vishvakarma N, Kumar GP, Guha R, Datta AK, Sunitha P. Rare variations in the formation of median nerve –embryological basis. Nepal Med Col J. 2009;11(4):287-290.
- [5]. Nayak S. Absence of Musculocutaneous nerve associated with clinically important variations in the formation, course and distribution of the median nerve. Neuroanatomy. 2007;6:49-50.
- [6]. Jahanshahi M, Moharreri AR, Golalipour MJ. A Variation of Brachial plexus: Absence of musculocutaneous nerve. MJIH 2003;6:87-88.
- [7]. Nene AR, Gajendra KS, Sharma MVR. A rare variant formation of the median nerve. IJAV 2010;3:138-140.
- [8]. Darwish HH, Khan MM, Alkokani MAF, Zaher WA. Bilateral variation in the formation of median nerve associated with absence of musculocutaneous nerve and radial nerve with two roots, Eur J Anat. 2009;13(1):33-36.
- [9]. Zora Haviarova, Hisham El Falougya, Anna Killingerova, Viktor Matejcik. Variation of the median nerve course and its clinical importance Biomed Pap Med Fac Univ Palacky Olomouc Czech Repub. 2009;153(4):303-306.

How to cite this article:

Amrita Bharti, Vaishali Mohan Paranjpe, Makarand V Apte. VARIATIONS IN THE FORMATION AND RELATION OF MEDIAN NERVE. *Int J Anat Res* 2015;3(3):1298-1301. DOI: 10.16965/ijar.2015.215