

## Case Report

# UNILATERAL VARIATION IN THE BRANCHING PATTERN OF RIGHT AXILLARY ARTERY

A.K.Manicka Vasuki <sup>\*1</sup>, M.Nirmala Devi <sup>2</sup>, K.Kalyana Sundaram <sup>3</sup>, Deborah Joy Hezbibah <sup>4</sup>, T.K.Aleyemma Fenn <sup>5</sup>, M.Jamuna <sup>6</sup>.

<sup>\*1</sup> Assistant Professor, Department of Anatomy, PSG Institute of Medical Sciences and Research, Coimbatore, India.

<sup>2</sup> Associate Professor, Department of Anatomy, PSG Institute of Medical Sciences and Research, Coimbatore, India.

<sup>3</sup> Associate Professor, Department of Anesthesiology, Coimbatore Medical College, Coimbatore, India.

<sup>4</sup> Assistant Professor, Department of Anatomy, PSG Institute of Medical Sciences and Research, Coimbatore, India.

<sup>5</sup> Former Professor & HOD, Department of Anatomy, PSG Institute of Medical Sciences and Research, Coimbatore India.

<sup>6</sup> Professor & HOD, Department of Anatomy, PSG Institute of Medical Sciences and Research, Coimbatore, India.

## ABSTRACT

Axillary artery and its branches are prone to have variations in their course. Knowledge about such variations are important for Radiologists in imaging techniques, Surgeons, Orthopedicians and Anesthetists in performing surgeries in the axilla and giving regional nerve blocks in the axilla. During dissection of a cadaver in the department of Anatomy, PSG IMS & R, Coimbatore, India. We observed a variation in the third part of right Axillary artery. From the common trunk, Subscapular artery, Anterior and Posterior circumflex humeral arteries and Profunda brachii artery arose. Third part of Axillary artery continued down as brachial artery. We are highlighting the variation in this study.

**KEY WORDS:** Axillary Artery, Common Trunk, Arterial Variation, Profunda Brachii Artery, Clinical Significance.

**Address for Correspondence:** Dr. A.K. Manicka Vasuki, Assistant Professor, Department of Anatomy, PSG Institute of Medical Sciences and Research, Coimbatore, India.

**E-Mail:** [vasukikalyan01@gmail.com](mailto:vasukikalyan01@gmail.com)

## Access this Article online

### Quick Response code



DOI: 10.16965/ijar.2015.218

**Web site:** International Journal of Anatomy and Research  
ISSN 2321-4287  
[www.ijmhr.org/ijar.htm](http://www.ijmhr.org/ijar.htm)

Received: 21 Jul 2015

Accepted: 19 Aug 2015

Peer Review: 21 Jul 2015

Published (O): 31 Aug 2015

Revised: None

Published (P): 30 Sep 2015

## INTRODUCTION

Axillary artery begins as a continuation of third part of Subclavian artery at the outer border of the first rib. It extends upto the lower border of the Teres major muscle where it continues as a

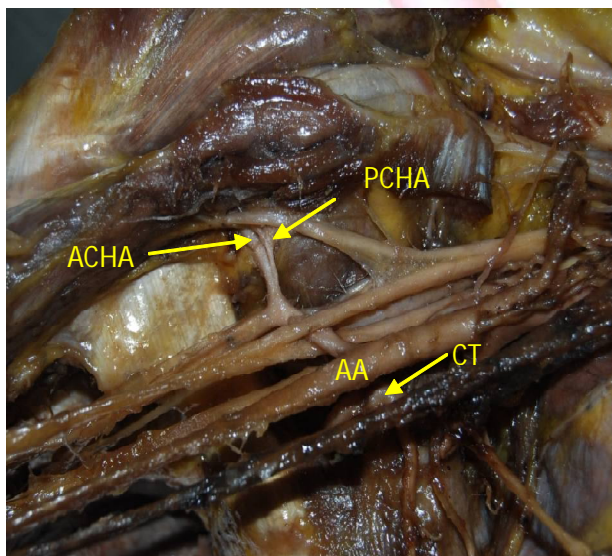
brachial artery. It is divided into three parts by Pectoralis minor. It gives off six branches, from the first part, which lies medial to Pectoralis minor, Superior thoracic artery arises; the second part gives thoracoacromial artery and

Lateral thoracic arteries which are deep to the above muscle; the third part gives Subscapular, Anterior and Posterior circumflex humeral arteries which are lateral to the above muscle. In upto 30% of the cases, the Subscapular artery can arise from a common trunk with Posterior circumflex humeral artery. Occasionally Subscapular artery, Anterior and Posterior circumflex humeral arteries and Profunda brachii artery arise as common trunk. The Posterior circumflex humeral artery may arise from a Profunda brachii artery and pass back below the teres major to enter the Quadrangular space [1].

### CASE REPORT:

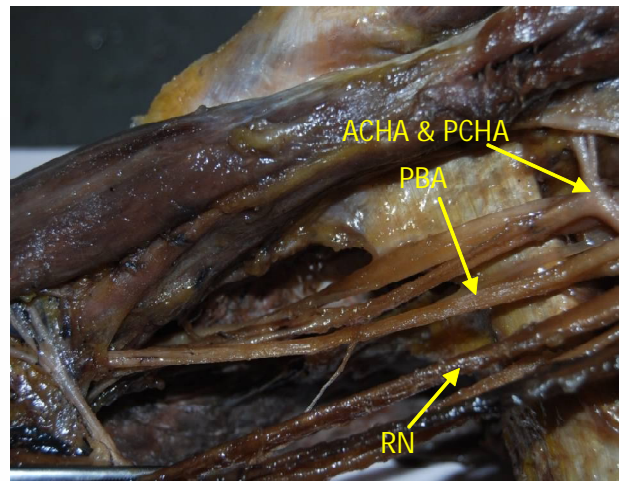
During routine dissection in the department of Anatomy, PSG IMS & R, Coimbatore, India, the axillary region of right upper limb was exposed in a cadaver. A variation in the branching pattern of third part of right Axillary artery was observed. From the first part of Axillary artery superior thoracic artery arose as usual and from the second part of Axillary artery, Lateral thoracic artery and Thoracoacromial artery arose as usual. From the third part of Axillary artery, Subscapular artery, anterior circumflex humeral artery, Posterior circumflex humeral artery and Profunda brachii artery arose from a common trunk. In the left upper limb, the branches of Axillary artery were found to be normal.

**Fig. 1:** Showing the variation in the branching pattern of third part of right Axillary artery.



AA-Axillary Artery, CT-Common Trunk, SA-Subscapular Artery, ACHA-Anterior Circumflex Humeral Artery, PCHA -Posterior Circumflex Humeral Artery.

**Fig. 2:** Showing the variation in the branching pattern of third part of left Axillary artery.



ACHA-Anterior Circumflex Humeral Artery, PCHA-Posterior Circumflex Humeral Artery, PBA-Profunda Brachii Artery, RN-Radial Nerve.

### DISCUSSION

According to Arey LB 1957 [2], the unusual blood vessels may be due to

- The choice of unusual paths in primitive vascular plexuses
- The persistence of vessels which are normally obliterated
- The disappearance of vessels which are normally retained
- Incomplete development and fusion and absorption of the parts which are usually distinct.

In a study Divya agarwal et al. 2013 [3] reported second part of Axillary artery with only a Thoracoacromial artery and third part gave the anterior circumflex humeral artery and a common trunk which gave Lateral thoracic artery, Subscapular artery, Posterior circumflex humeral artery, Circumflex scapular artery and a muscular branch.

Satabdi sarkar, Banani kundu et al. 2014 [4] observed from the second part of Axillary artery, Thoracoacromial branch alone and from the third part of Axillary artery, anterior circumflex humeral artery and a common trunk from which muscular branch, Lateral thoracic artery, Subscapular artery and Posterior circumflex humeral artery. Thoracodorsal nerve accompanied the lateral thoracic artery instead of Subscapular artery.

T.Ramesh rao et al. 2008 [5] found third part of Axillary artery gave a common trunk, from which

Subscapular artery, anterior circumflex artery, Posterior circumflex humeral artery, Profunda brachii artery and ulnar collateral artery. This common trunk was found arising between the two roots of Median nerve.

Ranjana verma et al. 2014 [6] encountered the second part of Axillary artery Thoracoacromial artery, Subscapular artery and a collateral branch. From the collateral branch, Anterior and posterior circumflex humeral artery and Accessory scapular artery arose. The Subscapular artery further subdivided into Circumflex humeral artery and Thoracodorsal artery. Third part of Axillary artery had no branches and continued down as brachial artery.

Kumar naveen et al. 2014 [7] observed an arterial trunk from third part of Axillary artery which coursed backwards and downwards passing between two roots of Median nerve. This anomalous trunk gave all the three branches of third part of Axillary artery before it continued as Profunda brachii artery.

Ishwar B.Bagoji et al. 2013 [8] encountered the anomalous branching in the third part of Axillary artery which was terminated into Subscapular arterial trunk, Superficial and deep brachial artery. From the Subscapular arterial trunk, Circumflex scapular artery, Thoarcodorsal artery, Posterior circumflex humeral artery, Thoracoacromial artery and Lateral thoracic arteries arose. The deep brachial artery in the arm gave anterior circumflex humeral artery at the surgical neck of humerus which terminated in the cubital fossa by dividing into radial and ulnar arteries. The superficial brachial artery gave two profunda brachii artery, both of which passed through spiral groove along with Radial nerve.

Sathyanarayana N et al. 2012 [9] observed that a common trunk arose from third part of Axillary artery which gave rise to Lateral thoracic artery, Anterior and Posterior circumflex humeral arteries. Subscapular artery took its origin separately from third part of Axillary artery.

Rajesh astik et al. 2012 [10] dissected eighty upper limbs. They found six different arterial variations of Axillary artery. The lateral thoracic artery arose from Subscapular artery in nine cadavers, unilaterally in two cases and bilaterally in seven cases. Absence of

thoracoacromial artery trunk with origin of all branches was directly from Axillary artery bilaterally in three cases. A division of Thoracoacromial trunk gives rise to deltoacromial and clavipectoral trunks in three cadavers. From third part of Axillary artery, a common trunk gave origin to Anterior and Posterior circumflex humeral arteries, Subscapular arteries and Profunda brachii arteries in five cadavers. Double Posterior circumflex humeral artery was found in one cadaver – one from third part of Axillary artery and the other from brachial artery.

This study correlates with our study. In this study five cadavers showed common trunk from third part of Axillary artery gave Anterior and Posterior circumflex humeral arteries, Subscapular artery and Profunda brachii artery.

Variations in branching pattern of Axillary artery are due to defects in embryonic development of the vascular plexus of upper limb bud.

Embryologically, Axillary artery represents axial system of development together with brachial and anterior interosseous artery. In later stages of development, superficial brachial artery from Axillary artery develops and continues as Radial artery. However the definitive Radial artery develops as a result of regression of Median artery and anastomoses between brachial and superficial brachial artery with regression of proximal segment of superficial brachial artery.

The anomalous branching pattern of Axillary artery was observed on the basis of there may be persistence vessels which normally obliterate and disappearance or failure of vessels which normally persist.

## CONCLUSION

Axillary artery and its branches are prone to have variations in their course. Prior knowledge about the variations is important in performing surgeries in the axilla and also in giving regional nerve blocks in the axilla.

Knowledge of branching pattern of Axillary artery is necessary while doing the antegrade cerebral perfusion in aortic surgery in case of Axillary artery thrombosis, creating axillary coronary bypass shunt in high risk individuals, reconstructing Axillary artery after trauma, using

the artery for microvascular graft to replace the damaged arteries and use the medial arm skin flap and during the surgical procedure of fracture of upper end of humerus and during Mastectomy with Axillary dissection for carcinoma Breast.

Sound knowledge of Axillary artery variation is important for surgeons, next to the popliteal artery; the Axillary artery is more frequently lacerated by violence than any other injury. It is found to be ruptured in an attempt to reduce old dislocations, especially when artery is adherent to articular capsule. Hence Radiologists, Anesthetists, Surgeons and Orthopedicians should know the Axillary artery branching pattern and its variations.

**Conflicts of Interests: None**

## REFERENCES

- [1]. Susan standing. Pectoral girdle, Shoulder region and axilla in the anatomical basis of clinical practice, Gray's Anatomy, 40<sup>th</sup> ed. London: Churchill Livingstone 2008. p.817.
- [2]. Arey LB. Developmental Anatomy, 6<sup>th</sup> ed. Philadelphia, W.B.Saunders. 1957;375-77.
- [3]. Divya agarwal, Narendra singh, Biswa Bhusan Mohanty, and Prafulla Kumar Chinara. Variation in the branching pattern of Axillary artery – a case report. Int.J.Anat Var.2013;6:31-33.
- [4]. Satabdi sarkar, Banani kundru, Pallab Kumar Saha. Variation of branching pattern of Axillary artery. Int.J.Anat.var.2014;7:27-29.
- [5]. T.Ramesh Rao, Prakashchandra shetty, R. Suresh. Abnormal branching pattern of Axillary artery and its clinical significance. Int.J.Morphol. 2008;26(2):389 – 92.
- [6]. Ranjana verma, Sabita Mishra, Anita Mahajan. Unilateral variation in the branching pattern of Axillary artery: A cadaveric study. Int.J.Anat.Res 2014;2(1): 292-94.
- [7]. Kumar Naveen, Patil Jyothsna, Satheesha B Nayak, Rao KG Mohandas, Ravindra S Swamy, R Deepthinath, Surekha D Shetty. Variant origin of an arterial trunk from Axillary artery continuing as profunda brachii artery – A unique arterial variation in the axilla and its clinical implications. Ethop J Health Sci. Jan 2014;24(1):93-96.
- [8]. Bagoji IB, Hadimani GA, Bannur BM, Patil BG, Bharatha A. A unique branching pattern of the Axillary artery: A case report. J Clin Diagn Res. 2013 Dec;7(12):2939-40. doi: 10.7860/JCDR/2013/5883.3795. Epub 2013 Dec 15.
- [9]. Satyanarayana N, Arul moli R, Sunitha P, Chandralekha G, Ravindranath G, Jayasree N, Srilahari N. Variation in the branching pattern of right Axillary artery in a Malaysian adult male cadaver – a case report. IOSR Journal of Pharmacy 2012;2(5):19-22.
- [10]. Astik Rajesh, Urvi Dave. Variations in branching pattern of the axillary artery: a study in 40 human cadavers. Jornal Vascular Brasileiro 2012; 11(1):12-17.

### How to cite this article:

A.K.Manicka Vasuki, M.Nirmala Devi, K.Kalyana Sundaram, Deborah Joy Hebzibah, T.K.Aleyemma Fenn, M.Jamuna. UNILATERAL VARIATION IN THE BRANCHING PATTERN OF RIGHT AXILLARY ARTERY: A CASE REPORT. Int J Anat Res 2015;3(3):1312-1315. DOI: 10.16965/ijar.2015.218