

A STUDY OF ANOMALIES OF LEFT RENAL VEIN

Namburu Bhanu Sudha Parimala ^{*1}, Pitta Venkata Chandrika ², Sangam Muralidhar Reddy ³.

Associate Professor ^{*1}, Assistant Professor ², Professor and HOD ³.

Department of Anatomy, N.R.I Academy of Medical Sciences, Guntur District, Andhra Pradesh, India.

ABSTRACT

Introduction: The left renal vein is preferred over the right in renal transplantation because of its longer length. It is important for the surgeons to know the course of the left renal vein and whether it is pre-aortic or not to avoid unexpected hemorrhage and even death. There are considerable no of radiological studies on Retro aortic Left Renal Vein but anatomical studies other than the Japanese were not found in the literature. In view of its anatomical, embryological, clinical and surgical importance the present study was undertaken.

Materials and Methods : The present study was conducted in 60 adult cadavers (10 female and 50 male) allotted to 1stM.B.B.S and M.D P.G students at Pinnamaneni Siddhartha institute of medical sciences & research foundation Gannavaram & N.R.I. Academy of Medical Sciences, Andhra Pradesh, India for routine dissection over a period of 5 consecutive years (2010-2015).

Results: Left Renal Vein anomalies can be classified into 4 types in the literature.Type1 is the most common in its occurrence followed by type 3,2and 4.Type 4 was rarely reported .In the present study the percentage of incidence of type 1, type 2 and type3 are 6.6%,1.6%,3.3% respectively and type 4 was not observed.

Conclusion: Knowing the variable expressions of the renal venous system allows better understanding of the clinical events. Pre operative CT can be considered mandatory as it helps in safe surgical outcome particularly in the retro peritoneal area.

KEY WORDS: Retro aortic left renal vein, Renal transplantation, Haemorrhage, Embryology.

Address for Correspondence: Dr. N. B. S. Parimala, MBBS, M. D. (Anatomy), Associate Professor, Department of Anatomy, N.R.I Academy of Medical Sciences, China kakani, Guntur District, Andhra Pradesh, India-522 503 Mobile no: +919440791896 **E-Mail:** nbsparimala@gmail.com

Access this Article online

Quick Response code



DOI: 10.16965/ijar.2015.241

Web site: International Journal of Anatomy and Research
ISSN 2321-4287
www.ijmhr.org/ijar.htm

Received: 11 Aug 2015 Accepted: 04 Sep 2015
Peer Review: 11 Aug 2015 Published (O): 30 Sep 2015
Revised: None Published (P): 30 Sep 2015

INTRODUCTION

Congenital venous abnormalities in the retroperitoneal space are relatively infrequent and Under normal circumstances they are asymptomatic, but have clinical importance due to the fatal complications that occur if left unnoticed. The left renal vein is 3 times longer than the right (7.5 & 2.5cm) and for this reason the left kidney is the preferred side for live donor

nephrectomy .The left renal vein may be double, one vein passing posterior, the other anterior, to the aorta before joining the inferior vena cava. This is sometimes referred to as persistence of "renal Collar". The anterior vein may be absent so that there may be a single retro aortic left renal vein [1].

The process of development of the renal veins which extends from the fourth to eighth week

of intra uterine life is a part of the complex developmental process of inferior vena cava. Three pairs of parallel veins, the posterior cardinal veins, the sub cardinal veins and the supracardinal veins are involved in this process. The renal veins are formed from persistence of anastomosis of the later [2].

The left renal vein is preferred over the right in renal transplantation because of its longer length. It is important for the surgeons to know the course of the left renal vein and whether it is pre-aortic or not to avoid unexpected hemorrhage and even death. A number of radiological studies on Retro aortic Left Renal Vein were reported but reports on anatomical studies are scanty. In view of its anatomical, embryological, clinical and surgical importance the present study was undertaken.

MATERIALS AND METHODS

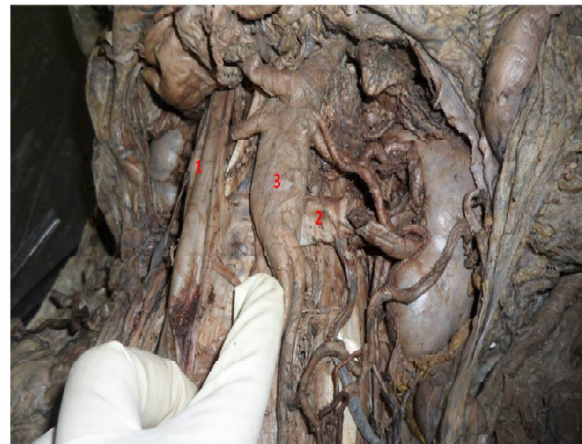The present study was conducted in 60 adult cadavers (10 female and 50 male) allotted to undergraduate and postgraduate students at Pinnamaneni Siddhartha institute of medical sciences & research foundation Gannavaram & N.R.I. Academy of Medical Sciences, Guntur, India. for routine dissection over a period of 5 consecutive years (2010-2015). During dissection of abdomen region, the peritoneal organs were removed and the kidney along with its blood supply was carefully dissected and any variations present were observed. In the present study variations of the left renal vein in relation to its course were recorded.

OBSERVATIONS

The left renal vein instead of its normal course in front of the aorta has taken a retro aortic course before it opens into the inferior vena cava in 4 cadavers (Fig.1), 1specimen the level of termination was L3-4 junction (Fig.2). The other tributaries of left renal vein the testicular and supra renal vein were normal in their course and termination. The other unusual variation observed in 2 cases was that left renal vein received left testicular vein and after a short course divided into two veins of almost equal calibre out of which one vein passed front and other behind the aorta at a lower level to terminate in inferior vena cava, so called as

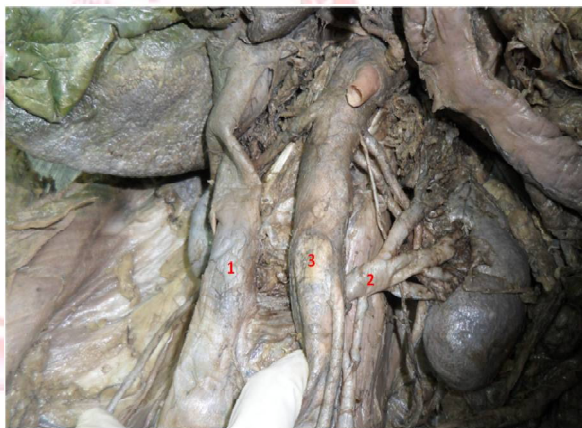
circum aortic left renal vein (Fig.3). The incidence of Left Renal Vein Anomalies in the present study was represented in table 1.

Fig. 1: Retro Aortic Left Renal Vein—Type 1.



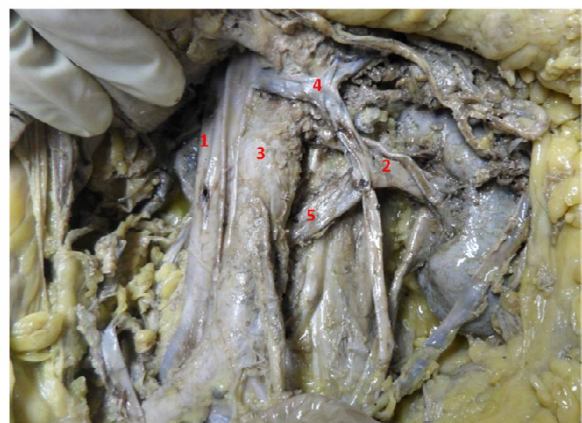- 1 - Inferior vena Cava
- 2 - Retro Aortic Left Renal Vein (horizontal)
- 3 - Abdominal Aorta

Fig. 2: Retro Aortic Left Renal Vein—Type 2.



- 1 - Inferior vena Cava
- 2 - Retro Aortic Left Renal Vein (oblique) opening into Inferior vena Cava at L3-4 level
- 3 - Abdominal Aorta

Fig. 3: Circum Aortic Left Renal Vein—Type 3.



- 1 - Inferior vena Cava
- 2 - Left Renal Vein
- 3 - Abdominal Aorta
- 4 - Pre Aortic limb of Circum Aortic Left Renal Vein
- 5 - Retro Aortic limb of Circum Aortic Left Renal Vein

Table 1: Incidence of Left Renal Vein Anomalies in the present study.

s.no	Type of variation	No .of cases	%
1	Retro aortic left renal vein (type 1)	4/60	6.6
2	Retro aortic left renal vein (type 2)	1/60	1.6
3	circum aortic left renal vein (type 3)	2/60	3.3

DISCUSSION

There are number of clinical studies on Left renal vein based on various radiological modalities like ultrasound ,MDCT,MRI,CT guided angiography but very few anatomical studies are available. The present study is undertaken owing to its morphological, embryological, clinical and surgical importance.

Major venous anomalies of inferior vena cava includes: duplication of the inferior vena cava, transposition of inferior vena cava (left IVC), circumaortic (left) renal vein, retroaortic (left) renal vein, absence of the hepatic portion of the inferior vena cava [2,3].

During the development of the IVC, there are anastomotic communications between the subcardinal and supracardinal channels that form a collar of veins encircling the aorta. The ventral portion of the circumaortic collar persists as the normal left renal vein. If the dorsal portion of this collar persists, then the left renal vein is posterior to the aorta, forming a Retro Aortic Left Renal Vein (RLRV). The circumaortic left renal vein (CALRV) or venous collar is due to the persistence of subsupracardial and intersupracardial anastomoses along with the dorsal limb of the left renal vein [4].

Among a series of 1008 kidneys studied by Satyapal et al, retroaortic left renal vein and circumaortic left renal vein anomaly was seen in only 0.5% and 0.3% respectively [5].

In another CT study of Trigaux et al, they observed 1014 cases and found that retroaortic left renal vein and circumaortic left renal vein anomaly was seen in 3.7% and 6.8% respectively [6].

Reed et al investigated 433 cases in a CT study and found that retroaortic left renal vein and circumaortic left renal vein anomaly was seen in 1.8% and 4.4% respectively [7].

karkos et al 2001, described retroaortic left renal vein as normal vein crosses the aorta in posterior face instead of the anterior face and Circumaortic left renal vein as a periaortic venous ring. The incidences of RLRV and CALRV are 0.3-1.9% ,1.5-8.7% respectively [8].

Both circumaortic and retroaortic left renal veins are the result of persistence of the dorsal limb of the embryonic left renal vein and of the dorsal arch of the renal collar (intersupracardinal anastomosis). However, in retroaortic left renal vein the ventral arch regresses so that a single renal vein passes posterior to the aorta. Circumaortic left renal vein is seen in 0.3% to 3.7% and the retroaortic left renal vein is seen in 0.5% to 6.8% of the population [9].

Hoeltl et al [10] classified the RLRV into 2 distinct types: type 1 is an orthotopic retroaortic renal vein; in type 2, a single LRV descends the renal hilum to the level of L4–L5, joins the testicular (or ovarian) and ascending lumbar veins before joining the IVC, and passes behind the aorta and in front of the vertebra. The circumaortic LRV has been defined as a third type of RLRV by numerous investigators in the literature. In this anomaly, 2 LRVs are present. One vein passes posterior and the other vein passes anterior to the aorta to join the IVC.[11]Type 4 has also been described where the LRV drains into common iliac vein after receiving its tributaries [11,12].

The most common urological symptom was hematuria. The frequency of urological symptoms was higher in groups II and IV compared to the other groups [12]. The most common type of RLRV is type I [12, 13].

Multidetector computed tomography (MDCT) angiographic study conducted in 1856 patients who underwent CT with urological symptoms (hematuria, flank and abdominal pain, left gonadal vein varicocele). Left renal vein anomalies were classified into four types according to their appearance: I) RLRV joining the inferior vena cava (IVC) in the orthotopic position; II) RLRV joining the IVC at level L4–L5; III) circumaortic or collar left renal vein; IV) RLRV joining the left common iliac vein. According this study the incidence of type 1-3.6%, type2-1.4%, type3-1.2%, type 4-0.9% [13].

Patients with urological problems, such as

hematuria, flank and abdominal pain, varicocele, and UPJO(uretero pelvi junction obstruction), were studied with MDCT.

9 of the 12 patients were available for evaluation of which the number of patients with type I, II, III, and IV of RLRV were 6, 2, 1, and 0 respectively [14].

These anomalies have a low prevalence, the type I retroaortic left renal vein (LRV), with an incidence of 0.3–0.9% joining the inferior vena cava (IVC) in orthotopic position; the type II LRV that joins the IVC lower, at L4–L5 has an incidence of 0.4–0.9%; circumaortic LRV (0.5–1.4%)[15]. Table 2 shows the comparison of Incidence of Type 1 and Type 3 anomalies of Left renal Vein. Table3 shows Comparison of Incidence of Type 2 Retro Aortic Left renal Vein reported in different studies.

Table 2: Comparison of Incidence of Type 1 and Type 3 anomalies of Left renal Vein.

Author	Retro aortic left renal vein (Type1) %	Circum aortic left renal vein (Type3) %
Satyapal et al 1999 [5]	0.5	0.3
Trigaeux et al 1998 [6]	3.7	6.8
Reed et al 1982 [7]	1.8	4.4
Kakros et al 2001 [8]	0.3- 1.9	1.5 -8.7
Yesildag et al 2004 [9]	0.5 -6.8	0.3-3.7
Karmann et al 2007 [13]	3.6	1.2
Aljabri et al 2011 [15]	0.3- 0.9	0.5-1.4
Present study	6.6	3.3

Table3: Comparison of Incidence of Type 2 Retro Aortic Left renal Vein.

Study	Retro aortic left renal vein (Type2) %
Karmann et al 2007 [13]	1.4
Aljabri et al 2011 [15]	0.4–0.9
Present study	1.6

An autopsy study done in Colombian subjects in 156 subjects 2 specimens have shown retro aortic course (1.3%) and in 1 case the course was circum aortic (0.6%).The low incidence of the retroaortic and circumaortic expressions could be a morphological trend of the Mestizo population [16] .very low incidence in this work (0.6%), a finding consistent with the reports by Satyapal et al. (1999) [5] and Baptista-Silva et al. (1997) [17].

Japanese studies are among the few anatomical studies available in literature where very low incidence of RALRV was observed. A study conducted in 203 Japanese cadavers only 1 case (0.49%) of RALRV was found [18] .The other Japanese studies by Okamoto (1990) and Izumiyama and Horiguchi (1997) the incidence was reported to be 0.74% and 0.75%, respectively [19,20]. Racial Differences may be the cause for such low incidence in these studies.

In a case of hypertensive, but otherwise healthy, middle aged male, with left sided varicocele, and symptoms of giddiness, palpitation but no haematuria a Posterior nutcracker phenomenon was identified on a CT scan, during the work up done for his labile hypertension. This case study has emphasized the importance of including retro aortic left renal vein in the differential diagnosis of labile hypertension. Early and proper diagnosis would spare many unwanted investigations [21].

The left renal vein hypertension (LRVH) syndrome or ‘Nutcracker syndrome’ was first described by Deschepper in 1972 [22]. It defines the compression of left renal vein with the development of renal venous hypertension that if transmitted backwards to the parenchyma, could result in various symptoms. The compression mechanism or the nutcracker phenomenon is diverse, the most frequent type being vein trapping in the aortic-mesenteric space which is due to aneurismal dilatation of aorta (anterior Nutcracker phenomenon). The retroaortic or circumaortic renal vein may be compressed between the aorta and the vertebral body, which is called posterior nutcracker. The clinical features of NP or posterior NP vary from asymptomatic microhematuria to severe pelvic congestion [23].

Hematuria is the most common symptom and is due to rupture of thin-wall varices into the collecting system, secondary to elevated venous pressure. Pain is the next most common symptom [23,24]. Congested kidney and renal infarcts secondary to posterior nutcracker phenomenon may lead to bacterial localization and abscess formation. Aortic thrombosis is a recognized complication of infection and sepsis [25]. Neonatal cases with septicaemia, renal abscess due to nutcracker phenomenon were

reported.

These anomalies are asymptomatic usually but AAA (Abdominal Aortic Aneurysm) when ruptured into a Retro aortic left renal vein unique syndrome characterized by the: continuous Abdominal bruit, abdominal and left flank pain with an associated pulsatile mass (Mansour Triad) [26]. Exposure of the proximal aorta and performing the proximal graft anastomosis is the major technical problem associated with anomalies of the renal vein or IVC; Clamping the aorta is feasible above or below a retroaortic LRV type I. (Shindo et al., 2000) [12].

Arslan et al reported that the incidence rates of the RLRV were 1.7% and 1.6% in men and women, respectively, by evaluating 1125 consecutive abdominal computed tomographic scans. Varicocele was found in 7 (77%) of 9 patients by scrotal color Doppler ultrasonography (CDU). They suggested that the RLRV could be one of the possible etiologic reasons for varicocele development [27].

A study was conducted on 140 patients with varicocele and 137 control patients. Thirteen (9.3%) of the 140 patients with varicocele had RLRV. Three (2.2%) of the 137 control patients had RLRV. Isolated right varicocele was not identified in any of the patients with varicocele. Significantly higher incidence of RLRV in patients with varicocele compared with age-matched control patients was noticed [28].

It is difficult to compare all the 4 types because major studies have reported type 1 and type 3 only. In some articles only type 1 was described. Type 4 anomaly was rarely reported in literature. In the present study Type 1, 2 and 3 were observed, when compared the findings were similar to the study conducted by Yesildag et al. [9]. Type 4 anomaly was not seen in this study.

CONCLUSION

Left renal vein anomalies are classified into 4 types by some authors but broadly come under 2 categories i.e; retro aortic and circum aortic types. The Retro aortic type can be subdivided into 3 types based on level of termination into inferior vena cava. Racial differences in the incidence of these anomalies are a notable feature.

Knowledge of anomalies of left renal vein is essential for surgeons, radiologists in particular and also for anatomists. These anomalies though mostly asymptomatic, occasionally may pose life threatening situation during surgeries of retro peritoneal region when ignored. Knowing the variable expressions of the renal venous system allows better understanding of the clinical events. Pre operative CT can be considered mandatory as it helps in safe surgical outcome.

Conflicts of Interests: None

REFERENCES

- [1]. Anthony R Mundy, Kidney And Ureter, Susan Stranding, GRAY's Anatomy 39th edition, Elsevier Pub 2005; Pg 1274-7.
- [2]. Moore KL, The Developing Human Clinically Oriented Embryology. Philadelphia: W.B. Saunders Company; 1998. p. 352-5.
- [3]. Babian RJ, Johnson DE. Major venous anomalies complicating retroperitoneal surgery, South Med J 1979;72:1254-8.
- [4]. Mathews R, Smith PA, Fishman EK, Marshall FF. Anomalies of the inferior vena cava and renal veins: embryologic and surgical considerations. Urology 1999; 53:873-80.
- [5]. Satyapal KS, Kalideen JM, Haffejee AA, Singh B, Robbs JV. Left renal vein variations. Surg Radiol Anat 1999;21:77-81.
- [6]. Trigaux JP, Vandroogenbroek S, De Wispelaere JF, Lacrosse M, Jamart J. Congenital anomalies of the inferior vena cava and left renal vein: evaluation with spiral CT. J Vasc Interv Radiol 1998;9:339-45.
- [7]. Reed MD, Friedman AC, Nealey P. Anomalies of the left renal vein: analysis of 433 CT scans. J Comput Assist Tomogr 1982;6:1124-6.
- [8]. Karkos CD, Bruce IA, Thomson GJ, Lambert ME. Retroaortic left renal vein & its implications in abdominal aortic surgery. Ann Vasc Surg 2001;15:703-8.
- [9]. Yesildag A, Adanir E, Koroglu M, Baykal B, Oyar O, Gulsoy UK. Incidence of left renal vein anomalies in routine abdominal CT scans. Tani Girisim Radyol 2004;10:140-3.
- [10]. Hoeltl W, Hruby W, Aharinejad S. Renal vein anatomy and its implication for retroperitoneal surgery. J Urol 1990;143:1108-1114.
- [11]. Bass JE, Redwine MD, Kramer LA, Huynh PT, Harris JH. Spectrum of congenital anomalies of the inferior vena cava: cross-sectional imaging. Radiographics 2000;20:639-652.
- [12]. Shindo S, Kubota K, Kojima A, Iyori K, Ishimoto T, Kobayashi M, et al. Anomalies of inferior vena cava and left renal vein: risks in aortic surgery. Ann Vasc Surg 2000;14:393-6.

- [13]. Karaman B, Koplay M, Ozturk E, Basekim CC, Ogul H, Mutlu H, et al. Retroaortic left renal vein: multidetector computed tomography angiography findings and its clinical importance. *Acta Radiol* 2007;48:355-60.
- [14]. Nam JK, Park SW, Lee SD, et al. The clinical significance of a retroaortic left renal vein. *Korean J Urol* 2010;51:276-80.
- [15]. Aljabri B, McDonald PS, Satin R, Stein LS, Obrand DI & Steinmetz OK. Incidence of major venous and renal anomalies relevant to aortoiliac surgery as demonstrated by computed tomography. *Annals of Vascular Surgery* 2011;15(6):615-618.
- [16]. Luis ernesto ballesteros, vladimir saldarriaga, luis miguel ramirez, Morphologic evaluation of the renal veins: a study with autopsy material from Colombian subjects; *Rom J Morphol Embryol* 2014;55(1):77-81
- [17]. Baptista-silva jc, verissimo mj, castro mj, câmara al, pestana jo, anatomical study of the renal veins observed during 342 living-donor nephrectomise. *SAO Paulo Med j.* 1997;115(3):1456-1459.
- [18]. Kazuya yoshinaga, katsushi kawai and kodo kodama, An Anatomical Study of the Retroaortic Left Renal Vein, *Okajimas Folia Anat. Jpn*,2000;77(2-3):47-52.
- [19]. Okamoto K. The posterior renal vein (new definition),together with its morphological significance. *Okajimas Folia Anat Jpn* 1990;67:203-218.
- [20]. Izumiyama M and Horiguchi M. Two cases of the retroaortic left renal vein and a morphogenetic consideration of the anomalous vein. *Acta Anat Nippon* 1997;72:535-543.
- [21]. K Hemalatha, R Narayani, Myuri Moorthy, M Paul Korath, K Jagadeesan. Retroaortic left renal vein and hypertension. *Bombay Hospital Journal*, 2008;50(1):6-9.
- [22]. De Schepper A, Belge J. "Nut cracker" phenomenon of the renal vein and venou pathology of the left kidney (in Dutch). *Radiol* 1972;55:507-11.
- [23]. Andrew KK, Thom WR. Nutcracker phenomenon and nutcracker syndrome. *Mayo Clin Proc* 2010;85:552-9.
- [24]. Rudloff U, Holmes RJ, Prem JT, et al. Mesoaoortic compression of the left renal vein (nutcracker syndrome): case reports and review of the literature. *Ann Vasc Surg* 2006;20:120-9.
- [25]. Cohen IJ, Yanai-Inbar I. Neonatal aortic thrombosis: A case description and an explanation for pathogenesis. *Clin Pediatr.* 1978;17:490-3.
- [26]. Gabrielli R, Rosati MS, Siani A & Marcucci G. Preoperative evaluation of retroperitoneal venous system anomalies during abdominal aortic aneurysm rupture. *Interactive Cardiovascular and Thoracic Surgery* 2011;12(2):278-80.
- [27]. Arslan H, Etlik O, Ceylan K, Temizoz O, Harman M, Kavan M. Incidence of retroaortic left renal vein and its relationship with varicocele. *Eur Radiol* 2005;15:1717-1720.
- [28]. Sinem Karazincir Ali Balci, , Sadik GörürHaldun Sumbas, Ahmet N. Kiper, Incidence of the Retroaortic Left Renal Vein in Patients With Varicocele. 2007 by the American Institute of Ultrasound in Medicine. *J Ultrasound Med* 2007;26:601-604.

How to cite this article:

Namburu Bhanu Sudha Parimala, Pitta Venkata Chandrika, Sangam Muralidhar Reddy. A STUDY OF ANOMALIES OF LEFT RENAL VEIN. *Int J Anat Res* 2015;3(3):1381-1386. DOI: 10.16965/ijar.2015.241