

STUDY ON COMMUNICATING BRANCHES OF SURAL NERVE: REVIEW OF LITERATURE AND ITS CLINICAL IMPLICATIONS

Sherry Sharma ^{*1}, Meenakshi Khullar ², Harpreet Singh Gulati ³, Sunil Bhardwaj ⁴.

^{*1} Associate Professor, Department of Anatomy, Punjab Institute of Medical Sciences, Jalandhar, Punjab, India.

² Assistant Professor, Department of Anatomy, Guru Gobind Singh Medical College, Faridkot, Punjab, India.

³ Assistant Professor, Department of Anatomy, Punjab Institute of Medical Sciences, Jalandhar, Punjab, India.

⁴ Medical Officer, PHC Thariawal, Block Majitha, Amritsar, Punjab, India.

ABSTRACT

Introduction: Variations of nerve are not only of anatomic and embryological interest but also of clinical importance. Their adequate knowledge will help in increasing surgical precision and decreasing morbidity.

Materials and Methods: In the present study the communicating branches of sural nerve were studied. The material for the present study comprised of 60 lower extremities belonging to 30 adult human cadavers obtained from Department of Anatomy, GMC, Amritsar, India. The sural nerve was identified and traced downward in the limb.

Result: In the present study these communicating branches arose either from lateral sural cutaneous nerve (branch of common peroneal nerve) or superficial peroneal nerve (intermediate dorsal cutaneous branch) or from tibial nerve itself.

Discussion: Sural nerve is usually used as grafting material. So these described variations are helpful for planning operative approaches that minimize risk of sural nerve injury. Moreover the anatomic course of nerve in distal leg and ankle makes it susceptible to local trauma and also to increased risk of injury during surgical intervention at ankle.

KEY WORDS: Sural nerve, Communicating branch, Grafting material, Nerve injury.

Address for Correspondence: Dr. Sherry Sharma, Associate Professor, Department of Anatomy, Punjab Institute of Medical Sciences, Jalandhar, Punjab, India. Phone No.: +919872830406

E-Mail: bhardwajsherry2@gmail.com

Access this Article online

Quick Response code



DOI: 10.16965/ijar.2015.260

Web site: International Journal of Anatomy and Research
ISSN 2321-4287
www.ijmhr.org/ijar.htm

Received: 04 Sep 2015

Accepted: 19 Sep 2015

Peer Review: 04 Sep 2015

Published (O): 30 Sep 2015

Revised: 15 Sep 2015

Published (P): 30 Sep 2015

INTRODUCTION

Sural nerve is a sensory nerve that originates in lower leg and provides sensory innervations to lateral and posterior part of inferior third of leg and lateral side of foot [1]. Classically the sural nerve comes from communication between

medial cutaneous nerve of leg which is branch of tibial nerve and perforating branch from lateral cutaneous nerve which is a branch of common peroneal nerve [2]. Sural nerve is a cutaneous nerve which begins as a branch of tibial nerve (medial sural nerve) and descends

between two heads of gastrocnemius muscle, under posterior fascia which perforates to receive communicating branch from lateral cutaneous nerve of leg at different levels. The sural nerve thus formed runs slightly obliquely downwards crossing lateral border of tendocalcaneus and passing behind and then below lateral malleolus and crosses dorso-lateral aspect of foot [3]. The anatomic course of nerve in distal leg and ankle makes it susceptible to local trauma and also increases the vulnerability to trauma during various surgical interventions [4]. Clinically, sural nerves are used widely for diagnostic purposes as in nerve conduction velocity studies and for biopsy. Since the sural nerve is the most frequently used sensory nerve in nerve transplantation, familiarity with variations in its course and distribution plays important role in these procedures [5]. The sural nerve when injured has tendency to form painful neuroma. The nerve is often used as autologous peripheral nerve graft on the grounds that it is easily harvested and identified [6].

MATERIALS AND METHODS

The material for the present study comprised of 60 lower extremities belonging to 30 adult human cadavers obtained from the Department of Anatomy, Government Medical College, Amritsar, Punjab India. Tibial nerve and its branches were exposed as per the dissection steps provided by Cunningham's Manual of Practical Anatomy [7]. Deep fascia from posterior surface of popliteal fossa was stripped off and fat from its upper angle was removed to expose tibial nerve and common peroneal nerve. Vertical midline incision from popliteal fossa was extended running along lateral edge of tendo calcaneus and ending in lateral infra malleolar region. From tibial nerve, medial sural cutaneous nerve was traced downwards; its communicating branch was identified and traced.

RESULTS AND OBSERVATIONS

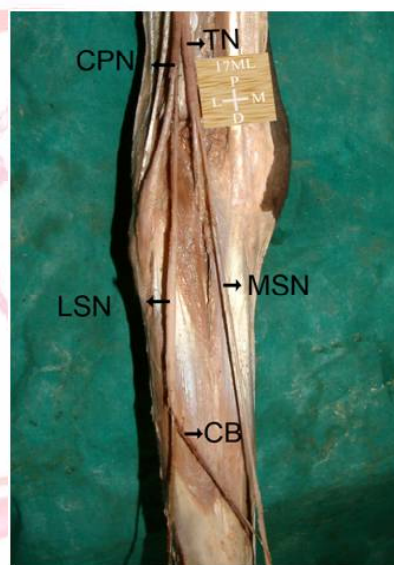
Normally there are two communicating branches. In present study, communicating branch of sural nerve is found in all the limbs.

These communicating branches arose either from lateral sural cutaneous nerve (branch of common peroneal nerve) or superficial peroneal

nerve (intermediate dorsal cutaneous branch) or from tibial nerve itself.

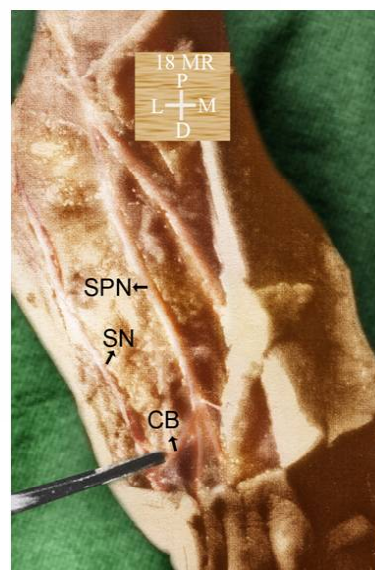
In the present study, in 38 (63.33%) limbs (20 on right and 18 on left) communication existed between medial sural nerve (branch of tibial nerve) and lateral sural nerve (branch of common peroneal nerve) (Fig. 1). Communicating branch arose from Lateral sural nerve mostly in the middle of leg and traversed obliquely from lateral to medial side and very rarely horizontally. The thickness of this branch is comparable with medial sural nerve with lateral sural nerve being thickest.

Fig. 1: Communicating branch between Lateral and Medial Sural Nerve.



LSN- Lateral Sural Nerve, MSN- Medial Sural Nerve
CB- Communicating Branch

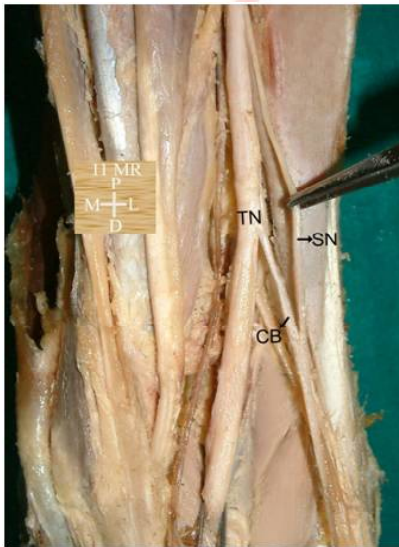
Fig. 2: Communicating branch between Superficial peroneal nerve and Peroneal nerve.



SN- Sural Nerve SPN- Superficial Peroneal Nerve
CB- Communicating Branch

In 18 (30%) limbs (10 on right and 8 on left) communication existed between sural and superficial peroneal nerve (Fig. 2). Communicating branch arose from Superficial peroneal nerve turning laterally to join Sural nerve about 2cm proximal to the 4th and 5th digits. The thickness of this branch is comparable with Sural nerve with Superficial peroneal nerve being the thickest.

Fig. 3: Communicating branch between Tibial nerve and Sural nerve



TN- Tibial Nerve, SN-Sural Nerve
CB- Communicating Branch

In 12 (20%) limbs (5 on right and 7 on left) communication existed between sural nerve and tibial nerve (Fig. 3). Short communicating branch arose obliquely from Tibial nerve crossing laterally to join Sural nerve. The thickness of this branch is approximately equal to that of sural nerve.

In 8 limbs (13.33%), 2 communicating branches were present. These communications existed between lateral and medial sural nerve and between superficial peroneal nerve and sural nerve and very rarely between Tibial nerve and Sural nerve.

DISCUSSION

Based on the earlier; fallowing observations done by the various authors, among them few studies related to the present study.

Drizenko et al. (2004) found communicating branch between superficial peroneal nerve and sural nerve in 60% of limbs (33 out of 55 dissections). 35 communicating branches were

found as 2 cadavers had 2 communicating branches [8].

Bonnel F, et al. (1992) stated that principal constant communicating branch lay in region of inferio lateral angle of extensor retinaculum [9].

Kosinski C. (1926) found distal communicating branches lying in metatarsal region between superficial peroneal (intermediate dorsal cutaneous nerve) and sural nerve (lateral dorsal cutaneous nerve) in 59.8% of limbs [10].

Eastwood DM et al. (1992) found 5 out of 20 limbs of sural nerve anastomosing with branches of superficial peroneal nerve [11].

Blair JM and Botte MJ. (1994) found only occasional small communicating branches between cutaneous branch of intermediate and lateral dorsal nerve in 25 dissections [12].

Heune DB, Bunnell WP. (1995) noted crossover, at lateral malleolus, of sensory branches from superficial peroneal and sural nerve but did not mention any communicating branch [13].

Sekiya S, Kumaki K. (2002) Investigated occurrence of a communication between sural and tibial nerve in 49 limbs of 28 Japanese cadavers and found communication in 7(14.3%) limbs of 5 (18.9%) cadavers [14].

In the present study, the relative percentages of different communicating branches are in comparison to the earlier studies. Communicating branches of considerable thickness were present in all the cases with majority between Lateral and Medial sural nerve. The communicating branches arising from Tibial nerve carry motor fibres to join Sural nerve which is predominantly a sensory nerve. Thus we hold the changing concept true that Sural nerve is not purely a sensory nerve.

Table 1: Comparison of communicating branches between sural and superficial peroneal nerve.

Author	Year	No. of limbs studied	No. of limbs with communicating branches between sural and superficial peroneal nerve [n (%)]
Kosinki C et al. [10]	1926	-	59.80%
Eastwood DM et al. [11]	1992	20	05(25.00%)
Drizenko A et al. [8]	2004	55	33(60.00%)
Present Study	2008	60	18(30.00%)

CONCLUSION AND CLINICAL IMPLICATIONS:

Rich sensory innervation of ankle and foot is manifested through numerous communicating branches linking the neural trunks, particularly the sural nerve and superficial peroneal nerve on anterolateral aspect of hind foot. Stretching of proximal communicating branch during forced inversion of ankle and / or foot or during fracture of calcaneus or direct injury in surgical approaches or arthroscopy of ankle may lead to unexplained pre and submalleolar pain. Advances in modern imaging techniques may allow recognition of these branches which can be proximal or distal, straight or curved and provide guidance for infiltration and even neurolysis [8]. In addition a direct blow, arthroscopy of ankle and surgical approach to lateral aspect of ankle and hind foot could directly injure the communicating branch.

The peripheral nerve entrapment syndromes in foot include those symptom complexes that are primarily neurologic in origin and result from embarrassment to any of peripheral nerve trunk or branches of foot [15]. The knowledge of anatomic variations also helps to explain discrepancies between the clinical examinations and electrophysiological tests as to the location of neuronal lesions [16].

In most of the cases, communicating nerve was of larger caliber than that of sural nerve. In a situation requiring limited length of nerve graft material, the communication nerve alone can be harvested and sural nerve can be spared. The concept that sural nerve is purely sensory is changing. Many worked on this and showed that nerve does contain motor fibers. It is recommended to screen the nerve electrophysiologically for motor fibers before nerve biopsy for interpretation of pathologic finding [17].

Forfeiting the sural nerve grafts may cause chronic pain and paraesthesia, some superficial peroneal nerve territories could also be affected because being supplied by sural nerve. In such circumstances lateral sural cutaneous nerve is best choice for nerve grafting to minimize the clinical problem [18].

One might hope that progress in modern imaging and particularly magnetic resonance imaging

(MRI) will allow visualization of anatomic variations which facilitate chronic irritation of nerves of foot and allowing their identification for infiltration or surgical release after failure of conservative treatment [8].

Conflicts of Interests: None

REFERENCES

- [1]. Mahakkanukraun P, Chomsung R. Anatomical variation of sural nerve. *Clin Anat* 2000; 15:263-266.
- [2]. Mestdagh H, Drizenko A, Maynou C, Demondion X, Monier R. Origin and make up of the human sural nerve. *Surg Radiol Anat* 2001;23:307-312.
- [3]. Bryan BM, Lutz GE, O'Brien SJ. Sural nerve entrapment after injury to gastrocnemius: a case report. *Arch Phys Med Rehabil* 1999;80:604-606.
- [4]. Stickler DE, Morley KN, Massey EW. Sural neuropathy: etiologies and predisposing factor. *Muscle Nerve* 2006;34:482-484.
- [5]. Nayak SB. Sural nerve and short saphenous vein entrapment – a case report. *Ind J Plast Surg* 2005;38(2):171-172.
- [6]. Williams PL, Bannister LH, Berry MM, Collins P, Dyson M, Dussek LE et al. The Leg. Berry MM, Mstrandring S, Bannister LH. In: *Gray's Anatomy*. 40th Edition. Edinburgh, London: Churchill Livingstone; 2008;1427.
- [7]. Romans GJ. The popliteal fossa, back of thigh, leg and foot. In: *Cunningham's Manual of Practical Anatomy*. 15th Edition. Edinburgh, London: Book Society and Oxygen University Press; 1986;(3):160-214.
- [8]. Drizenko A, Demondion X, Luyckx F, Mestdagh H, Cassagnaud X. The communicating branches between the sural and superficial peroneal nerve in the foot: a review of 55 cases. *Surg Radiol Anat* 2004;26(6):447-452.
- [9]. Bonnel F, Janot TAP, Briand D, Claustre JE, Faure P. Lenerf fibulaire superficial au pied. *Med Chir Pied* 1992; 8: 95-100. Cited by Drizenko A, Demondion X, Luyckx F, Mestdagh H, Cassagnaud X. The communicating branches between the sural and superficial peroneal nerve in the foot: a review of 55 cases. *Surg Radiol Anat* 2004; 26(6): 447-452.
- [10]. Kosinski C. The course, mutual relations and distribution of cutaneous nerves of metazonal region of leg and foot. *J Anat* 1926; 60: 274-297 Cited by Drizenko A, Demondion X, Luyckx F, Mestdagh H, Cassagnaud X. The communicating branches between the sural and superficial peroneal nerve in the foot: a review of 55 cases. *Surg Radiol Anat* 2004;26(6):447-452.
- [11]. Eastwood DM, Irgau I, Atkins RM. The distal course of the sural nerve and its significance for incision around the lateral hind foot. *Foot Ankle* 1992; 13: 199-202.

- [12].Blair JM and Botte MJ. Surgical anatomy of superficial peroneal nerve in the ankle and foot. Clin Orthop 1994;305:229-238.
- [13]. Heune DB, Bunnell WP. Operative anatomy of nerves encountered in lateral approach to distal part of fibula. J Bone Joint Surg (Am) 1995;77:1021-1024.
- [14]. Sekiya S, Kumaki K. Sural - tibial nerve communications in humans. Anat Sci Int 2002; 77: 140.
- [15]. Tsai CC, Lin TM, Lai CS, Lin SD. Tarsal tunnel syndrome secondary to neurilemmoma – a case report. Kaohsiung J Med Sci 2001;17(4):216-220.
- [16].Davis TJ, Schon LC. Branches of tibial nerve: anatomic variation. Foot Ankle Int 1995; 16(1):21-29.
- [17]. S R Seema. Study of sural nerve complex in human cadaver. ISRN Anatomy; 2013 article ID 827276:127.
- [18]. Devi SK, Sharmila BP, Susan PJ, Gajendra K. Variant formation of sural nerve and its distribution at the dorsum of the foot. International journal of anatomical variations 2009;1:33-34.

How to cite this article:

Sherry Sharma, Meenakshi Khullar, Harpreet Singh Gulati, Sunil Bhardwaj. STUDY ON COMMUNICATING BRANCHES OF SURAL NERVE: REVIEW OF LITERATURE AND ITS CLINICAL IMPLICATIONS. Int J Anat Res 2015;3(3):1436-1440.

DOI: 10.16965/ijar.2015.260