

## Case Report

# BILATERAL VARIATIONS IN BRANCHING OF AXILLARY ARTERY

**Bikash Chandra Satapathy <sup>\*1</sup>, Abu Ubaida Siddiqui <sup>2</sup>, Soumitra Trivedi <sup>2</sup>, Dhanesh Kumar Sharma <sup>3</sup>.**

<sup>1</sup> Senior Resident, <sup>2</sup>Assistant Professor, <sup>3</sup>Additional Professor

Department of Anatomy, All India Institute of Medical Sciences, Raipur, India.

## ABSTRACT

Bilateral variations in the branching pattern of axillary artery were seen in a 78 year male cadaver during routine dissection. On the right side superior thoracic artery was a branch of second part of axillary artery. Additional pectoral branches were seen coming out of the second part on either side. Bilaterally from the second part a common trunk originated which gave rise to lateral thoracic and subscapular artery. On the left side an additional pectoral branch from the common trunk was present. From the third part on either side a muscular branch supplied the coracobrachialis muscle. On the right side from the third part of axillary artery a common trunk started and divided into anterior and posterior circumflex humeral arteries.

**KEY WORDS:** Axillary artery, Common trunk, Coracobrachialis, Clinical significance.

**Address for Correspondence:** Dr Bikash Chandra Satapathy, Department of Anatomy, All India Institute of Medical Sciences, Raipur-492099, India. **E-Mail:** [bikash.satapathy@gmail.com](mailto:bikash.satapathy@gmail.com)

## Access this Article online

### Quick Response code



DOI: 10.16965/ijar.2015.294

**Web site:** International Journal of Anatomy and Research  
ISSN 2321-4287  
[www.ijmhr.org/ijar.htm](http://www.ijmhr.org/ijar.htm)

Received: 09 Oct 2015      Accepted: 04 Nov 2015  
Peer Review: 09 Oct 2015      Published (O): 30 Nov 2015  
Revised: None      Published (P): 31 Dec 2015

## INTRODUCTION

Axillary artery (AA) is the continuation of subclavian artery and extends from outer border of first rib to lower border of subscapularis muscle. It is divided into three parts by pectoralis minor (PM) muscle. The first part is between outer border of first rib and medial border of pectoralis minor muscle. Superior thoracic or supreme thoracic artery (STA) is the only branch from the first part of axillary artery. The second part of axillary artery is deep to the pectoralis minor muscle and commonly gives rise to thoracoacromial artery (TAA) and lateral thoracic artery (LTA). The third part of axillary artery extends from the lateral border of pectoralis minor to lower border of subscapularis muscle. Normally there are three branches from the third part of axillary artery, which are anterior circumflex humeral artery (ACHA), posterior

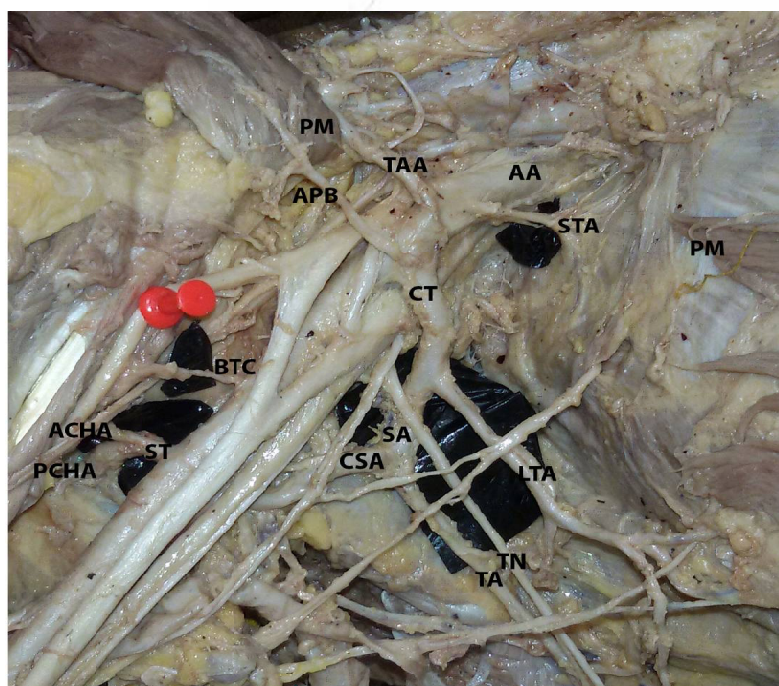
circumflex humeral artery (PCHA) and subscapular artery (SA) [1]. Axillary artery is known to have variations from the above description [2].

## CASE REPORT

During routine dissection for undergraduate classes in AIIMS, Raipur, we found a 78 year old male cadaver with the superior thoracic artery on right side taking origin from second part of axillary artery. On either side near the origin of thoracoacromial artery there was another artery, an additional pectoral branch (APB), directly from the third part of axillary artery supplying pectoralis minor muscle. Bilaterally there was a common trunk (CT) from the second part of axillary artery that divided into lateral thoracic artery and subscapular artery. On the left side the common trunk gave rise to an artery for thoracic wall, a pectoral branch (PB) before giving rise to lateral thoracic artery. On both

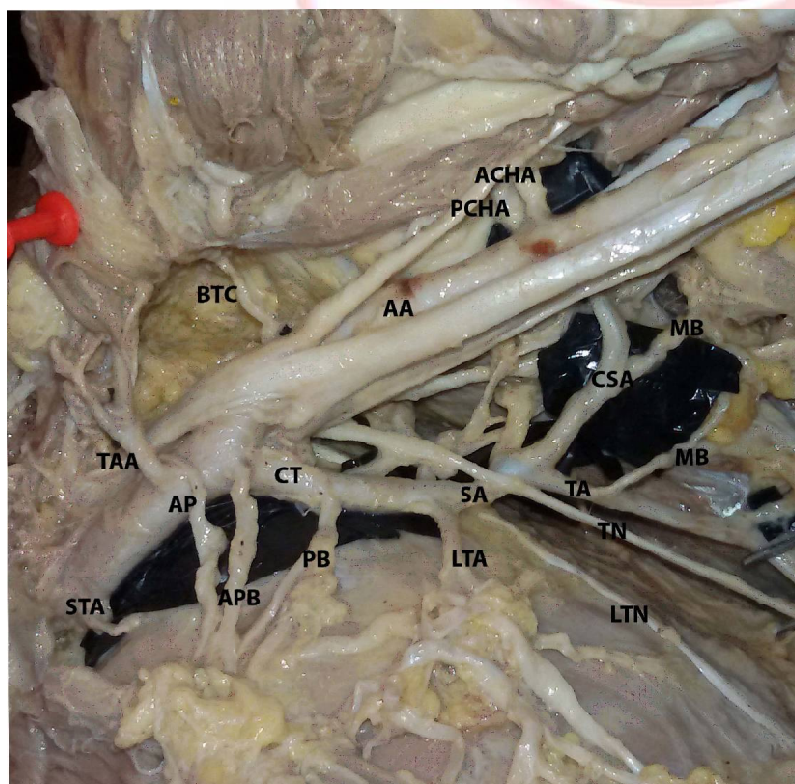
sides the common trunk after giving rise to lateral thoracic artery continued as subscapular artery and divided into a bigger branch called circumflex scapular artery (CSA) and continued as a smaller thoracodorsal artery (TA) that accompanied the thoracodorsal nerve (TN). On either side there was a branch from the third part of axillary artery supplying coracobrachialis muscle (BTC=branch to coracobrachialis). On right side both ACHA and PCHA started as a single trunk (ST) from the third part of axillary artery and then got divided. All other branches of axillary artery were normal.

**Fig. 1:** Variations in branching of axillary artery (Right Side).



PM=Pectoralis Minor,  
AA=Axillary Artery,  
STA=Superior Thoracic Artery,  
TAA=Thoracoacromial Artery,  
APB= Additional Pectoral Branch,  
CT=Common Trunk,  
LTA=Lateral Thoracic Artery,  
SA=Subscapular Artery,  
CSA=Circumflex Scapular Artery,  
TA=Thoracodorsal Artery,  
TN=Thoracodorsal Nerve,  
BTC=Branch to Coracobrachialis,  
ST=Single Trunk,  
ACHA=Anterior Circumflex Humeral Artery,  
PCHA=Posterior Circumflex Humeral Artery

**Fig. 2:** Variations in branching of axillary artery (Left Side).



STA=Superior Thoracic Artery,  
TAA=Thoracoacromial Artery,  
AP=Ansa Pectoralis,  
APB=Additional Pectoral Branch,  
CT=Common Trunk,  
PB=Pectoral Branch,  
LTA=Lateral Thoracic Artery,  
SA=Subscapular Artery,  
CSA=Circumflex Scapular Artery,  
TA=Thoracodorsal Artery,  
TN=Thoracodorsal Nerve,  
LTN=Long Thoracic Nerve,  
MB=Muscular Branch  
BTC=Branch to Coracobrachialis,  
AA=Axillary Artery,  
ACHA=Anterior Circumflex Humeral Artery,  
PCHA=Posterior Circumflex Humeral Artery



## DISCUSSION

Branching pattern of axillary is quite variable and well documented. Samta et al [3] reported the incidence to be as high as 28%. Verma et al [4] reported a case in which the left superior thoracic artery was taking origin from the second part of axillary artery. In the present case similar variation was seen on the right side.

Incidence of subscapular artery taking origin from second part of axillary artery has been documented to vary from 4% by Samta et al [3] to 15% by Huelke [5]. Swamy et al [6] described a variant subscapular artery taking origin from second part of axillary artery and giving rise to posterior circumflex humeral and lateral thoracic artery. Vasuki et al [7] encountered variations in the third part of axillary artery on the right side. In the present case a common trunk took origin from second part of axillary artery and then gave rise to lateral thoracic artery and circumflex scapular artery on both sides. The circumflex humeral arteries took origin from the third part of axillary artery, but on left side anterior and posterior circumflex humeral arteries were separate branches, whereas on the right side they took origin as a common trunk and then divided into ACHA and PCHA.

Chitra and Anandhi [8] reported absence of thoracoacromial trunk and presence of individual branches from the second part such as deltoid, pectoral, acromial and clavicular on the right side. In the current case extra pectoral branches were there. On left side there were two extra pectoral branches, one additional pectoral branch (APB) from second part of axillary artery and one pectoral branch (PB) from the common trunk from second part of axillary artery. On the right side the additional pectoral branch originated directly from second part of axillary artery.

Arey LB [9] gave some possible explanation for the unusual blood vessels. Among which one was "obliteration of normally retained blood vessel", which could explain absence of the subscapular artery directly from axillary artery on either side. The author also suggested that incomplete fusion and absorption of usually distinct parts could also lead to unusual blood vessels. This process might have led to fusion

of subscapular artery with the lateral thoracic artery to form the common trunk. The separate pectoral branches might have resulted due to their incomplete fusion with thoracoacromial artery. The superior thoracic artery on right side was taking origin from the second part of axillary artery. This could be explained by incomplete fusion and absorption of vessels.

According to Hamilton and Mossman [10] arterial variations found in the upper limb are because of defect in the limb bud's vascular plexus. These variations could have been possible due to retention, regression or reappearance of branches after arrest of normal vascular development.

## CONCLUSION

In performing antegrade cerebral perfusion in aortic surgery for axillary artery thrombosis variant anatomy of axillary artery is crucial. Knowledge of branching pattern of axillary artery is essential for reconstructing axillary artery after trauma, giving regional nerve block in the axillary region. In performing surgeries in upper end of humerus and axillary dissection during mastectomy for carcinoma breast and for utilising medial arm skin flap, knowledge of different variations in branching of axillary artery is very valuable. So knowing the variations in branching of axillary artery is beneficial for anaesthetists, surgeons, orthopedicians as well as interventional radiologists.

**Conflicts of Interests: None**

## REFERENCES

- [1]. Susan Standring, editor. Gray's Anatomy: The Anatomical Basis of Clinical Practice. 40th ed. London: Churchill Livingstone Elsevier; 2008. p. 817.
- [2]. Hollinshead WH. Anatomy for Surgeons in General surgery of the upper limb. The back and Limbs. Volume 3. New York: Heber- Harper Book; 1958. 290-300 p.
- [3]. Samta gaur, S K.Katariya, H Vaishnani, I N Wani, K V Bondre GVS. A cadaveric study of branching pattern of the axillary artery. Int J Biol Med Res. 2012 Feb 1;3(1):1388-91.
- [4]. Verma R, Mishra S, Mahajan A. Unilateral variation in the branching pattern of axillary artery: a cadaveric study. Int J Anat Res. 2014;2(1):292-4.
- [5]. Huelke DF. Variation in the origins of the branches of the axillary artery. Anat Rec. 1959 Sep;135(1):33-41.

- [6]. Swamy R, Rao M, Kumar N, Sirasanagandla S, Nelluri V. Unusual branching pattern of axillary artery associated with the high origin of ulnar artery. *Ann Med Health Sci Res*. 2013 Apr;3(2):265–7.
- [7]. A.K.Manicka Vasuki, M.Nirmala Devi, K.Kalyana Sundaram, Deborah Joy Hezbibah, T.K.Aleyemma Fenn, M.Jamuna. UNILATERAL VARIATION IN THE BRANCHING PATTERN OF RIGHT AXILLARY ARTERY: A CASE REPORT. *Int J Anat Res* 2015;3(3):1312-1315. DOI: 10.16965/ijar.2015.218.
- [8]. Chitra PS, Anandhi V. A unique variation in branching pattern of axillary artery. *Int J Anat Var*. 2013;6:1–3.
- [9]. Arey LB. *Developmental Anatomy*. 6th ed. Philadelphia: W B Saunders Company; 1957. 375-377 p.
- [10]. Hamilton WJ, Mossman HW. *Cardiovascular system. Human Embryology*. 4th ed. Baltimore: Williams and Wilkins; 1972. p. 271–90.

#### How to cite this article:

Bikash Chandra Satapathy, Abu Ubaida Siddiqui, Soumitra Trivedi, Dhanesh Kumar Sharma. BILATERAL VARIATIONS IN BRANCHING OF AXILLARY ARTERY. *Int J Anat Res* 2015;3(4):1593-1596. DOI: 10.16965/ijar.2015.294