

## MORPHOMETRIC STUDY OF THE SUPRACONDYLAR PROCESS OF THE HUMERUS WITH ITS CLINICAL UTILITY

Roopali D. Nikumbh <sup>\*1</sup>, Dhiraj B. Nikumbh <sup>2</sup>, Megha A. Doshi <sup>3</sup>, Manohar N Ugadhe <sup>4</sup>.

<sup>\*1</sup> Assistant Professor, Department of Anatomy, JMF's ACPM Medical College, Dhule, Maharashtra, India.

<sup>2</sup> Associate Professor, Department of Pathology, JMF's ACPM Medical College, Dhule, Maharashtra, India.

<sup>3</sup> Professor & Head, Department of Anatomy, KIMS University, Karad, Maharashtra, India.

<sup>4</sup> Professor, Department of Anatomy, JMF's ACPM Medical College, Dhule, Maharashtra, India.

### ABSTRACT

**Background:** The Supracondylar process is a beak like bony spine/ projection that arises from the anteromedial surface of the Humerus. It is also called Supraepitrochlear, epicondylar, epicondylic process or Supracondylar spur. It represents a phylogenetic remnants of complete osseous bride found in climbing animals and many reptiles mostly marsupials, cats, lemurs and American monkeys.

**Materials and Methods:** The two hundred and eighty dried humeri were studied in the Dept of Anatomy, KIMSUDU, Karad and ACPM Medical College, Dhule, India. The bones were examined for any osseous projection from distal part under day light. On findings, the dimensions were recorded and photographed.

**Results:** Out of 280 dried humeri examined, we found only 1 humerus of the right side with an osseous spine on the anteromedial surface. The incidence calculated in this study was 0.36%.

**Conclusion:** The Supracondylar process is usually clinically silent but may become symptomatic by presenting as a mass or can be associated with symptoms of median nerve compression and claudication of brachial artery especially when associated with Struthers ligament. Hence the knowledge of the presence of variations in anatomy like Supracondylar process is important for anatomists, radiologists, anesthesiologists, surgeons, and anthropologists.

**KEYWORDS:** Humerus, Supracondylar process, Struther's ligament.

**Address for Correspondence:** Dr. Roopali D. Nikumbh. M.D. Assistant Professor, Department Of Anatomy, JMF'S ACPM Medical College, Dhule, Maharashtra, India. **E-Mail:** [drdnikumbh@gmail.com](mailto:drdnikumbh@gmail.com)

### Access this Article online

#### Quick Response code



DOI: 10.16965/ijar.2016.117

**Web site:** International Journal of Anatomy and Research  
ISSN 2321-4287  
[www.ijmhr.org/ijar.htm](http://www.ijmhr.org/ijar.htm)

Received: 22 Jan 2016      Accepted: 08 Feb 2016  
Peer Review: 23 Jan 2016    Published (O): 29 Feb 2016  
Revised: None                Published (P): 29 Feb 2016

### INTRODUCTION

The Supracondylar process (SCP) or Supracondylar spur is a hook-like bony spine of variable size from 2-20 mm in length and about 5cms proximal to the medial epicondyle projecting distally downwards and forwards with its pointed apex sometimes connected to the medial border just above the medial epicondyle by

fibrous band to which part of the proneter teres is attached [1]. This fibrous band is known as 'Ligament of Struthers', which represents the lower head or third head of coracobrachialis [2]. According to Kessel and Rang ,the ligament actually represents lower part of tendon of a vestigial muscle lattissimus condyloidies, which is found in climbing animals and extends from

lattissimus dorsi to medial epicondyle [3].

The median nerve and or brachial artery may become compressed causing clinical symptoms. Struthers [4], Solieri [5] and Aydinlioglu et al [6] have described causes of median nerve entrapment. SCP of humerus was first noted by Tiedemann in 1822 who described it as pathological exostosis [7]. The reported incidence of SCP varies from 0.1% to 2.7% in different races [8,9]. Till now few studies has been done on SCP in Indian population [8,10-12].

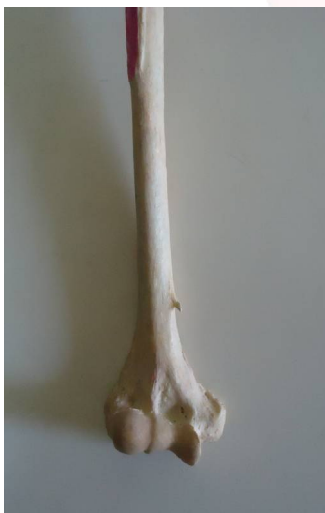The present study is carried out to study incidence of Supracondylar process of the humerus in Maharashtra territory and discuss its clinical utility.

### MATERIALS AND METHODS

The study was conducted on 280 dried humeri which were collected from Dept. of Anatomy, KIMSDU, Karad and ACPM Medical College, Dhule, Maharashtra, India. The bones were examined for any osseous process/spur from distal part under day light. On findings a Supracondylar process, the dimensions of the spur were recorded by Vernier caliper and photographs were taken.

### RESULTS AND OBSERVATIONS

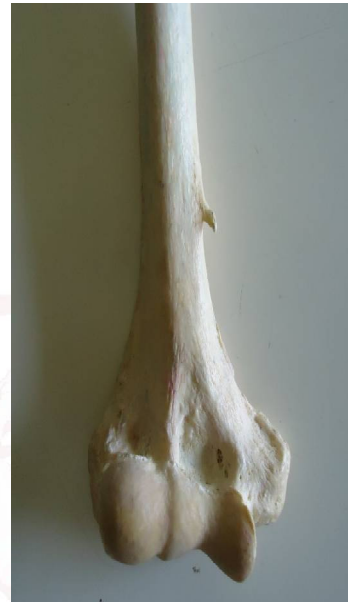**Fig. 1:** Photograph showing right humerus with Supracondylar process.



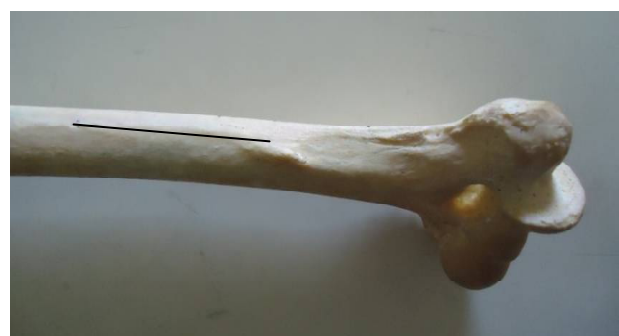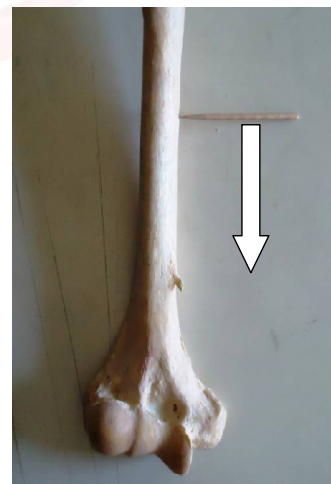
Out of 280 dried humeri examined, we found only 1 humerus of the right side with an osseous spine on the anteromedial surface (Fig. 1). It was 5.5.cms proximal to medial epicondyle (ME) was projecting 0.7 cms from the surface and 1.1 cm long vertically and 0.9 cms broad. The spine was directed oblique, forward and downwards

(Fig. 2).The distance between tip of the spine to medial Supracondylar ridge was 1.2 cms. The distance of spine from nutrient foramina (NF) was 6.5 cms (Fig. 3 & 4).The total length from the lowest tip of the trochlea to the highest point of head of this humerus was 32.5 cms. The incidence calculated was 0.36%.

**Fig. 2:** Showing distal part of humerus with Supracondylar process.



**Fig. 3 & 4:** Photograph showing distance (arrow) between nutrient foramina (NF) and SCP.



**DISCUSSION**

Race estimation from skeletal data has been a central focus in anthropology. Also knowledge of variations in anatomy is important to anatomists, radiologists, anesthesiologists and surgeons in modern diagnostic medicine [10]. Morphological differences are the tools being used to find the missing links between the different stages of evolution. One of such variations is the ‘Supracondylar process’ [10]. The incidence of SCP of variations is very low and the percentage of incidence, as given by different author varies in Table 1 as per race [11].

**Table 1:** The Incidence of Supracondylar process reported in studies of different races.

Sl. No	Author	Incidence	Population/race
1	Gruber (1865)	2.70%	European race
2	Danforth (1924)	0.50%	Mixed (Review)
3	Adachi (1928)	0.80%	Mixed (Review)
4	Terry (1930)	1.16%	European race
5	Terry (1930)	0.10%	Negros
6	Hrdlijka (1923)	1%	American Indians
7	Dellon (1986)	1.15%	European race
8	Parkinson (1954)	0.40%	Mixed population
9	Natsis (2008)	1.30%	Caucasian s
10	Gupta (2008) [8]	0.26 %.	Indians(Gujrat)
11	Oluyemi (2007)	2.50%	Nigerians
12	Prabahita (2012) [10]	1.25%	Indians (Assam)
13	Present study	0.36%	Indians(Maharashtra)

The incidence of SCP is low in Indian population and very few studies have been done on SCP till now as known in Table 2 [12].

**Table 2:** Incidence and measurements of SCP in Indian population.

Author	No of humeri	Incidence %	Length (mm)	Breadth at the base (mm)	Distance from ME (mm)	Distance from NF (mm)
Gupta & Mehta 2008 [8]	380	0.26	3	11	65	-
Prabahita B et al 2012 [10]	80	1.24	11	15	44	65
Shivaleela C et al 2014 [11]	240	0.41	10	10	60	47
Ravi & Patil 2014 [12]	133	0.75	8	12	53	38
Present study	280	0.36	11	10	55	65

The dimensions of SCP process in our study are different from other studies done by Gupta RK [8], Prabahita B [10], and Ravi and Patil [12] and in concordance with Shivaleela C et al [11].

SCP is usually clinically silent, but may become symptomatic by presenting an a mass or can be associated with symptoms of median nerve compression and claudication of the brachial artery [13,14]. There is high incidence of unilateral SCP of humerus in ‘Cornelia de Lange Syndrome’ an autosomal recessive trait, occurring in approximately one in every 10,000 live births [15].

The SCP ends in a roughened point at which a dense fibrous band (Ligament of Struthers) continues to the medial epicondyle [16]. From embryonic point of view, the Struthers ligament lies between the tendon of lattissimus dorsi and the coracobrachialis and corresponds to the lower end of the tendon of the vestigial lattissimo-condyloideus, a muscle found in climbing animals which extends from the tendon of insertion of the lattissimus dorsi muscle to the median epicondyle [17]. Rarely, this fibrous band may ossify forming a Supracondylar foramina, a tunnel which transmits the median nerve and brachial artery and sometimes variant ulnar artery [18] or ulnar nerve [19]. In lower mammals, this tunnel serves to protect the nerves and vessels going in the forearm [19]. In humans, the presence of SCP and Struthers ligament is usually asymptomatic, but also an important entrapment site for median nerve and brachial artery; known as Supracondylar process syndrome, which can be treated by surgical removal of the process and ligament [20]. The compression symptoms include severe parasthesia, hyperesthesia of the hand and fingers, ischemic pain of the forearm, embolization of distal arm arteries and disappearance of radial/ulnar pulse on full extension and supination of the forearm [17,19]. The diagnosis of the SCP and evaluation of amount of compression of neuromuscular bundle can be made by EMG, Doppler evaluation together with physical examination [17,19].

The SCP should be differentiated from Osteochondroma pathologically.SCP is oriented distally, towards the elbow with no discontinuity in cortex of humerus. An Osteochondroma point away from the joint [11]. X-ray of SCP shows an intact underlying humeral cortex, whereas in an osteochondroma, the cortex of tumor is continuous with the humeral cortex.

Heterotopic bone such as myositis ossificans may also mimic a Supracondylar process [11]. Rarely fracture of the SCP following trauma may cause median nerve compression syndrome as reported by Newman [21]. Treatment consist of excision of the SCP and the associated ligament of Struthers. The spur has been reported to recur and therefore it is recommended that the spur be removed together with the overlying periostium [9,22].

## CONCLUSION

The Supracondylar process is frequently misjudged as a pathological tumors as Osteochondroma rather than as a normal anatomical variation. Though the SCP is a very rare vestigial structure in humans, yet it is known to have racial variations. It is usually clinically silent, however may become symptomatic by presenting a mass or symptoms of the median nerve compression and claudication of brachial artery. Along with the anatomists and anthropologists, the SCP is equally important for clinicians as it may be overlooked and there may be misdiagnosis. Hence variations as SCP should be known to anatomists, radiologists, surgeons and anthropologists to avoid misdiagnosis.

**Conflicts of Interests: None**

## REFERENCES

- [1]. In: Williams PL, Warwick R, Dyson M, Bannister LH, editors. Gray' Anatomy. 39<sup>th</sup> ed. Edinburgh London: Churchill Livingstone; 2005. p. 850.
- [2]. Datta AK. Essentials of human Anatomy. In: Superior and inferior extremity. 3<sup>rd</sup> ed. Kolkatta: Current Books International; 2004. p. 60
- [3]. Kessel L, Rang M. Supracodylar spur of the humerus. J Bone Joint Surg Br 1966;48:765-769.
- [4]. Struthers J on the processus supracondyloideus humeri of man. Trans Int Med Congr. London; 1881;1:148-51
- [5]. Solieri S.: Nervalgia del nervo mediano da processo sopraepitrocleare. Chirurgia dcgli Organi di Movimento 1929; 14, 71.
- [6]. Aydinlioglu A, Cirak B, Akpinar F, Tosun N, Dogan A. Bi lateral Median Nerve Compression At The Level Of Struthers' Ligament. J. Neurosurg. 2000; Vol 92: 693-96.
- [7]. Tiedmann F. Tabulae arterium corporis humani. Carlsruhae: Muller; 1822.
- [8]. Gupta RK, Mehta CD. A study of the incidence of supracondylar process of the humerus. J Anat Soc India 2008;57:111-115.
- [9]. Spinner R.J., Lins, R.E., Jacobson, S.R. and J.A. Nunley. Fractures of the supracondylar process of the humerus. The Journal of Hand Surgery (Am) 1994; 19(6):1038-41.
- [10]. Prabahita B, Pradipta RC, Talukdar KL. A study of supracondylar process of humerus. Journal of Evolution of Medical and Dental Sciences. 2012;1(5):822
- [11]. Shivaleela C, Suresh BS, Kumar GV, Lakshmiprabha S. Morphological study of Supracondylar process of the humerus and its clinical implications. JCDR.2014;8(1):1-3
- [12]. Ravi V and Patil SP. Study of Supracondylar process of humerus. International Jr of Health & Allied Sciences2014;3(2):134-136.
- [13]. Oluyemi KA, Okwuonu UC, Adesanya OA, Akinola OB, Ofusori DA, Ukwenya VO and Odion BI. Supracondylar and infratubercular processes observed in the humeri of Nigerians. African Journal of Biotechnology. 2007 Novemver 5; Vol. 6 (21), pp. 2439-41.
- [14]. Subasi M, Kesemenli C, Necmioqlu S, Kapukaya A, Demirtas M. Supracondylar process of the Humerus. Acta Orthop. Belg. 2002; 68 (1):72-75.
- [15]. Peters FLM. Radiologic manifestations of the Cornelia de Lange syndrome. Pediatr Radiol. 1975; 3:41-46.
- [16]. Parkinson C. The supracondylar process. Radiology. 1954; 62: 556-58
- [17]. Ivins G. K., Fulton M. O. Supracondylar process syndrome: A case report. J. Hand Surg., 1996, 21-A, 279-81
- [18]. Barnard LB, Mccoy SM. The supracondyloid process of the humerus, J Bone Joint Surg 1946; 28(4):845-50.
- [19]. Mittal RL, Gupta BR. Median and ulnar-nerve palsy: an unusual presentation of the supracondylar process. Report of a case, J Bone Joint Surg Am 1978; 60(4): 557-58.
- [20]. Pecina M, Boric I, Anticevic D. Intraoperatively Proven Anomalous Struthers' Ligament Diagnosed by MRI. Skeletal Radiol. 2002; 31(9): 532-35.
- [21]. Newman A. The supracondylar process and its fracture. Am J Roentgenol Radium Ther Nucl Med. 1969; 105: 844-49.
- [22]. Thompson JK, Edwards JD. Supracondylar process of the humerus causing brachial artery compression and digital embolization in a fast-pitch softball player. A case report. Vasc Endovascular Surg. 2005; 39(5):445-8.

**How to cite this article:** Roopali D. Nikumbh, Dhiraj B. Nikumbh, Megha A. Doshi, Manohar N Ugadhe. MORPHOMETRIC STUDY OF THE SUPRACONDYLAR PROCESS OF THE HUMERUS WITH ITS CLINICAL UTILITY. Int J Anat Res 2016;4(1):1941-1944. DOI: 10.16965/ijar.2016.117