

A STUDY OF THE DIFFERENT TYPES OF FORMATION OF THE MEDIAN NERVE

P. S. Chitra ^{*1}, V. Anandhi ².

^{*1} Associate Professor, KAPV Government Medical College, Tiruchirappalli, Tamilnadu, India.

² Associate Professor, KAPV Government Medical College, Tiruchirappalli, Tamilnadu, India.

ABSTRACT

Background: Normally, the median nerve is formed by the union of two roots; medial root and lateral root of median nerve arising from the medial cord and lateral cord of brachial plexus respectively. The knowledge about the formation of median nerve from a single cord, by more than two roots, and their relationship with the axillary artery has profound importance during upper limb surgeries and during axillary block procedures.

Materials and Method: The median nerve formation was studied during routine dissection for undergraduate students in 36 cadavers i.e. 72 upper limbs of formalin preserved cadavers, over a period of 6 years.

Results: In this study four anomalies were found in the formation of the median nerve in 5 upper limbs. In one limb the median nerve arose from the single fused medial and lateral cords of brachial plexus (1.38%). In both upper limbs of a cadaver, three roots were taking part in the formation of median nerve (2.7%); two roots from lateral cord and one from medial cord. In one upper limb the median nerve was formed by three roots and the third root was from musculocutaneous nerve (1.38%). The median nerve was formed by four roots in an upper limb; three of them were from lateral cord and one from medial cord of brachial plexus (1.38%).

Conclusion: From the study we find that the median nerve can be formed by two, three or four roots. It can also arise from a fused cord or get an additional contribution from the musculocutaneous nerve. Awareness of these different modes of formation would be an asset to the operating surgeons and anaesthetists to avoid catastrophes during their procedures.

KEY WORDS: Medial root, Lateral root, Median nerve formation, variations.

Address for Correspondence: Dr. P. S. Chitra. M.S. (Anatomy), Associate Professor of Anatomy, KAPV Government Medical College, Tiruchirappalli, Tamilnadu, India. Mobile No: +9183447 67640.
E-Mail: pschitraezhilko@gmail.com

Access this Article online

Quick Response code



DOI: 10.16965/ijar.2016.157

Web site: International Journal of Anatomy and Research
ISSN 2321-4287
www.ijmhr.org/ijar.htm

Received: 22 Feb 2016

Peer Review: 22 Feb 2016

Revised: None

Accepted: 10 Mar 2016

Published (O): 30 June 2016

Published (P): 30 June 2016

INTRODUCTION

The Median nerve is formed by the union of two roots, lateral and medial root coming from lateral and medial cord of brachial plexus [1]. Formation of the median nerve occurs around the third part of the axillary artery where the lateral and medial roots join in front of the artery. Anomalies of the median nerve have been desc-

-ribed by various authors. We undertook this study to find variations in the formation of median nerve in central Tamil Nadu. Familiarity with these anatomical variations is very important during repair of nerve injury and reconstructive surgeries.

MATERIALS AND METHODS

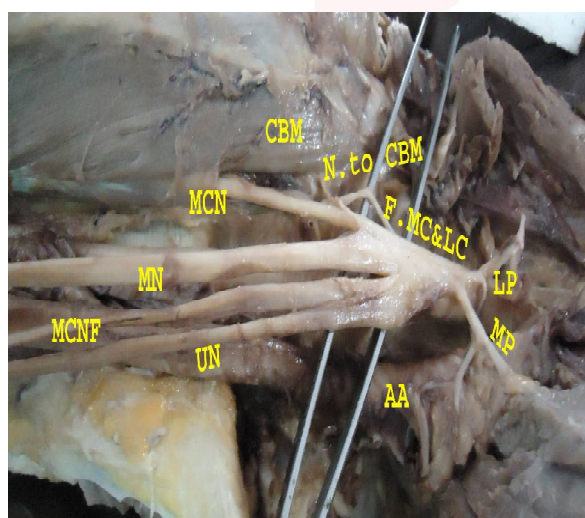
The specimens consisted of formalin fixed 72

limbs from 36 cadavers irrespective of sex and age used for routine dissection by undergraduate medical students. Conventional method of dissection was done and examined for anatomical variations in the median nerve formation and its relation to the axillary artery. In this study, four kinds of variations of median nerve were found in five upper limbs. (out of 72 upper limbs).

RESULTS AND FINDINGS

In the right upper limb of a male cadaver, the medial cord and the lateral cord were fused with each other. All the branches of the medial and lateral cord, including the median nerve arose from this fused cord (1.38%). The median nerve was medial to the axillary artery. The musculocutaneous nerve took its usual course by piercing the coracobrachialis muscle. (Fig.1)

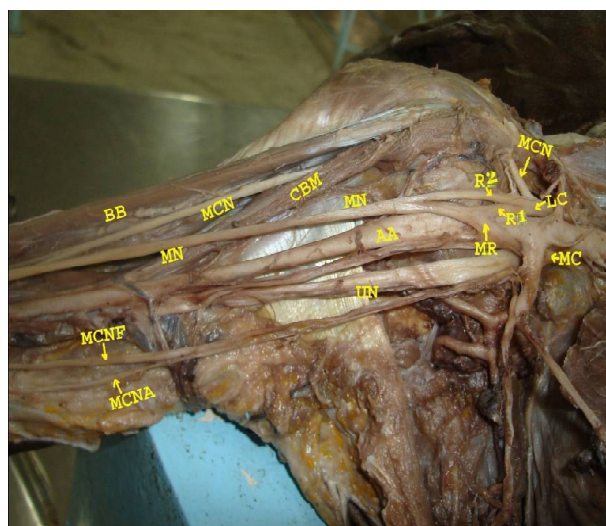
Fig. 1: Showing the formation of median nerve from fused medial and lateral cord.



F.MC & LC (Fused medial and lateral cord),
LP- Lateral pectoral nerve,
MP-Medial pectoral nerve,
CBM-coracobrachialis,
N.to CBM – branch to coracobrachialis,
MCN – musculocutaneous nerve,
MN- median nerve, **UN**-Ulnar nerve, **AA** – Axillary artery,
MCNF- medial cutaneous nerve of forearm.

In both upper limbs of a female cadaver, the median nerve was formed by three roots (2.7%). Two roots were from the lateral cord and one from medial cord of the brachial plexus. The first root from lateral cord (R1) joined with the medial root to form the median nerve in front of the axillary artery and the second root from the lateral cord joined the median nerve lateral to the third part of the axillary artery (Fig.2).

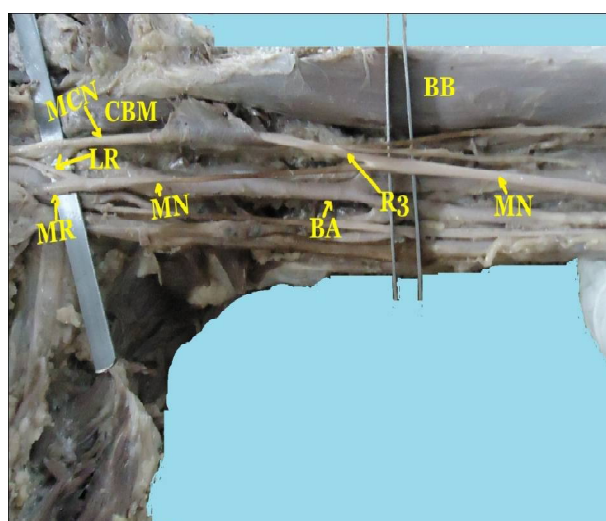
Fig. 2: Showing the formation of median nerve from three roots, two from lateral and one from medial cord.



MC-Medial cord, **LC**-Lateral cord, **R1**-Root 1, **R2** – Root 2;
MR-Medial root of median, **MN** – Median nerve;
AA – Axillary artery; **UN** – Ulnar nerve;
CBM – Coracobrachialis muscle;
MCN - Musculocutaneous nerve; **BB**-Biceps brachii;
MCNF- Medial cutaneous nerve of forearm;
MCNA- Medial cutaneous nerve of Arm

In the left limb of a male cadaver, the median nerve was formed by three roots; the usual two roots joined in front of the axillary artery, and a third root arose from the musculocutaneous nerve joined the median nerve lateral to the brachial artery at the mid-arm level. This type of anomaly was found in 1.38% of the upper limbs (Fig.3).

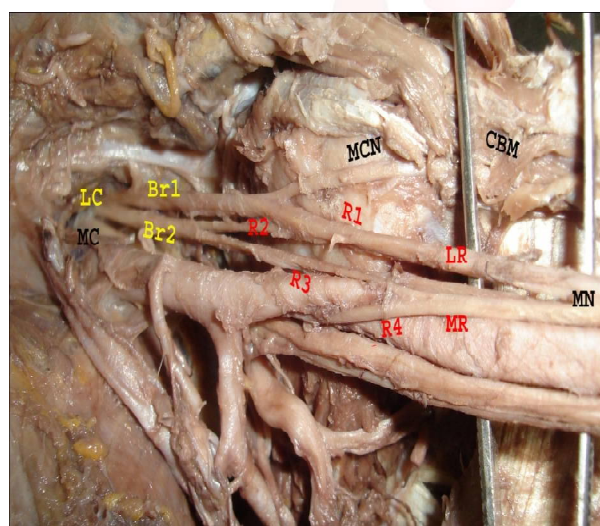
Fig. 3: Showing the formation of median nerve from three roots. third from musculocutaneous nerve.



MR-Medial root; **LR**- Lateral root;
MCN-Musculocutaneous nerve; **MN**- Median nerve;
CBM-Coracobrachialis muscle; **MN**-Median nerve;
AA – Axillary artery; **R3**-root 3; **MN**-Median nerve

In the left upper limb of a female cadaver, the median nerve was formed by four roots (1.38%); three from the lateral cord and one from medial cord of brachial plexus. In this anomaly, the lateral cord divided into 2 branches (Br1 & Br2). The musculocutaneous nerve and one root of median nerve (R1) arose from the lateral branch (Br1). The medial branch (Br2) again divided into two roots (R2 & R3). R3 joined with R4 of medial cord to form the medial root of median nerve in front of the axillary artery. The R1 joined with R2 to form the lateral root of median nerve. The lateral and medial roots united to form the median nerve lateral to axillary artery at the level of insertion of coracobrachialis (Fig.4).

Fig. 4: Showing the formation of median nerve from four roots.



MC-Medial cord; **LC**-Lateral cord; **Br.1**-Branch 1; **Br 2**-Branch 2; **R1**-Root 1, **R2** -Root 2; **R3**-Root 3; **R4**-Root 4; **LR**-Lateral root, **MR**-Medial root; **MN**-Median nerve; **MCN**-Musculocutaneous nerve; **CBM**-Coracobrachialis muscle.

DISCUSSION

Kerr (1918) [2] has reported the presence of two cords, Anterior and Posterior, where medial and lateral cords of classical brachial plexus united to form anterior cord which was lateral to axillary artery. Jamuna, Amudha (2010) [3] reported brachial plexus with two cords Anterior and Posterior in which both lateral and medial cord of brachial plexus unit to form a single anterior cord which was lateral to axillary artery. Shankar and Veeramani (2010) [4] reported a case of formation of a common cord replacing medial and lateral cords. In this present study, the median nerve was formed

from the fused medial and lateral cord which was lateral to axillary artery (1.38%).

Chauhan and Roy (2002) [5] reported that the median nerve was formed by three roots, two of them from lateral cord and third one from the medial cord. Saeed and Rufai (2003) [6] reported the formation of median nerve by two lateral roots and one medial root. Joshi et al (2008) [7] in their study of variations of lateral cord of brachial plexus, have described the formation of median nerve by two lateral and one medial root. According to their statement, the formation of median nerve was found to be occurring in two stages. In stage one, the first lateral root joined with the medial root. In the second stage, the second lateral root joined with the medial root. In this study the median nerve was formed by two lateral and one medial root (2.7%).

Ramachandran Kanakasabapathy and Holla (2006) [8] found three roots forming median nerve, but the third root was coming from musculocutaneous nerve. Budhiraja et al. (2011) [9] have described the formation of median nerve by three roots; the third root arose from the musculocutaneous nerve in 8.16% cases. In the present study the median nerve was formed by three roots, the third one from musculocutaneous nerve (1.38%).

Uzun and Seeling (2001) [10] described a case in which median nerve was formed by the fusion of four branches, three of them coming from the lateral cord and one from medial cord. Satyanarayana et al. (2008) [11] also reported that the median nerve was formed by four roots, three lateral and one medial root. In the present study the formation of median nerve by four roots was observed in one limb (1.38%).

Development and Innervation of Limbs:

These variations can be explained by observing the embryological stages in the development of the brachial plexus. The muscles of the upper limb develop from the mesenchyme of the paraxial mesoderm during the 5th week of the embryonic life [12]. The axon of spinal nerve grows distally to reach the limb bud mesenchyme. The peripheral process of the motor and sensory neurons grows in the mesenchyme in different directions. Once formed, any developmental differences would obviously persist.

postnatally [13]. As the guidance of the developing axons is regulated by expression of chemo-attractants and chemo-repellants in a coordinated site specific fashion, any alteration in signalling between mesenchymal cells and neuronal growth cones can lead to significant variations [14].

CONCLUSION

The insight into the variations in the formation, course and innervation is very essential for the anaesthetists and surgeons during axillary block, traumatic injuries of the upper limb and various surgical procedures in the axillary region. Recognition of the different types of formation of the median nerve would also be useful in interpreting diagnostic images during radiological procedures.

Conflicts of Interests: None

REFERENCES

- [1]. Susan Standring. Gray's Anatomy 40th edi. Churhill Livingstone, 2008; 781.
- [2]. Kerr AT. The brachial plexus of nerves in man, the variations in its formation and branches. Am J Anat 1918; 23:285-395.
- [3]. Jamuna M, Amudha G. Two cord stage in the infraclavicular part of brachial plexus. International Journal of Anatomical Variations 2010; 3:128-129.
- [4]. Shankar N, Veeramani. Replacement of medial and lateral cords of the brachial plexus by a common cord and its trifurcation into major brachial. International Journal Of Anatomical Variations. 2010;3:205-207.
- [5]. Chauhan R, Roy TS Communication between the median and musculocutaneous nerve- a case report. JASI 2002;52(1):72-75.
- [6]. Saeed M, Rafai AA. Median and Musculocutaneous nerves: Variant formation and distribution. Clinical Anatomy 2003;16:453-457.
- [7]. Joshi SD, Joshi SS, Athavale SA: Hitch –hiking fibers of the lateral cord of The brachial plexus in search of their destination. J Anat.Soc.India 2008;57:26-9.
- [8]. Ramachandran, K., Kanakasabapathy, I., and Holla, S.J. Multiple variations involving all the terminal branches of the Brachial plexus and the axillary artery. A case report. European Journal of Anatomy 2006 ; vol 10(3): 61-66.
- [9]. Budhiraja, V., Rastogi, R., and Asthana, AK. Anatomical Variations of median nerve formation: embryological and clinical correlation. J.Morphol.Sci. 2011;28(4):283-286.
- [10]. Uzun A, Seeling LL Jr A variation in the formation of median Nerve; communicating branch between the musculocutaneous and median nerves in man. Folia Morphol (warsz) 2001;80:99-101.
- [11]. Satyanarayana N, Guha R. Formation of median nerve by four Roots, J College of Medical sciences - Nepal 2008;5(1):105-7.
- [12]. Moore KL, Persaud TVN. The developing human: Clinically oriented embryology. 7th Ed., Philadelphia, W.B. Saunders Company. 2003;410,458.
- [13]. Brown MC, Hopkins WG., and Keynes, RJ. Essentials of neural development. In: Axon guidance and target recognition, Cambridge University Press. Cambridge 1991; pp 46-66.
- [13]. Sannes HD., Reh TA. and Harris, WA. Development of the nervous System In: Axon growth and guidance. Academic Press, New York, (2000); p. 189-197.

How to cite this article:

P. S. Chitra, V. Anandhi. A STUDY OF THE DIFFERENT TYPES OF FORMATION OF THE MEDIAN NERVE. Int J Anat Res 2016;4(2):2397-2400. DOI: 10.16965/ijar.2016.157