

# SUTURAL BONES ASSOCIATED WITH LAMBDOID SUTURE OF HUMAN SKULL: PRESENCE, VARIATIONS AND CLINICAL IMPORTANCE

A Arun Kumar <sup>\*1</sup>, B. Rajesh <sup>2</sup>, K. Arumugam <sup>3</sup>, V. Tamilalagan <sup>4</sup>.

<sup>\*1</sup> Department of Anatomy, Andaman & Nicobar Islands Institute of Medical Sciences, Port Blair, India.

<sup>2</sup> Department of Anatomy, Sri Lakshmi Narayana Institute of Medical Sciences, Puducherry.

<sup>3</sup> Department of Anatomy, Government medical college, Thirunelveli, India.

<sup>4</sup> Department of Anatomy, National Institute of Siddha, Chennai, India.

## ABSTRACT

**Background:** Sutural bones or Wormian bones are bony ossicles rarely present in between the bones of calvaria. These bones are also called as flower's bone or supernumerary bones usually found in the sagittal, coronal and lambdoid sutures but rarely present in fontanelle. They ossify from additional ossification centers which develop de novo in the calvarial mesenchyme. The frequency of these bones increases in various clinical conditions.

**Aim:** The purpose of this study is to analyze the frequency of sutural bones, their morphology, and position to discuss their clinical importance as well as forensic importance.

**Materials and Methods:** Two hundred and fifty human dry skulls are used for the study from the Department of Anatomy, Andaman & Nicobar Island Institute of Medical Sciences, Port Blair, Government medical college, Thirunelveli, Sri Lakshmi Narayana Institute of Medical Sciences, Puducherry and National Institute of Siddha, Chennai. The skulls are examined and the features of sutural bones are noted.

**Results:** Many numbers of sutural bones mimicking skull fractures are found in this study including presence of Inca Bones/Goethe's ossicles.

**Conclusions:** Our observations may be useful in interpreting the incidental findings of sutural bony ossicles during radiological procedures, surgical interventions of skull and also in autopsy procedure.

**KEY WORDS:** Lambda, Sutural bone, Inca bone, Goethe's ossicle.

**Address for Correspondence:** A Arun Kumar, Department of Anatomy, Andaman & Nicobar Islands Institute of Medical Sciences, DHS Annexe Building Near Rear Gate, G.B.Pant Hospital Atlanta Point, Port Blair 744104 India. **E-Mail:** [arivalaganarun@gmail.com](mailto:arivalaganarun@gmail.com)

## Access this Article online

### Quick Response code



DOI: 10.16965/ijar.2016.208

**Web site:** International Journal of Anatomy and Research  
ISSN 2321-4287  
[www.ijmhr.org/ijar.htm](http://www.ijmhr.org/ijar.htm)

Received: 19 Feb 2016

Peer Review: 08 Apr 2016

Revised: None

Accepted: 12 May 2016

Published (O): 31 May 2016

Published (P): 31 May 2016

## INTRODUCTION

Sutural bones or Wormian bones are the occasionally present small sized irregular bones

found in between the bones present in vault of the skull. These bones are also called as flower's bone/ supernumerary bones. During develop-

ment sutural bones are formed from separated part of bone forming centers in the neurocranium of the skull, or they are formed from an abnormal ossification center.

Hydrocephalic adult skulls show numerous occurrences of sutural bones [1]. These accessory bones are also named as "Wormian bones". They are clinically important markers for many syndromes and are useful in diagnosing osteogenesis imperfecta[2]. Wormian bones may also be seen in: Rickets, "Kinky-hair" Menke's syndrome, Otopalatodigital syndrome, Cleidocranial dysostosis, Pycnodysostosis, Hypoparathyroidism and hypophosphatasia, Primary acro-osteolysis, Down's syndrome [3].

They are also found in healthy individuals. The detached upper part of Occipital bone is called as "Inca Bone"[4]. Sometimes these bones are found at pterion (epipteric bone), at Bregma (OS Kerckring). They are commonly found in the skull of Incas and nowadays also seen in their Andean descendants [4].

A number of studies on the occurrence of these accessory bones among the many races were reported.[5,6,7] Studies focusing the variations of sutural bones present in lambdoid suture are very limited in South Indian Population. Hence, this study has been designed to determine the variations of sutural bones present in lambdoid suture by using a large number of sample size.

## MATERIALS AND METHODS

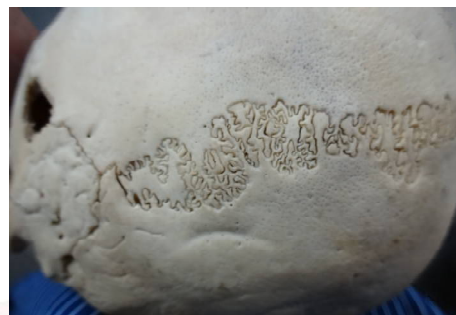Two hundred and fifty human dry skulls are used for the study; which were collected from the Department of Anatomy, Andaman & Nicobar Island Institute of Medical Sciences, Portblair, Sri Lakshmi Narayana Institute of Medical Sciences, Government medical college, Thirunelveli and National Institute of Siddha, Chennai. All the skulls were examined carefully for sutural bones. Presence, absence and variations in shape of the sutural bones are identified and data was collected.

## OBSERVATIONS


Many numbers of sutural bones mimicking skull fractures are noted. Inca Bones / Goethe's ossicles are observed. Out of the 250 skulls studied, 36 skulls were found to have wormian bones on the lambdoid suture, and 3 cases of inca bones are identified.

**Sutural Bones In Lambdoid Suture:** Sutural bones are identified in lambdoid suture. They appeared like leaves of ferns. The following pictures (Fig. 1 A to Fig. 1 E) showed some zigzag arrangements of sutural bones. These may be due to any of the above discussed reason. These patterns of sutural bones in radiographic view will confuse with multiple fractures.

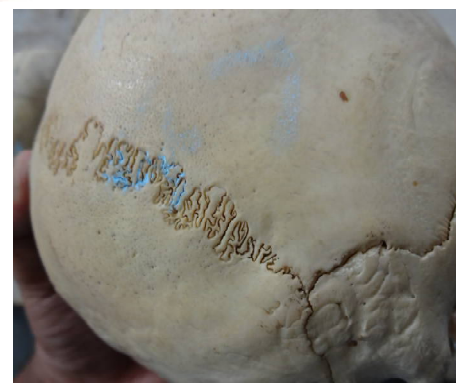**Fig. 1A:** Sutural bones in Lambdoid suture.



**Fig. 1B:** Sutural bones in Lambdoid suture.



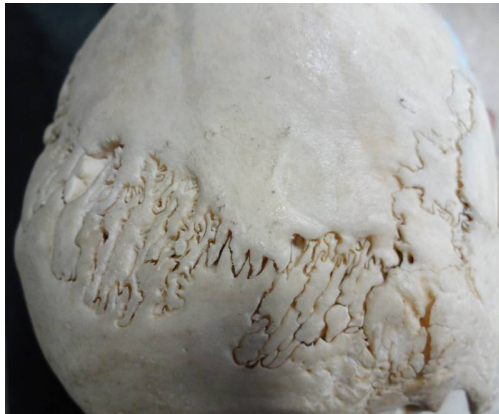
**Fig. 1C:** Sutural bones in Lambdoid suture.



**Fig. 1D:** Sutural bones in Lambdoid suture.

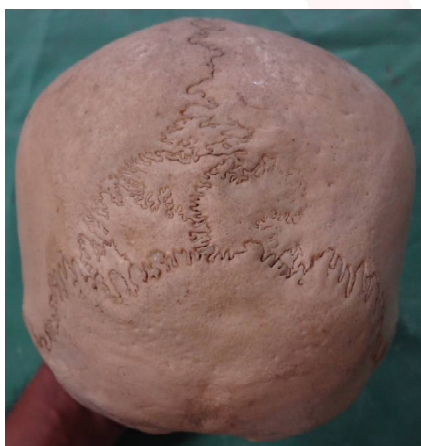


**Fig. 1E:** Sutural bones in Lambdoid suture.



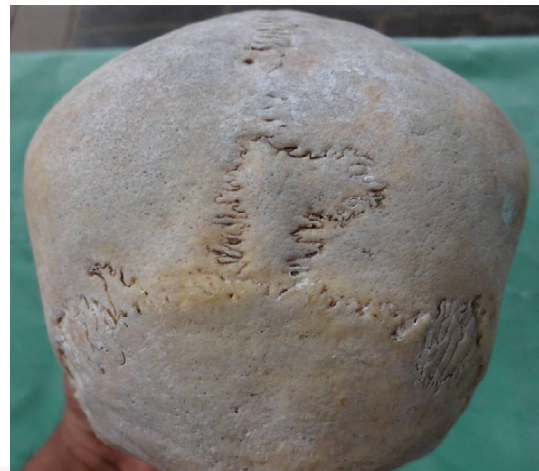**Sutural Bones at Lambda:** Sutural bones are identified at lambda. They appeared like islands. The picture (Fig. 2 A) shows four number of islands like sutural bones at lambda. The picture (Fig. 2 B) shows only one island like sutural bone at lambda and also some sutural bones seen in lambdoid suture. The picture (Fig. 2 C) shows two number of islands like sutural bones at lambda and appears to be connected by isthmus. The picture (Fig. 2 D) shows more than fifteen number of islands like sutural bones starting from obelion, along lambda and also in lambdoid suture.

**Fig. 2A:** Shows four number of islands like sutural bones at lambda.




**Inca Bones / Goethe's Ossicles:** Inca Bones / Goethe's ossicles are identified in two skulls (Fig. 3 A & Fig: 3 B). These bones are results of non-union of squamous part of occipital bone with the rest. It is also called as inter-parietal bones. The next picture (Fig. 3 C) shows a rare


**Fig. 2B:** shows only one island like sutural bone at lambda and also some sutural bones seen in lambdoid suture.



**Fig. 2C:** Shows two number of islands like sutural bones at lambda and appears to be connected by isthmus.




**Fig. 2D:** Shows more than fifteen number of islands like sutural bones starting from obelion, along lambda and also in lambdoid suture.






case of half inca bone which can mimic occipital fracture.


**Fig. 3A:** Inca Bones / Goethe's ossicles.



**Fig. 3B:** Inca Bones / Goethe's ossicles.



**Fig. 3C:** Shows a rare case of half inca bone which can mimic occipital fracture.



## DISCUSSION

Sutural bones occur in all the individuals but can be determined genetically in certain cases [8].

**Factors Responsible For Formation of Wormian Bones:** Incidence was more among the artificially deformed skulls. [8]

According to Jeanty et al [9] The sutural bones are found in large numbers if the skull is

enlarged, regardless of the cause of enlargement. He also proposed that sutural diastasis induces the formation of ectopic ossification centers. He also states that stress on the fetal skull bones during labour is an additional factor for separation of bone growing areas.

**Metabolic disorders:** Hess[10] proposed that metabolic disorders of the mesoderm will lead to sutural bone formation. He also noted that these bones are found in non symmetrical skulls, metopism and congenital abnormalities of the central nervous system.

**Significance of Wormian Bones:** In the 16th century, the sutural bones were first identified in association with cerebral disorders [11]. Although the exact mechanisms responsible for the formation of wormian bones are unknown, some studies showed that they are acting as markers for the identification of anomalies of the central nervous system. When wormian bones occur as abnormal variant, they tend to be smaller and less numerous than when they are associated with skeletal dysplasias[8][11].

Pryles CV and Khan AJ [11] reported 93% prevalence of sutural bones in the individuals having central nervous system abnormalities and 100% prevalence in mentally retarded population.

Presence of these bones can mislead in the diagnosis of fracture of skull bones. The explanation for the occurrence of Inca bone above the highest nuchal line is developing from membrane and usually from two pairs of centres [4, 12].

## Along the Lambdoid Suture:

The sutural bones found in lambdoid sutures are termed as preinterparietal bone [4, 12]. The presence of series of wormian bones in lambdoid sutures causes difficulty in posterior approach to the cranial cavity. The multiple wormian bones are misdiagnosed as multiple fractures.

Radiologist has reported cases of wormian bones associated with rickets, hypothyroidism, Down syndrome, osteogenesis imperfecta, pycnodysostosis and cleidocranial dysplasia [13]. Conversely Jeanty et al [9] have reported the presence of wormian bones in four fetuses, but none of these cases were associated with any anomalies.

**Table 1:** Comparison of Wormian Bone frequency between previous reports and present study.

SL. No.	Author	Method of Study	Wormian Bones Location
1	Jeanty et al. 2000 [9]	Using CT Scan reports	2 in Posterior Fontanelle – 3 cases 3 in Posterior Fontanelle – 1 case.
2	Berry and Berry 1967 [14]	Direct visualization of skull bones.	coronal and squamosal sutures.
3	Tewari et al 1982 [12]	Direct visualization of skull bones	Absence of wormian bones
4	B. Marti 2013 [15]	Using CT Scan reports	22 in sagittal suture 252 in Right Lambdoid suture 256 in left Lambdoid suture 45 in Right squamosal suture 41 in left squamosal suture 178 in posterior fontanelle
5	Present study	Direct examination of skull bones	36 in Lambdoid suture.

Only few studies are reported with the occurrence of wormian bones in the coronal, sagittal and squamosal suture. Berry and Berry [14], in their study on epigenetic variations in the human cranium, reported the presence of wormian bones in the coronal and squamosal sutures. However, Tewari et al. [12] reported absence of sutural bones in a study of sample size 1500 skulls.

#### Significance of Sutural bones in Radiography:

Simple non-depressed skull fractures can be identified by sharp lucency with non-sclerotic edges. But in sutural bones image show a zigzag pattern with interdigitations and sclerotic borders similar to major calvarial sutures. High impact fractures can cross suture lines or extend from one major suture to another and merge with the major suture. Plain radiograph will show lucency in skull fractures. CT scan with 3D reconstruction will show a well-defined lucency but bone scan is ineffective in detecting skull fractures. Knowledge of the normal anatomy, development and timing of sutural closure are also important in the evaluation of questionable fractures.

#### CONCLUSION

Presence of sutural bones may lead to complications in “Burr hole” surgery of skull vault. Neurosurgeons should have good awareness about these sutural bones and they should have appropriate training to handle skulls with sutural bones. The sutural bone may be mistaken as fracture of skull in case of trauma.

Present study with large sample size of the same population shows 14.4% of overall occurrence of wormian bones.

Wormian bones are clinically important markers for many syndromes. Wormian bones may also be seen in: Rickets, “Kinky-hair” Menke’s syndrome, Otopalatodigital syndrome, Cleidocranial dysostosis, Pycnodysostosis, Hypoparathyroidism and hypophosphatasia, Primary acro-osteolysis, Down’s syndrome [9]. Knowledge of these details will be helpful for Radiologists to diagnose these types of congenital syndromes as early as possible in intra-fetal life and take necessary steps to provide them a healthy future.

#### ACKNOWLEDGEMENTS

I convey my sincere thanks to my family members and my colleagues.

#### Conflicts of Interests: None

#### REFERENCES

- [1]. Bennett KA. The etiology and genetics of wormian bones. Am J Phys Anthropol. 1965;23(3):255-60.
- [2]. Glorieux FH, Osteogenesis Imperfecta, Best Practice & Research Clinical Rheumatology. 22:1, pp. 85-100. 2008.
- [3]. Wormian Bones: Differential Diagnosis #6, The Radiology Blog, Published April 27, 2012.
- [4]. Saxena SK, Chowdhary DS, Jain SP. Interparietal bones in Nigerian skulls. J. Anat. 1986;144:235-7.
- [5]. Carolineberry A, Berry RJ: Epigenetic variation of the human cranium. J Anat. 1967;101:361-79.
- [6]. Gopinathan K., Dhall U., Chhabra S: Sutural bones in the north Indian population. Journal of Anatomical Society of India. 1998;47(2):91-6.

- [7]. Pal GP, Tamankar BP, Routal RV and Bhagwat SS. The ossification of the membranous part of the squamous occipital bone in man. J Anat. 1984; 138:259-66.
- [8]. El-Najjar M, Dawson GL. genetic The effect of artificial cranial deformation on the incidence of Wormian bones in the lambdoidal suture. Am. J. Phys. Anthropol. 1977;46:155-60.
- [9]. Jeanty P, Silva SR, Turner C. Prenatal diagnosis of wormian bones. J Ultrasound Med 2000;19:863-9.
- [10]. Hess L. Ossicula wormiana. Hum. Biol 1946;18:61-80.
- [11]. Pryles CV, Khan AJ. Wormian bones. A marker of CNS abnormality? Am J Dis Child 1979;133:380-2.
- [12]. Tewari PS, Malhotra VK, Agarwal SK, Tewari SP. Preinterparietal bone in man. Anat. Anz. 1982;152:337-9.
- [13]. Murlimanju, B.V., Prabhu, L.V., Ashraf, C.M., Kumar, C.G., Rai, R. and Maheshwari, C. Morphological and topographical study of Wormian bones in cadaver dry skulls. J. Morph. Sci. 2011;28(3):176-9.
- [14]. Berry AC, Berry RJ. Epigenetic variation in the human cranium. J Anat. 1967; 101(2):361-79.
- [15]. B. Marti. Wormian bones in a general paediatric population. Diagn Interv Imaging. 2013;94:428-32

**How to cite this article:**

A Arun Kumar, B. Rajesh, K. Arumugam, V. Tamilalagan. SUTURAL BONES ASSOCIATED WITH LAMBDROID SUTURE OF HUMAN SKULL: PRESENCE, VARIATIONS AND CLINICAL IMPORTANCE . Int J Anat Res 2016;4(2):2331-2336. **DOI:** 10.16965/ijar.2016.208