

MORPHOMETRY OF EAR PINNA IN SEX DETERMINATION

B. Senthil Kumar *¹, G. Panneer Selvi ²

¹ Assistant Professor, Department of Anatomy, Vinayaka Mission's Kirupananda Variyar Medical College and Hospital, Salem, Tamil Nadu, India.

² Tutor, Department of Anatomy, Vinayaka Mission's Kirupananda Variyar Medical College and Hospital, Salem, Tamil Nadu, India.

ABSTRACT

Introduction: The ear lobule morphometry gives information on age and sex which plays a valuable role in forensic investigation. The auricle plays an important role in the clinical diagnosis of congenital anomalies and syndromes.

Aim of the study: The present study was done to determine the sex by morphometry of ear pinna in two different populations (Malaysian and Indian).

Material and methods: The study population includes Indians 50 males and 50 females between 20-30 years and also Malaysians 50 males and 50 females between 20-30 years. Four linear dimensions which is the length and the width of ears, length of cartilaginous ear and ear lobe length was measured and compared.

Results and Conclusion: Dimensions of ear in Malaysian male and females showed higher values when compared to that of Indian male and females, the Malaysians showed longer ear dimensions when compared to that of Indians it is believed that the data obtained in the present study would serve some purposes in ear morphology and for anthropometric considerations.

KEY WORDS: Ear Pinna, Indians, Malaysians, Morphometry, Sex determination, Anthropometry.

Address for Correspondence: Dr. B. Senthil Kumar, Assistant Professor, Department of Anatomy, Vinayaka Mission's Kirupananda Variyar Medical College and Hospital, Salem – 636308, Tamil Nadu, India. **E-Mail:** skdrchinu88@gmail.com, chinus.kumar9@gmail.com

Access this Article online

Quick Response code



DOI: 10.16965/ijar.2016.244

Web site: International Journal of Anatomy and Research
ISSN 2321-4287
www.ijmhr.org/ijar.htm

Received: 19 May 2016	Accepted: 14 June 2016
Peer Review: 19 May 2016	Published (O): 30 June 2016
Revised: None	Published (P): 30 June 2016

INTRODUCTION

The external ear consists of auricle or pinna and external acoustic meatus. The auricle is made up of elastic cartilage lined by skin on both sides. The lower part of the auricle is made up of connective tissue covered by skin which is called as lobule. The ear pinna is formed in-between fourth to sixth weeks of gestation when the neural crest cells of the first and second pharyngeal arches interacts with the underlying surface ectoderm of these arches. At this

time six auricular hillocks appears, which are derived from the first and second pharyngeal arches [1]. These hillocks develop into the folds of the pinna and gradually get shifted to their final position on the head. The cartilaginous framework and connective tissues of the pinna are derived from the neural crest cells and the muscles of the pinna are derived from the head mesoderm [1].

A vast knowledge of normal ear dimensions will

be of much use for the plastic surgeons rectifying the possible ear pinna defects. The forensic specialist needs the ear pinna dimensions for identifying a person, whereas the manufacturer needs for making ear prosthesis. The dimensions vary in different ethnic groups, which necessitate them to base their observations on the data specific to the ethnic group [2]. The morphometric standards vary in various ethnic groups. North Western Indian population was found to have smaller ear lobule than Japanese or Caucasians [3].

The auricle plays an important role in the clinical diagnosis of congenital anomalies and syndromes. A deformation in auricular shape and size or spatial dislocation of the auricle on the face can point toward a possible anomaly in the patient. Auricular deformation is seen in Trisomy 13 and 18 syndromes, in case of Down's syndrome the auricles are smaller than normal.

Auricular appearance and its symmetry contribute enormously to the facial aesthes. Cosmetic surgery and facial rejuvenation have become quite popular not only in the West but also in many developing countries. The treatment of auricular dimensions or to perform facial rejuvenation by a plastic surgeon requires morphometry data of auricle.

This study aimed to provide anthropometric information about the normal dimensions of the external ear such as total ear length and width, length of cartilaginous ear and ear lobe of the adult male and female auricle of Indians and Malaysian populations. To find out the difference in morphometric measurements between the male and female gender and also between the right and left ear in each gender.

MATERIALS AND METHODS

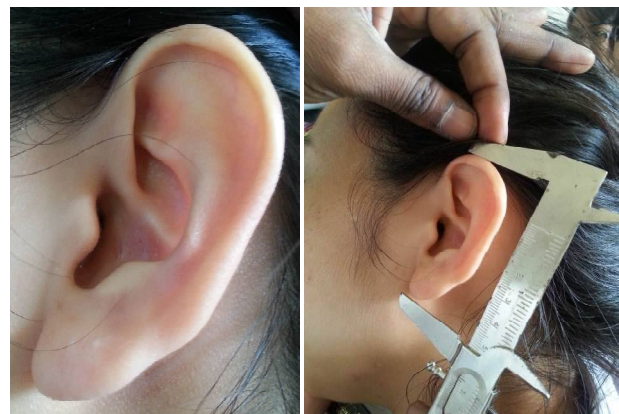The study population includes Indian population 50 males and 50 females between 20-30 years and also from Malaysian population 50 males and 50 females between 20-30 years from Penang International Dental College and VMKV Medical College, Salem. It has been opined that 85% of the growth of the ear occurs before 3 years of age, with the remaining 15% occurring before age 20. Beyond 20 years of age are basically attributable to secondary elongation of the earlobe due to gravitational forces [4].

The institutional ethical clearance was obtained from VMKV Medical College, Salem. The study was a descriptive cross sectional study carried as a part of another study along with other facial measurements. Subjects with history of craniofacial trauma, ear diseases, congenital abnormalities or surgery of the ear were excluded from the study. Prior to data collection, the subjects were informed of the nature and purpose of the study, and only those who gave their consent were included in the study [5].

Anthropometry involves measurements of the pinna based on international standard (Figure 1). [6-9]. Each subject was made to sit in a natural head position in a chair with a backrest and positioned the head so that the subject looked straightforward with the lower borders of the eye sockets in same horizontal plane as the external auditory meatuses (Frankfurt plane) [5]. Four parameters were measured on each of the right and left ears. Four linear dimensions which is the length of ears from supraaurale to subaurale (AB), the width of ears from preaurale to post aurale (CD), length of cartilaginous ear from supraaurale to antiragus (AE) and ear lobe length from antiragus to subaurale (EB) was measured (Figure 1). The Auricular index was calculated using the formula - The width of the auricle X 100 / length of the auricle.

The data obtained were subjected to statistical analysis using descriptive statistics, *t* test with the aid of statistical package for social sciences (SPSS). *P* < 0.05 was considered statistically significant.

Fig. 1: Pictures showing ear landmarks and dimensions.



AB = Total ear length (Physiognomic ear length); CD = Ear width (Physiognomic ear width); AE = Length of cartilaginous ear; EB = Ear lobe length.

RESULT AND DISCUSSION

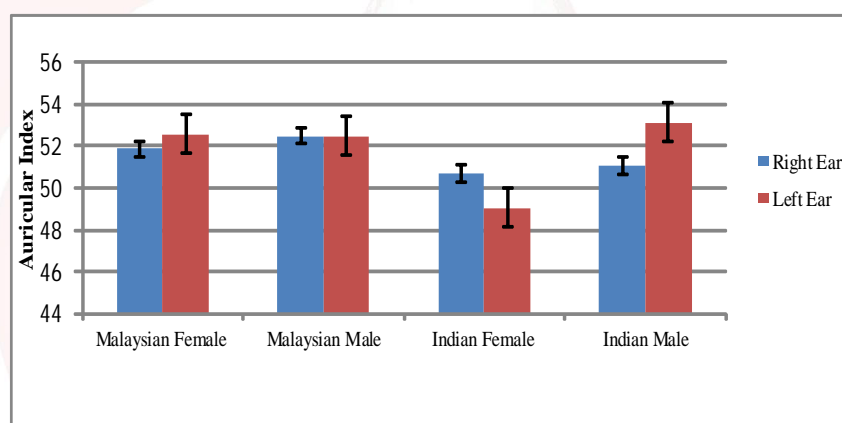
Table 1: Morphometry of Ear pinna in Malaysians (Female).

Population	Side	Total ear length (cm)	Total ear width (cm)	Length of cartilaginous ear (cm)	Ear lobe length (cm)
M.Female	Right	5.62 ±0.09	3.06±0.07	4.49±0.09	2.11±0.08
	Left	5.99±0.09 [#]	3.15±0.06 [#]	4.34±0.08 [#]	2.07±0.07 [#]
M.Male	Right	6.02±0.13	3.16±0.09	4.88±0.08	1.90±0.13
	Left	6.08±0.16 [#]	3.19±0.08 [#]	4.82±0.09 [#]	1.83±0.12 [#]
I.Female	Right	5.84 ±0.09	2.96±0.06	4.35±0.08	1.51±0.08
	Left	5.35±0.10 [#]	2.83±0.05 [#]	4.24±0.08 [#]	1.39±0.07 [#]
I.Male	Right	6.11 ±0.09 ^{R*}	3.12±0.07 ^{R#}	4.42±0.07 ^{R#}	1.89±0.08 ^{R*}
	Left	5.85±0.08 ^{#, L*}	3.16±0.07 ^{#, L#}	4.32±0.07 ^{#, L#}	1.86±0.06 ^{#, L*}

Number = 50, M. Female – Malaysian Female, M.Male – Malaysian Male, I.Female – Indian Female, I. Male - Indian Male. Values expressed as Mean ± SEM (Standard Error Mean), *P<0.05 Significant, # - Statistically not significant. Right and left ear measurements were compared in each population by t test. All right and left ear measurements among all the population was compared by one way ANOVA. L# - left ear not significant, L* - Left ear significant, R# - Right ear not significant, R* - Right ear significant,

Graph 1: Auricular Index.

Number = 50,
Values expressed as Mean ± SEM
(Standard Error Mean)



The auricle reaches its mature height at 13 years in male and at 12 years in females [10]. Anthropometric studies had been carried out on the external ear of children with different conditions such as cleft lip/palate, Down's syndrome, chromosomal abnormalities like aneuploidy [11-13]. The diagnostic values of abnormality of external ear to establish the existence of an abnormality of the urinary tract, as a result of coincidence in the period of embryogenesis has been reported [13]. An acquired deformity that develops with aging may include elongation or Ptosis of the ear lobe [14]. The ear is an important and under-recognized defining feature of the face whose shape conveys information about age and sex that is clearly difficult to characterize [15].

McKinney et al. (1993) proved that there is no significant correlation between the earlobe

height and aging [9]. Brucker et al. (2003) on their morphometric study of the external ear, age and sex related differences, obtained a mean total ear height of 6.30 cm and an average lobular height of 1.88 cm. He also observed that though the total ear height was larger in the men, their lobular height and width remained nearly identical to women [6].

In the present study the Malaysian female total ear length, width and ear lobe height were comparatively same on both right and left side whereas the length of cartilaginous ear were slightly higher on right side than that of left side (Table 1). In case of Malaysian males the length of cartilaginous ear and ear lobe height showed a slight difference between the right and left side whereas the female total ear length and width did not show any difference. In the Indian population the morphometry of ear was found

to be more on right side when compared to left in both the sex. Graph 1 shows the auricular index among the Malaysian and Indian population.

Existence of sexual dimorphism in external ear dimensions were documented [15]. It was shown that sexual dimorphism exists in auricular linear dimensions between males and females with higher values in males [6]. The differences in males and females may be due to auricle expansion which starts earlier in males than females, which continues up to the older age [6]. The variations in gender may also be influenced by genetic factors which vary with sex.

In the present study the Malaysian male total ear length, width and length of cartilaginous ear showed higher values when compared to female whereas the ear lobe height were longer in female than that of Malaysian males (Table 1). The Indian males total ear length, width, length of cartilaginous ear and ear lobe length were higher than that of Indian females (Table 3&4). The present study was in correlation with the study done by Brucker et al. (2003) [6]. It was shown that sexual dimorphism exists in auricular linear dimensions between males and females with higher values in males [6]. Ito et al. (2001) studied the morphological age changes in adult human auricular elastic cartilage and reported that auricular size increases significantly with age in both men and women due to the changes in the elastic fibers after adulthood [10].

Bozkir et al. (2006) observed significant difference in ear height between Turkish and Japanese populations and the total auricular height and width were longer in males within the Turkish population [16]. In the present study significant differences was found in the linear dimensions of ear in Malaysian male and females when compared to that of Indian male and females. The Malaysians showed longer ear dimensions when compared to that of Indians. The dimensions vary in different ethnic groups, which necessitate them to base their observations on the data specific to the ethnic group [2]. The morphometric standards vary in various ethnic groups. North Western Indian population was found to have smaller ear

lobule than Japanese or Caucasians [3,17].

CONCLUSION

The ear lobule morphometry gives information on age and sex which plays a valuable role in forensic investigation. Age dependent changes in lobules and its influence on individual identification through photographs or ear prints are of significance in forensic medicine and criminology. Initially ear lobule parameters were studied for the surgical treatment of congenital deformities and reconstruction. Now the ear lobules are also used in otomorphology for identification. In conclusion, dimensions of ear in Malaysian male and females showed higher values when compared to that of Indian male and females, the Malaysians showed longer ear dimensions when compared to that of Indians it is believed that the data obtained in the present study would serve some purposes in ear morphology and for anthropometric considerations. In future the study will be continued to relate the results of our present study to the height of an individual and some facial/cranial anthropometric parameters in correlation with the bite mark analysis for forensic investigations.

ACKNOWLEDGEMENTS

Work attributed to Penang International Dental College and VMKV Medical College, Salem, Tamilnadu, India.

Conflicts of Interests: None

REFERENCES

- [1]. Van De Water T.R., Staecker H. Otolaryngology: Basic Science and Clinical Review. Thieme Medical Publishers Inc. New York. 2006:251.
- [2]. Ruma P, Singh P. Anthropometry of the Normal Human Auricle: A Study of Adult Indian Men. *Journal of Aesth Plast Surg* 2007;31:372-379.,
- [3]. Sharma A, Sidhu NK, Sharma MK, Kapoor Kanchan, Singh B. Morphometric study of ear lobule in north-west Indian male subjects. *Anatomical Science International* 2007;82:98-104.
- [4]. Adamson J.E., Hortox C.E., Crawford H.H. The growth pattern of the external ear. *Plast Reconstr Surg* 1965;36(4):466-70.
- [5]. Eboh D. Morphological changes of the human pinna in relation to age and gender of Urhobo people in Southern Nigeria. *J Exp Clin Anat* 2013;12:68-74.
- [6]. Brucker M.J., Patel J., Sullivan P.K. A morphometric study of the external ear: Age and sex related differences. *Plast Reconstr Surg*. 2003;112(2):647-52.

- [7]. Ekanem A.U., Garba S.H., Musa T.S., Dare N.D. Anthropometric study of the pinna (Auricle) among adult Nigerians resident in Maiduguri metropolis. *J Med Sci* 2010;10(6):176-80.
- [8]. De Carlo D., Metaxas D., Stone M. An anthropometric face model using variational techniques. Proceedings of the 25th Annual Conference on Computer Graphics and Interactive Techniques. New York, 1998.
- [9]. McKinney P., Giese S., Placik O. Management of ear in rhytidectomy. *Plast Reconstr Surg.* 1993;92(5):858-66.
- [10]. Ito I et. al. A morphological study of age changes in adult human auricular cartilage with special emphasis on elastic fibres. *Laryngoscope.* 2001;111:881-6.
- [11]. Nathan N, Latham K, Cooper J, Perlyn C, Gozlan I, Thaller SR. Anthropometry of the external ear in children with cleft lip and palate in comparison to age-matched controls. *J. Craniofac. Surg.*, 2008;19:1391-1395.
- [12]. Sforza C, Dellavia C, Tartaglia GM, Ferrario VF. Morphometry of the ear in Down's syndrome subjects: A three-dimensional computerized assessment. *Int. J. Oral Maxillofac. Surg.*, 2005;34:480-486.
- [13]. Lettieri L, Rodis JF, Vintzileous AM, Feeney L, Craffey A. Ear length in second-trimester aneuploid fetuses. *Obstetr. Gynaecol.* , 1993;81:57-60.
- [14]. Perrin P, Baithelme H, Moyot D, Pem C, Schmitt M. External ear and abnormality of the urinary tract: A comparative study of 2 series (100 and 150 cases). *Rev. Laryngol. Otol. Rhinol. (Bord)*, 1999;112:399-403.
- [15]. Sidra Shireen, Vrushali P. Karadkhelkar. Anthropometric Measurements of Human External Ear. *Journal of Evolution of Medical and Dental Sciences* 2015;4(59):10333-10338.
- [16]. Bozkir, M.G., P. Karakas, M. Yavuz and F. Dere. Morphometry of the external ear in our adult population aesth. *Plast. Surg.* 2006;30:81-85.
- [17]. Taura M. G. et al. External ear anthropometry among Hausas of Nigeria; the search of sexual dimorphism and correlations. *World Journal of Medicine and Medical Science Research.* 2013;1(5):091-095.

How to cite this article:

B. Senthil Kumar, G. Panneer Selvi. MORPHOMETRY OF EAR PINNA IN SEX DETERMINATION. *Int J Anat Res* 2016;4(2):2480-2484. **DOI:** 10.16965/ijar.2016.244