

PREVALENCE OF PALMARIS LONGUS AGENESIS IN A SEMI URBAN POPULATION: A STUDY IN A TERTIARY CARE HOSPITAL

Pabbati Raji Reddy

Associate Professor, RVM Institute of Medical Sciences and Research Center, Medak, Telagana, India.

ABSTRACT

Introduction: Palmaris longus is one of the very few muscles of the body which shows a wide variation in position, duplication, slips and can be found reverted. One of the most common variations of this muscle is its agenesis or absence.

Materials and Methods: 200 hundred patients out of which 100 were males and 100 were females, were included into the study. All the patients were examined for Palmaris longus by the clinical inspection of the volar aspect of the wrist by Schaeffer's test. If the tendon was found to be absent, the confirmation was done by Mishra's test I and II, Pushpakumar's test and Thompson's test.

Results: Palmaris longus muscle was absent in a total of 18.5% subjects. Out of them males were 10.5% and the females were 8%. 23.8% subjects out of the males had bilateral agenesis while unilateral agenesis was seen in 76.2% cases. Among the females, 43.75% had a bilateral agenesis and 56.25% had unilateral agenesis. Most of the agenesis was seen on the non dominant hand.

Conclusion: Palmaris longus agenesis was seen in 18.5% of the cases overall, concluding that it is very prevalent in our geographical region.

KEYWORDS: Palmaris longus, agenesis, Incidence.

Address for Correspondence: Dr. Pabbati Raji Reddy, Associate Professor, RVM Institute of Medical Sciences and Research Center, Medak, Telagana, India.

E-Mail: pabbatirajireddy@gmail.com

Access this Article online

Quick Response code



DOI: 10.16965/ijar.2016.236

Web site: International Journal of Anatomy and Research
ISSN 2321-4287
www.ijmhr.org/ijar.htm

Received: 11 May 2016

Accepted: 07 Jul 2016

Peer Review: 12 May 2016

Published (O): 31 Jul 2016

Revised: None

Published (P): 31 Jul 2016

INTRODUCTION

Palmaris longus muscle is a fusiform, slender muscle located between the flexor carpi radialis and flexor carpi ulnaris muscles. It originates from the common flexor around the medial epicondyle and ends as a slender, flattened tendon, passing superficially over the transverse carpal ligament and inserting into the palmar aponeurosis [1].

It is supplied by the median nerve and its action is the flexor of the hand at the wrist and in

making the palmar aponeurosis tense.

It is one of the very few muscles of the body which shows a wide variation in position, duplication, slips [2] and can be found reverted [3]. Due to its variations, it is one of the muscles to be frequently studied and investigated in cadavers as well as in vivo [4]. The earlier studies on this muscle included vascular and neural compression [5], in surgery by using the tendon for grafting or other reconstructions [2,6,7], in radiological analysis, in studying the

performance of athletes, and in genetic and anthropological studies [2].

Apart having secondary function, the loss of this muscle does not cause any significant loss in the strength of the muscle [8]. Therefore, it has been used in reconstructive plastic surgery, mainly in the setting of the tendon grafting, and also in lip augmentation, ptosis correction and facial palsy management [9-12].

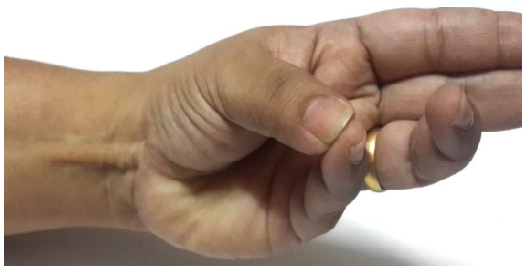One of the most common variations of this muscle is its agenesis or absence. The prevalence of agenesis of this muscle is estimated to be around 15% although in different ethnic races, it had been found to be different [13-15]. Among the Eutoppeaan population, the absence was found to be 15% [16] and in an American study it was found to be 12% [17], while it was much lower in a Chinese study (4.6%) [18].

Due to the wide variation in the absence of this muscle, this study was performed to assess the prevalence of the Palmaris longus agenesis in our geographical area.

MATERIALS AND METHODS

This study as performed by the Department of Anatomy on 200 patients attending the various outpatient departments of Mediciiti medical college and hospital, over a period of two years. Out of the 200 hundred patients, 100 were males and 100 were females. Demographic details such as age, weight, social status, place and type of work was noted. All patients with any prior surgeries to the limbs, whether upper or lower, trauma to the limbs and any other physical disabilities were excluded from the study. All the patients were examined for Palmaris longus by the clinical inspection of the volar aspect of the wrist by Schaeffer's test²¹, which is a slight wrist flexion with thumb and little finger opposed (Fig. 1).

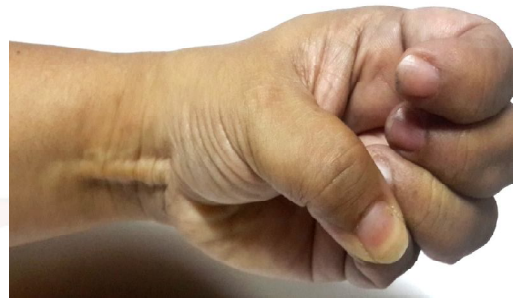Fig. 1: Schaeffer's test for Palmaris longus.



In case, the tendon was not visible or palpable with the above standard tests, other tests such as Thompson's test [19], Mishra's test I [20], Mishra's test II [20] and Pushpakumar's test were also done before agenesis of the muscle was concluded.

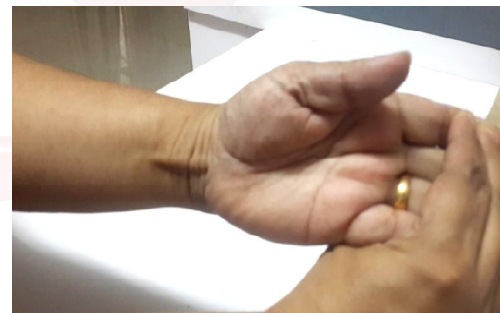Thompson's test: The subjects were asked to make a fist and flex the wrist. The Thumb was kept opposed and flexed over the fingers [19] (Fig. 2).

Fig. 2: Thompson's Test.



Mishra's Test I: The subjects were asked to flex the wrist, while the examiner passively hyper-extended the metacarpo-phalangeal joints of all the fingers²⁰ (Fig.3).

Fig. 3: Mishra's Test I.



Mishra's Test II: The subjects were asked to abduct the thumb against resistance with the wrist in slight palmar flexion (Fig. 4).

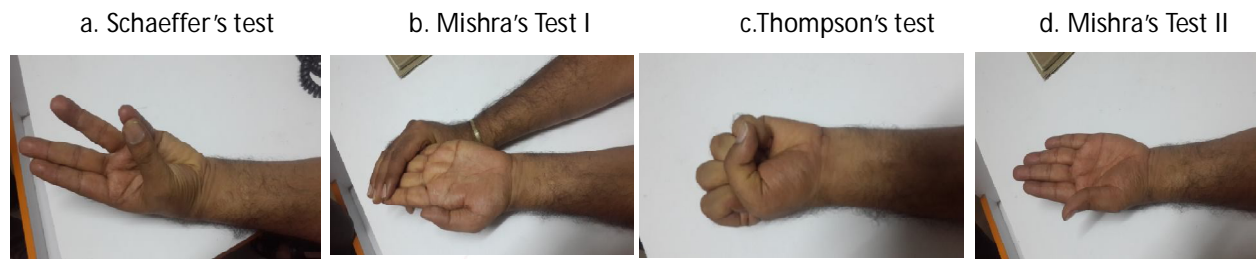
Fig. 4: Mishra's Test.



Pushpakumar's Test [22]: This is a two finger test where the subject is asked to fully extent the index and middle finger, keeping the wrist and all the other fingers flexed. The thumb is kept fully opposed and flexed.

RESULTS

Fig. 5: Absence of Palmaris longus muscle confirmation by:



Out of the 200 patients, 100 were males and 100 were females. The average age group of the patients was 21.45 years. Since this was not a parameter in our study, we didn't investigate the relation of age and absence of the muscle.

Palmaris longus muscle was absent in a total of 37 (18.5%) subjects. Out of the males, it was absent in 21 (10.5%) subjects and among the females the number was 16 (8%). All the subjects were confirmed by all the above 5 tests, (Fig:5)

5 (23.8%) subjects out of the 21 males had bilateral agenesis while 15 (76.2%) had an absence of the muscle in one hand only. Among the females, 7 (43.75) had a bilateral agenesis and 9(56.25%) had unilateral agenesis. (Table1).

Most of the agenesis was seen on the left hand, which was the non dominant hand. Of the 5 subjects, where the agenesis was on the right hand, were non dominant while only 3 agenesis was seen in the dominant hand.

Table 1: Number of subjects showing unilateral and bilateral agenesis.

	Males	Females	Right side	Left side
Overall	21	16	-	-
Unilateral	16	9	5	16
Bilateral	5	7	-	-

DISCUSSION

Palmaris longus is one of the most variable muscles in the human body. Its tendon has not much use functionally but it is very useful in grafting by the hand surgeon and plastic surgeons as well as by ophthalmologists and otolaryngeologists [9-12]. It is usually the first choice of the surgeons as the necessary requirements are fulfilled such as length, diameter and availability and can be used without any deformity [23].

In the vertebrates, the Palmaris longus muscle is present only in the mammals, especially in those where the muscle is used for ambulation. It is found to be absent in higher apes and chimpanzees [17].

The incidence of agenesis of this muscle has been the topic of several studies. The prevalence in our studies had been seen more in males than in females. This was in accordance to a study conducted by Thompson et al, where predominantly, the agenesis of Palmaris longus muscle was seen in males rather than in females [26].

But, the present study was in contrast to studies by Vanderhooft et al [17] and Troha et al [23] where females were reported to be the predominant gender to have Palmaris longus muscle agenesis. Similar results were seen in studies by Kapoor et al²⁴ and Reimann et al [25].

Although we have not studied the relation of the agenesis of the muscle among the different races, in an Asian study the absence of this muscle was more often seen in the Caucasian population with about a prevalence of 12 – 24% [16,17,26]. The least was seen in the Singaporean population of only about 4.6% [18]. In yet another study in the Chinese population, the prevalence was seen to be 2.8%, while 3.7% prevalence was observed among the Amazon Indians [4].

In our study, the overall prevalence was observed to be 18.5%. This was higher than few other studies conducted in India. Mugalur et al reported an overall incidence of 10.9% [27].

76.2% of the males with absence of the Palmaris longus muscle had unilateral agenesis, most of it being on the left hand, while only 23.8% of them had bilateral agenesis. The number of bilateral agenesis was more in the females with 43.75% of them and 56.25% of them showed

unilateral agenesis. Bilateral agenesis was observed to be around 8-16% and unilateral 4-16%, overall, by Sharma et al [28].

There was a wide range of variability among the authors regarding the non dominant hand to have agenesis rather than the dominant hand. We also observed in our study, that 2 women, who had agenesis in the right hand were left hander, showing that the agenesis mostly affected the non-dominant hand. Bilateral agenesis was found to be more common in females with left hand being more predominant in similar studies, in accordance to our study, as was observed by Schaeffer et al [21].

CONCLUSION

Agenesis of the Palmaris longus muscle was observed in 18.5% of the study subjects out of which, the predominant gender was males. Bilateral agenesis was seen 23.8% of the patients with agenesis and most of them were among the females. Left or the non dominant had was more affected then the dominant one.

Conflicts of Interests: None

REFERENCES

- [1]. Chaurasia BD, Human Anatomy, 1988;Vol 1, 3rd Ed:95.
- [2]. J. W. M. Kigera and S. Mukwaya, "Frequency of agenesis Palmaris longus through clinical examination—an East African study. PLoS ONE 2011;6(12). Article ID e28997.
- [3]. J. M. Cope, E. M. Looney, C. A. Craig, R. Gawron, R. Lampros, and R. Mahoney, "Median nerve compression and the reversed palmaris longus, " International Journal of Anatomical Variation 2009;2:102-104.
- [4]. A. B. M. Machado and L. J. A. Di Dio. Frequency of the musculus palmaris longus studied in vivo in some Amazon Indians. American Journal of Physical Anthropology 1967;27(1):11-20.
- [5]. M. A. Babinski, K. M. A. Valente, C. M. S. Savedra, C. H. F. Burity, and A. M. S. Sabrá, Variação anatômica do músculo palmar longo associado a ausência do arco palmar superficial e compressão do canal de Guyon. Acta Scientiae Medica 2008;2(2):54-58.
- [6]. V. S. Telles, B. A. L. Ernesto. Consideraciones anatómicas de los músculos inconstantes. MedUnab 1998;1(3):165-170.
- [7]. C. Fowlie, C. Fuller, and M. K. Pratten. Assessment of the presence/absence of the palmaris longus muscle in different sports, and elite and non-elite sport populations. Physiotherapy. 2012;98(2):138-142.
- [8]. Lippert, L. Cinesiologia Clínica para Fisioterapeutas, incluindo teste para auto-avaliação. 2 Ed: Rio de Janeiro, Ed. Revinter, 1996.
- [9]. Kurihara K, Kojima T, Muramo E, Frontalis suspension for blepharoptosis using Palmaris longus tendon. Ann Plast Surg 1984;13:274-278.
- [10]. Atiyeh BA, Hashim HA, Hamdan AM, Kayle DI, Musharafieh RS. Lower reconstruction and restoration of oral competence with dynamic Palmaris longus vascularised sling. Arch Otolaryngol Head Neck Surg. 1998;124:1390-1392.
- [11]. Davidson BA., Lip augmentation using the Palmaris longus tendon. Plast Reconstr Surg. 1995;95:1108-1110.
- [12]. Naugle TC Jr, Faust DC. Autogeneous Palmaris longus tendon as frontalis suspension material for ptosis correction in children. Am J Ophthalmol; 199; 127:488-489.
- [13]. Kleinert HE, Pulvertaft RG, Smith DJ. Flexor tendon grafting in the hand. In: Jupiter JB, editor. Flynn's Hand Surgery. Baltimore: Williams & Wilkins. 1991:285.
- [14]. Zancolli EA, Cozzi EP. The retinaculum cutis of the hand. In: Zancolli EA, Cozzi EP (eds). Atlas of Surgical Anatomy of the Hand. New York: Churchill Livingstone, 1992: 2.
- [15]. Valentine P. Extrinsic muscles of the hand and wrist: An Introduction. In: Tubiana R (ed). The Hand. Vol I. Philadelphia: WB Saunders, 1981:237.
- [16]. George R. Co-incidence of the palmaris longus and plantaris muscles. Anat Rec 1953; 116: 521-3.
- [17]. Vanderhooft E. The frequency and relationship between the palmaris longus and plantaris tendons. Am J Orthop 1996;25:38-41.
- [18]. Sebastin SJ, Lim AYT, Wong HB. Clinical Assessment of Absence of the Palmaris Longus and its Association With Other Anatomical Anomalies – A Chinese Population Study. Ann Acad Med Singapore 2006;35:249-5.
- [19]. Schaeffer JP. On the variations of the palmaris longus muscle. Anat Rec 1909;3:275-8.
- [20]. Thompson J. W, McBatts J, Danforth C. H. Hereditary and racial variations in the musculus palmaris longus. Am. J. Phys. 1921;4:205-20.
- [21]. Mishra, S. Alternative tests in demonstrating the presence of palmaris longus. Indian J. Plast. Surg. 2001;34:12.
- [22]. Pushpakumar SB, Hanson RP, Carroll S. The 'two finger' sign. Clinical examination of palmaris longus (PL) tendon. Br J Plast Surg 2004;57:184-5.
- [23]. Troha, F.; Baibak, G. J. & Kelleher, J. C. Frequency of the palmaris longus tendon in North American Caucasians. Ann. Plast. Surg. 1990;25:477-8.
- [24]. Thompson NW, Mockford BJ, Cran GW. Absence of the palmaris longus muscle: a population study The Ulster Medical Journal. 2001;70(1):22-24.
- [25]. Kapoor S. K, Tiwari A, Kumar A, Bhatia R, Tantuway V, Kapoor S. Clinical relevance of palmaris longus agenesis: Common anatomical aberration. Anat. Sci. Int. 2008;83:45-8.

- [26]. Reimann AF, Daseler EH, Anson BJ, Beaton LE. The Palmaris longus muscle and tendon. A study of 1600 extremities. Anat. Rec., 1944;89:495-505.
- [27]. Mugalur A, Shahane SM, Samant A, Pathak AC, Patil A & Reddy R. Anatomic variation of palmaris longus and flexor digitorum superficialis of little finger in Indian population. SICOT J. 2015;1:5.
- [28]. Sharma DK, Shukla CK, Sharma V. Clinical assessment of absence of Palmaris longus and its association with gender, body sides, handedness and other neighbouring anomalies in a population in central India. J Anat Soc, India.2012;61(1):13-20.

How to cite this article:

Pabbati Raji Reddy. PREVALENCE OF PALMARIS LONGUS AGENESIS IN A SEMI URBAN POPULATION: A STUDY IN A TERTIARY CARE HOSPITAL. Int J Anat Res 2016;4(3):2513-2517. **DOI:** 10.16965/ijar.2016.236

