

# MORPHOMETRY AND MORPHOLOGY OF SUPRA SCAPULAR NOTCH: IT'S IMPORTANCE IN SUPRASCAPULAR NERVE ENTRAPMENT

Neeta Chhabra <sup>\*1</sup>, Suraj Prakash <sup>1</sup>, MS Ahuja <sup>2</sup>.

<sup>1</sup> Assistant Professor, Dept. of Anatomy, Army College of Medical Sciences, Delhi Cantt, India.

<sup>2</sup> Professor and Head, Dept. of Anatomy, Army College of Medical Sciences, Delhi Cantt, India.

## ABSTRACT

**Introduction:** Suprascapular notch is the common site for entrapment of supra scapular nerve. SSN compression usually presents with vague pain across the scapula or dull shoulder ache. It is more common in overhead athletes like volleyball players. Better knowledge of the suprascapular notch anatomy may help to prevent and to assess more accurately suprascapular nerve entrapment syndrome. The regional variations in the incidence of complete absence of suprascapular notch and its involvement in suprascapular nerve entrapment neuropathy should be kept in mind during surgical or arthroscopic shoulder procedures.

**Materials and Methods:** The present study is done on the basis of classification proposed by Iqbal and Natis et al. 126 scapulae of North Indian origin were taken for the study. Morphometric measurement and shape of each supra scapular notch was studied.

**Results:** The present study showed Type II supra scapular notch (TD>VL) as the most common Type which was found in 47.6% of specimens. The most common shape of SSN found was U shaped (46%) followed by V shaped & J shaped at 24.6% & 15.9% respectively. Complete ossification of STSL leading to formation of bony foramen was observed in 2.4% while both notch and a bony foramen together was not found even in a single scapula in our study.

**Conclusion:** The shape & dimensions of SSN and complete ossification of STSL has been shown to be associated with increased risk of supra scapular nerve entrapment, resulting in weakness and wasting of supraspinatus and infraspinatus muscles. Anatomical knowledge of such variations should be kept in mind during surgical and arthroscopic shoulder procedures.

**KEY WORDS:** Scapula, suprascapular nerve, suprascapular notch, superior transverse scapular ligament, Vernier calipers.

**Address for Correspondence:** Dr. Neeta Chhabra, Assistant Professor, Dept. of Anatomy, Army College of Medical Sciences, Delhi Cantt-10, India. **E-Mail:** [neetachhabra86@gmail.com](mailto:neetachhabra86@gmail.com)

## Access this Article online

### Quick Response code



DOI: 10.16965/ijar.2016.267

**Web site:** International Journal of Anatomy and Research  
ISSN 2321-4287  
[www.ijmhr.org/ijar.htm](http://www.ijmhr.org/ijar.htm)

Received: 15 Jun 2016	Accepted: 15 Jul 2016
Peer Review: 16 Jun 2016	Published (O): 31 Jul 2016
Revised: None	Published (P): 31 Jul 2016

## INTRODUCTION

The suprascapular notch is situated in the lateral part of the superior border of the scapula; just medial to the base of the coracoid process. This notch is converted into a foramen by the superior transverse scapular ligament. This foramen transmits the suprascapular nerve to

the supraspinous fossa, whereas the suprascapular vessels pass above the ligament. The suprascapular nerve has a tortuous course from the supraspinous fossa to the infraspinous fossa through spinoglenoid notch. It supplies supraspinatus and infraspinatus muscles as well as sensory branches to the shoulder and

acromioclavicular joint [1,2]. Morphological variations of the suprascapular notch are very important clinically for possible predisposing factors, for compression of the suprascapular nerve in this region. In the whole population, approximately 1–2% of all shoulder pain is caused by the suprascapular nerve entrapment syndrome. This syndrome was first described by Kopell and Thompson in 1959 [3].

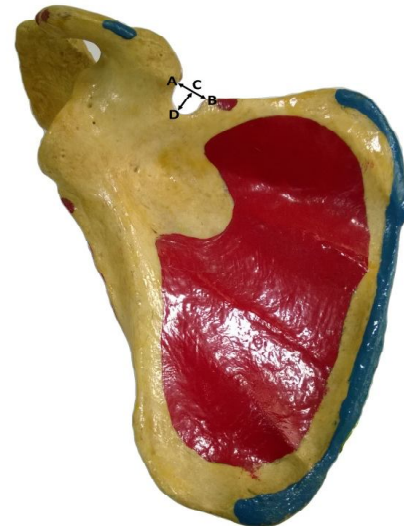
The results of suprascapular nerve entrapment are weakness of the arm, difficulty in external rotation and abduction, and then, atrophy of the infraspinatus and supraspinatus muscles. This entrapment syndrome is most frequently found in individuals with occupations which require a lot of overhead work involving extreme abduction and external rotation of shoulder. These include baseball players, weight lifters, tennis players, fencers, hunters using bows, dancers, figure skaters and athletes who repeatedly experience stress on their shoulder. This notch is an imp landmark of the supra scapular nerve during arthroscopic shoulder operation [4-8].

SSN has been classified by various workers in different populations on the basis of parameters such as vertical length, transverse diameter and shape of the notch [9-13]. Rengachary distinguished VI types of SSN on the basis of morphologic and geometric features. In Type I the superior border of the scapula presents a depression from the medial superior angle to the base of the coracoid process; Type II is described as a wide blunted "V"-shaped notch, occupying nearly a third of the superior border with the widest point along the superior border. Type III is a symmetric and "U"-shaped notch while Type IV is described as a very small "V"-shaped notch, frequently presenting a shallow groove near the notch; Type V is similar to type III, with partial ossification of the medial border of the notch and with the minimal diameter along the superior border of the scapula. Type VI is described as a bony foramen with a completely ossified STSL [11].

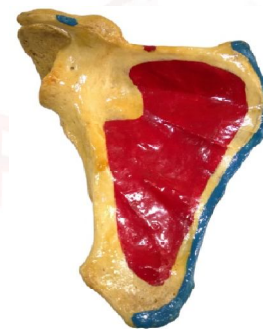
The aim of this study is to see the variations of dimensions and shape of supra scapular notch in North Indian scapulae considering them as possible predisposing factor for supra scapular nerve entrapment.

## MATERIALS AND METHODS

**Fig. 1:** Showing the measurements of suprascapular notch.



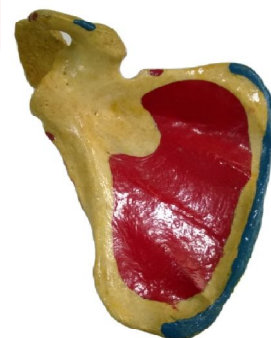**Fig. 2:** Showing the various shapes of suprascapular notch.



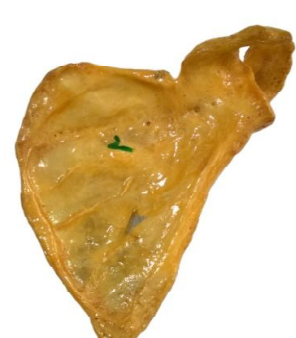a. Absent SSN



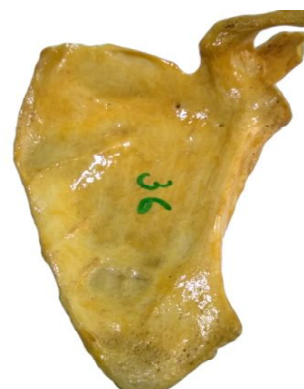b. Indentation



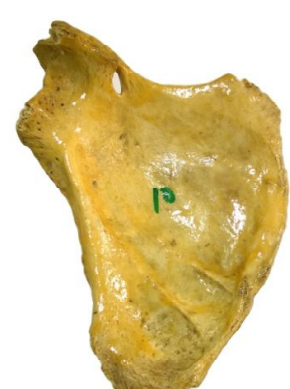c. U shaped



d. V shaped



e. J shaped



f. Complete ossification

In this study 126 dried, unbroken and completely ossified human scapulae (71 left sided and 55 right sided) were taken. These belonged to the collection of Dept of Anatomy ACMS Delhi Cantt and also taken on loan from nearby medical colleges. The gender and ages of the donors were not known. This study also includes scapulae where SSN was absent but those with broken superior border were excluded from the study. Measurements of SSN were made using classic osteometry with the digital vernier caliper and these were recorded in millimeters. Digital Vernier caliper used in this study was of resolution of 0.01 mm. The data was analyzed statistically. The shape of the SSN was also classified.

The following measurements were taken:

**(i) Transverse diameter of the suprascapular notch (TD)** (AB in Fig.1) measured along the superior border from the medial to the lateral margin of the notch.

**(ii) Vertical length of the suprascapular notch (VL)** (CD in Fig.1), measured as the maximal vertical distance between the deepest point at the base of supra scapular notch to an imaginary line between superior edges of notch.

On the basis of above measurements and on the previous description by Natsis et al [10] morphometric classification and typing of the suprascapular notches were done. Percentage of each type depending on the vertical and the transverse diameters of the SSN was calculated and compared with the percentage of the previous studies. We decided to apply Natis classification since it is simple and reproducible. In addition it has already been used in several studies and it allowed us to compare the results.

Various types of suprascapular notches according to Natis classification

**Type I** - Without a discrete notch

**Type II** - Notch with largest transverse diameter

**Type III** - Notch with largest vertical diameter

**Type IV** - Bony foramen

**Type V** - Notch and a foramen

## RESULTS

The results of the study are depicted as per table below.

**Table 1:** Shows the range, mean and SD of measurements of supra scapular notch.

Sr no	Parameters	Range (mm)	Mean (mm)	SD (mm)
1	Transverse diameter of supra scapular notch (TD)	2.95-16.88	7.78	3.09
2	Vertical Length of supra scapular notch (VL)	1.7-12.91	6.39	2.65

The mean transverse diameter and vertical length of the supra scapular notch in the present study was 7.78 mm and 6.39 mm with SD of 3.09 and 2.65 respectively. The range of transverse diameter was 2.95-16.88 mm and of vertical length was 1.7-12.91mm.

On examination of scapulae for presence or absence of notch and after taking measurements 5 different types were classified. Each type has its own percentage as shown in **Table 2**.

**Table 2:** Shows distribution of various types of SSN based on measurements.

Sr no.	Type	Description	No.	%age
1	Type I	Without a discrete notch	14	11.1
2	Type II	(TD>VL)	60	47.6
3	Type III	(VL>TD)	49	38.9
4	Type IV	Bony foramen	3	2.4
5	Type V	Bony foramen & notch	Nil	0

There were 14 scapulae (11.1%) without a discrete notch and they were considered as Type I (Fig.3a,b). The rest 112 (89.9%) scapulae showed the other four types (Fig.3 c,d,e,f).Type II in which the transverse diameter of the notch was longer than the vertical diameter (TD>VL) was present in 60 scapulae (47.6%).This was the most prevalent type, as the results of other studies (Table 4). Type III was present in 49 (38.9%) and had VL>TD.Type IV with suprascapular foramen only without a visible notch was found in 3 scapulae (2.4%). Type V i.e. presence of both notch and foramen together in the same scapula was not observed in our study. We also classified supra scapular notch on the basis of morphological appearance as U, V, and J shaped (Table 3).

**Table 3:** Showing the incidence of various types of SSN according to shape.

Sr no.	Shape of SSN	Number	Percentage
1	'U'shaped	58	46
2	'V'shaped	31	24.6
3	'J'shaped	20	15.9
4	Indentation	10	7.9
5	Absent notch	4	3.2
6	Complete ossification of STSL	3	2.4



According to this distribution the most common type of supra scapular notch found in our study was U shaped (46%), followed by V shaped in 24.6%. J shaped supra scapular notch was found only in 15.9% of scapulae in the present study. Ten scapulae (7.9%) had indentation along the superior border while in 04 scapulae (3.2%) there was no notch. Complete ossification of STSL was found in 2.4% of specimens in present study.

## DISCUSSION

Several morphological variations and classifications of SSN have been reported in various populations. Suprascapular notch is commonly bridged by superior transverse scapular ligament in living, which may sometimes get ossified. This leads to formation of suprascapular foramen which transmits the supra scapular nerve to supraspinous fossa. Various factors including variations in supra scapular notch along with the variations of superior transverse scapular ligament ossifications have been identified as being causes of SSN entrapment [14,15]. In 2007 Natis et al presented their classification distinguishing five types of supra scapular notches on the basis of relationship between the vertical and transverse diameter of the SSN and the presence or absence of both notch and foramina [10]. A further system of classification was elaborated by Polguy et al in 2010 [16]. Rengachary et al [11] classified the SSN into six types based on the inferior shape of the SSN as well as the degree of ossification of STSL. This classification was difficult to use when transition between these types is being found. The classification given by Natis et al seems to be simple and includes all the anatomical variations based on the vertical and transverse diameters of the SSN. The classification by Iqbal et al [9] also provides an easy method of distinction of SSN based on its shape (U, V, J) without involving measurements.

The results of the present study show that the most common type of SSN is type II (47.6%), a notch that is largest in its transverse diameter and the least common is Type V which was not found even in a single scapula in our study. This corresponds with the studies done by Natis et al on Greek [10] Wang et al on Chinese [13] and Lajja et al on Indian population [17] where also

the most common was Type II and least common was Type V (Table 4).

**Table 4:** Showing the comparison of the results of present study with other studies.

Sr no.	Author	Type I	Type II	Type III	Type IV	Type V
		No discrete notch	TD>VL	VL≥TD	Bony foramen	Notch & foramen
1	Natis et al. 2007 [10]	8.3	41.85	41.85	7.3	2
2	Wang et al. 2011 [13]	28	58.6	28.23	3	4
3	Lajja K et al. 2013 [17]	29	52	16	2	1
4	Present study	11.1	47.6	38.9	2.4	0

A reduction in the height of SS foramen may predispose to entrapment of suprascapular nerve. Dunkelgrun et al stated that the U shaped notches had larger area than the V shaped notch and is more likely to be associated with suprascapular nerve entrapment [18]. On Gross examination we observed that the U shaped notch was more common (46%) than the V shaped notch (24.6%) and J shaped notch (15.9%) as seen in Table 3. These observations correspond with other studies done on Indian population. Dushyant et al [19], Pragna et al [20] & Lajja et al [17] found an incidence of U shaped notch as the most common in their studies at 45%, 47.5% & 38% respectively. Iqbal et al reported the J shaped notch as the commonest (22%) in their study on the population of Pakistan [9]. The incidence of bony foramen in scapulae (the STSL was completely ossified) and SSN was closed varies from 0.3% to 13.6% [10,11,14,15].

Complete ossification of STSL differs throughout the world. In the European population it was found to be in 5-6.5% of cases, Italian-6.5%, German 7.3% & Turkish 6-12.5% [15,21,10,14]. In some population complete ossification of STSL was very rare for e.g. in Alaska Eskimos (0.3%) or Native Americans 2.1-2.9% [22, 23] whereas in other population bony foramen was even more frequent than usual. e.g. Ancient Egyptian 13.6% [23].

In the present study 2.4% incidence of complete ossification of STSL was observed which was corresponding with studies done by Wang et al [13] and Lajja et al [17] having incidence of 3 & 2% respectively. However Natis et al found an incidence of complete ossification of STSL of 7.3% in their study (Table 4). Yucesoy et al (2009)

evaluated the notch width and depth as well as the superior transverse scapular ligament in 50 volunteers by means of ultrasound and they found narrow notches in patients with supra scapular nerve entrapment syndrome [24]. Polguj et al (2011) reported that the size and shape of suprascapular notch may be a factor in supra scapular nerve entrapment [16]. Though exact cause of various shapes of SSN is not clear but Odita et al suggested that the ossifications of the coracoid process epiphysis influence the shape of the SSN and it could be the cause of the population difference [25].

In conclusion knowing the anatomical variations in detail is better for understanding of location and source of the entrapment syndrome. Although it has been documented that the supra scapular nerve entrapment is more likely to be associated with a narrow V shaped notch, no direct correlation between notch type and supra scapular nerve entrapment has been shown clinically. Therefore, rather than the shape and diameter of the notch, the morphology of the STSL has been associated with suprascapular nerve entrapment.

## CONCLUSION

The absence of SSN or reduction in the height of suprascapular foramen may predispose to entrapment of suprascapular nerve. Knowledge of anatomical variations of SSN is better for understanding location and source of entrapment syndrome. These variations should be kept in mind during surgical or arthroscopic shoulder procedures to prevent iatrogenic supra scapular nerve injuries.

## ABBREVIATIONS

**SSN** - Suprascapular notch  
**STSL** - Superior transverse scapular ligament  
**SD** - Standard deviation  
**VL** - Vertical length of Suprascapular notch  
**TD** - transverse diameter of Suprascapular notch

**Conflicts of Interests: None**

## REFERENCES

- [1]. Moore KL, Dalley AF and Agur A M, 2010. Clinical oriented anatomy. 6th ed Lippincott Williams & Wilkins, Philadelphia.
- [2]. Williams PL, Bannister LH, Bery M M et al. Gray's Anatomy. 38<sup>th</sup>ed. London Churchill- Livingstone, 2004.
- [3]. Kopell HP, Thompson WA. Pain and the frozen shoulder Surg Gynecol Obstet 1959;109:92-6.
- [4]. Antoniou J, Tae SK, Williams GR, Bird S, Ramsey MJ, Iannotti JP. Suprascapular neuropathy. Variability in the diagnosis, treatment, and outcome. Clin Orthop Rel Res. 2001;386:131-8.
- [5]. Cummins CA, Messer TM, Nuber GW. Suprascapular nerve entrapment. J Bone Joint Surg 2000;82-A:415-24.
- [6]. Edeland HG, Zachrisson BE. Fracture of the scapular notch associated with lesion of the suprascapular nerve. Acta Orthop Scand. 1975;46(758):763.
- [7]. Ferretti A, Cerullo, G, Russo G. Suprascapular neuropathy in volleyball players. The Journal of Bone Joint Surg AM. 1987;69:260-3.
- [8]. Vastamaki M, Goransson GH. Suprascapular nerve entrapment. Clin Orth Rel Res. 1993;297(135):143.
- [9]. Iqbal K, Iqbal R, Khan SG. Anatomical variations in shape of suprascapular notch of scapula. J Morphol Sci. 2010;27:1-2.
- [10]. Natsis K, Totlis T, Tsikaras P, Appell HJ, Skandalakis K. Proposal for classification of the suprascapular notch: a study on 423 dried scapulas. Clin. Anat. 2007; 20(2):135-9.
- [11]. Rengachary SS, Neff JP, Singer PA, Brackett CF. Suprascapular nerve entrapment neuropathy. A clinical, anatomical and comparative study. Part 1 Clinical study. Neurosurg. 1979;5:441-6.
- [12]. Sinkeet SR, Awori KO, Odula PO, Ogeng'o JA, Mwachaka PM. The suprascapular notch: its morphology and distance from the glenoid cavity in a Kenyan population. Folia Morphol. 2010; 69:241-245.
- [13]. Wang H, Chen C, Wu L, Pan C, Zhang W, Li Y. Variable morphology of the suprascapular notch: an investigation and quantitative measurements in Chinese population. Clin Anat. 2011; 24(1):47-55.
- [14]. Bayramoglu A, Demiryurek D, Tuccar E et al: Variations in anatomy at the suprascapular notch possibly causing suprascapular nerve entrapment: An anatomical study. Knee Surg Sports Traumatol Arthrosc 2003;11:393-398.
- [15]. Olivier G: Pratique anthropologique. Le scapulum. Paris: Vigot Freres; 1960:194-201.
- [16]. Polguj M, Je(drzejewski K, Podgórski M, Topol M: Correlation between morphometry of the suprascapular notch and anthropometric measurements of the scapula. Folia Morphol 2011;70(2):109-15.
- [17]. Lajja K Sutaria, Tushar V Nayak, Sejal V Patel, H R Jadav, CA. Pensi, Morphology and morphometric analysis of suprascapular notch; IJBAR 2013;04(01).
- [18]. Dunkelgrun M, Lesaka K, Park SS, Kummer FJ, Zuckerman JD: Interobserver reliability and intraobserver reproducibility in suprascapular notch typing. Bull Hosp Joint Dis 2003;61:118-122.
- [19]. Dushyant A, Brijendra S, Geetika AA. Human scapulae; Suprascapular notch, morphometry and variations. Indian Jour Clin Anat & Physio 2014;1(1):1-7.

- [20]. Pragna Patel, S V Patel, S M Patel, Badal Jotania, Sanjay Chavda, Dhara Patel. Study of variations in the shape of the suprascapular notch in dried human scapula. *Int J Biol Med Res.* 2013;4(2):3162-4.
- [21]. Vallois HV. L'os acromial dans les races humaine. *L'Anthropologie.* 1925;35:977-1022.
- [22]. Hrdicka A. The adult scapula: additional observations and measurements. *Am J Phys Antropol.* 1942; 29: 363-415.
- [23]. Hrdicka A. The scapula: visual observations. *Am J Phys Antropol.* 1942;29:73-94.
- [24]. Yücesoy C, Akkaya T, Özel O et al. Ultrasonographic evaluation and morphometric measurements of the suprascapular notch. *Surg Rad Anat* 2009;31: 409-14.
- [25]. Odiata JC, Ugbodaga C, Omene JA, Okolo AA. Humeral head & coracoid ossification in Nigerian new born infants. *Paediatric radiol.* 1983;13:276-8.

**How to cite this article:**

Neeta Chhabra, Suraj Prakash, MS Ahuja. MORPHOMETRY AND MORPHOLOGY OF SUPRA SCAPULAR NOTCH: IT'S IMPORTANCE IN SUPRASCAPULAR NERVE ENTRAPMENT. *Int J Anat Res* 2016;4(3):2536-2541. **DOI:** 10.16965/ijar.2016.267