

## MICROSCOPIC STUDY OF SKELETAL MUSCLE IN EMBALMED CADAVERS

Archana Kalyankar <sup>\*1</sup>, Shivaji Sukre <sup>2</sup>, Santoshkumar Dope <sup>1</sup>, Sanjog Pahade <sup>3</sup>.

<sup>\*1</sup> Associate Professor, Department Of Anatomy, Government Medical College, Aurangabad, Maharashtra, India.

<sup>2</sup> Professor and Head, Department Of Anatomy, Government Medical College, Aurangabad, Maharashtra, India.

<sup>3</sup> House Officer, Department Of Anatomy, Government Medical College, Aurangabad, Maharashtra, India.

### ABSTRACT

**Introduction:** Histology slides are prepared from animals like guinea pigs, mice etc. routinely for the purpose of teaching and research. In the department of Anatomy, cadavers are available for dissection purpose. Here, an attempt has been made to prepare the histology slides from human cadaveric tissue obtained after embalming. The aim of present study was designed to obtain skeletal muscle sample from human cadavers after embalming for the purpose of preparation of slide. The study was undertaken to see the feasibility of prepared skeletal muscle slide from human cadaver for teaching purpose and to enhance the research activity.

**Materials and Methods:** Twelve human cadavers received to the department of anatomy through body donations were selected for sample collection. The taken tissues were fixed into 10% buffered formalin, processed and stained with usual H and E staining. The prepared slide was studied and compared with the skeletal muscle slide of the guinea pig.

**Results:** Post embalmed skeletal sections are better in staining and appearance as that of guinea pig slides.

**Conclusion:** The present study was undertaken on muscle tissue with H and E staining was found to be feasible for histological study, but slides from other tissues from human cadavers by using special stains needs to be studied. There is also scope to obtain normal tissues removed from living human beings during surgical procedures for preparing histology slides after taking proper consent but needs further study of its feasibility.

**KEY WORDS:** Skeletal Muscle, Cadaver, Embalming.

**Address for Correspondence:** Dr. Archana G. Kalyankar, Associate Professor, Department Of Anatomy, Government Medical College, Aurangabad, Maharashtra, India.  
Mobile No.: +919975133601 **E-Mail:** drarchana76@yahoo.com

### Access this Article online

#### Quick Response code



DOI: 10.16965/ijar.2016.270

**Web site:** International Journal of Anatomy and Research  
ISSN 2321-4287  
[www.ijmhr.org/ijar.htm](http://www.ijmhr.org/ijar.htm)

Received: 17 Jun 2016

Peer Review: 18 Jun 2016

Revised: None

Accepted: 15 Jul 2016

Published (O): 31 Jul 2016

Published (P): 31 Jul 2016

### INTRODUCTION

We are making the histology slides from the tissues of guinea pig, mice, pig, monodelphys, rat, hamster, rabbit, dog, monkey and chicken [1,2]. For getting the tissues we sacrifice them but the histology slides obtained from animal

compared to human beings. We also get tissues from surgically removed specimen but they are unreliable source for normal histology [1]. It also has ethical issues. The histology slides are also obtained from the tissue of body came for post mortem but the tissue availed are not as fresh

as compared to that which are taken from animals. It is quite difficult to get the tissue from embalmed human cadaver for preparation of slides. The aim of present study is designed to compare the skeletal muscle tissue sample from the human cadaver after embalming for the purpose slide preparation. The study is also comparing the stained slides of skeletal muscle obtained from embalmed cadaver with that of slides we prepared usually from animal's tissue. The knowledge of histology of normal tissue is an essential requirement of establishing parameters of diagnosis of pathological conditions. This study is only the attempt to bridge the gap in the shortage of availability of histology slides for teaching purpose and to enhance the research activities.

## MATERIALS AND METHODS

The study was performed on 12 human cadavers (10 males and 2 females) received to the department of anatomy, GMC Aurangabad in the year 2015 through body donation. The age group, sex and cause of death of the cadavers were noted. The cadavers brought to department were embalmed within six hours of death with embalming fluid (10% formalin, 10% ethanol, 20% glycerin, 5% phenol, thymol crystals and Magnesium chloride) as per gravitation method [2]. As body donation is already a legal procedure, no consent was taken from the relatives. Just after embalming within an hour the skeletal muscle tissue was taken from right deltoid muscle according to prescribed precautions.

The collected sample was fixed with label in 10 % neutral buffered formalin (4% formaldehyde phosphate buffered saline). It was processed as per standard protocol. Paraffin embedding of the collected sample was done after dehydrating fixed tissue in ascending grades of alcohol solution. The clearing agent (xylene) was used which is miscible with both alcohol and paraffin to remove the alcohol. The blocks were made by melted paraffin and were allowed to cool and they were hardened to an appropriate size.

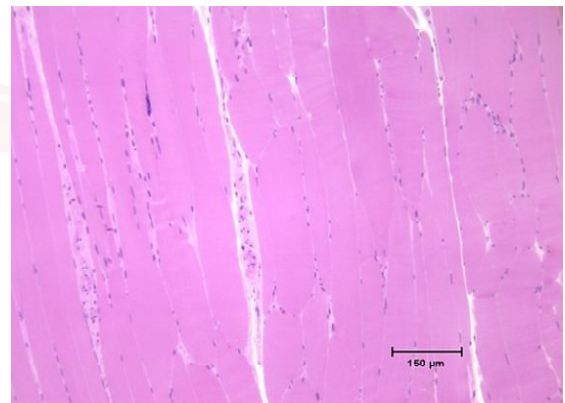
Sectioning of tissue sample was done by rotary microtome. The tissue was stained with H and E staining. To stain the tissue section the slide

was rehydrated by descending alcohol concentrations. It was stained by hematoxylin and counterstained by eosin. The specimen was mounted with the help of mounting media and covered with cover slip. The stained slide of skeletal muscle (both transverse and longitudinal section) was studied under the microscope. The same was compared with slides obtained from guinea pig.

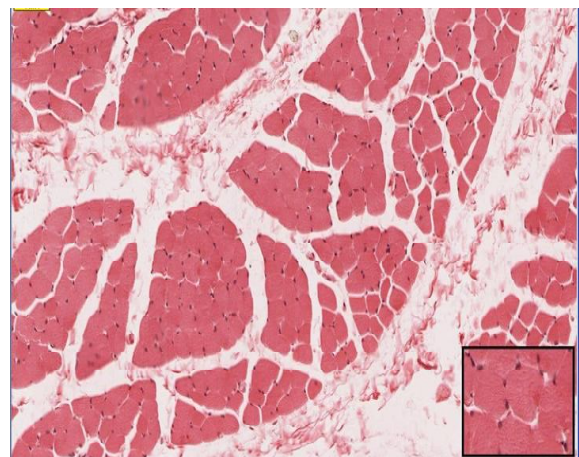
**Microanatomy of skeletal muscle:** Skeletal muscles consist of long, cylindrical fibers running parallel to each other in the bundles. The multiple nuclei are elongated and lie along the periphery of fibers just beneath the sarcolemma. The sarcoplasm contains numerous myofibrils arranged in groups called Conheim field. The striking feature is cross striations of alternate light (I) and dark bands (A). Running across each light band there is an intersection of Z line and dark band is traversed by light H zone. The part of myofibril situated between two consecutive Z line is called sarcomere [3].

## OBSERVATION AND RESULT

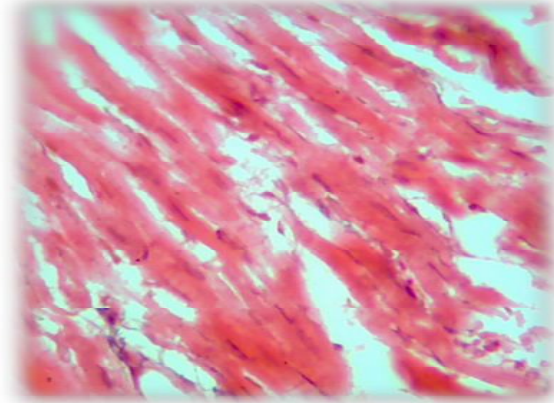
**Fig. 1:** LS Guinea Pig Skeletal Muscle (10x).



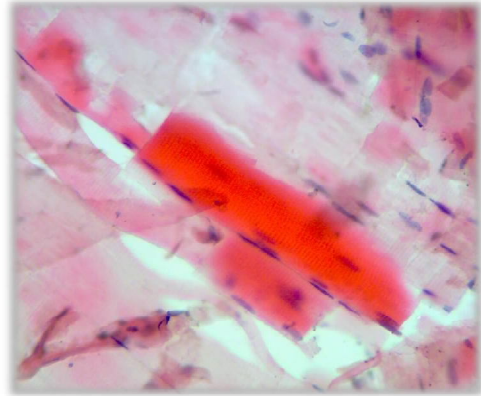
**Fig. 2:** TS Guinea Pig Skeletal Muscle (10x).



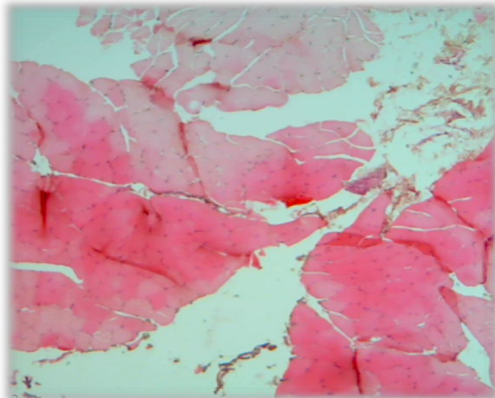
**Fig. 3:** LS Human Skeletal Muscle Low Power (10X).



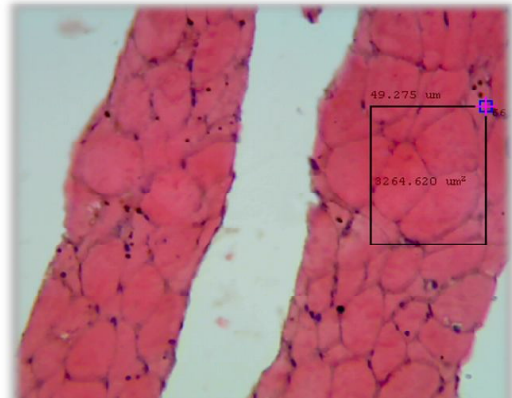
**Fig. 4:** LS Human Skeletal Muscle High Power (40X).



**Fig. 5:** TS Human Skeletal Muscle Low Power (10X).



**Fig. 6:** TS Human Skeletal Muscle High Power (40X).



The procedure undertaken for both human cadaver sample and guinea pig sample was same but the skeletal muscle sample obtained from cadaver consumed more time for paraffin embedding than the usual time required for guinea pig muscle. The cadaveric tissue was hard to cut while taking serial sections than that of guinea pig tissue. When both skeletal muscle tissues observed under the microscope the cadaveric tissue shows more artifacts than guinea pig tissue.

The other features of skeletal muscle were comparatively same as that of guinea pig tissue both in transverse and longitudinal section.

The features compared were parallel running fibers, peripherally situated multiple nuclei, alternate cross striations on high power. The size of myocyte was large as compared to guinea pig myocyte.

Figure 1 Showing LS of striated muscle. It shows longitudinally disposed muscle fibers, spindle shaped nuclei arranged longitudinally close to sarcolemma.

Figure 2 Showing TS of skeletal muscle. It shows

muscle fibers lying in the bundles. The connective tissue sheath with blood vessels and nerves form epimysium, perimysium and endomysium.

Figure 3 Showing LS of striated muscle under low power. The features seen were longitudinally disposed muscle fibers. Spindle shaped nuclei were arranged longitudinally beneath the sarcolemma.

Figure 4 Showing LS of striated muscle under high power. It shows alternate cross striations. The connective tissue is separating the muscle fibers.

Figure 5 Showing TS of striated muscle under low power. The muscle fibers were seen as irregular rounded structures with peripheral nuclei. The myofibrils were seen as the dots within the muscle fibers.

Figure 6 Showing TS of skeletal muscle under high power. The features seen were peripherally stained multiple nuclei. The size of myocyte was measured (49.275 micrometer).

## DISCUSSION AND CONCLUSION

The preparation and teaching of histological

slides is an important and integral part of undergraduate and most of the postgraduate curriculum. Cadaveric tissue is ideal source for teaching and research purpose. It does not require additional ethical clearance. In some institutes [4] it was considered a novel method of preparing a histological slide to integrate the teaching of gross and microscopic anatomy. It was done by group of UG students taking tissue samples from cadavers as a part of academic activity.

Andrew W. quoted that Chapman J.A. from university of Tasmania, Australia studied the suitability of human cadaveric tissue for the generation of Histology teaching slides. He obtained tissues such as skin, liver, pancreas, kidney, lung, lymph node and ureter from the one female and five males' embalmed cadavers. All tissues placed into 10% buffered formalin, processed, embedded into paraffin wax, sectioned and stained with H and E staining. Only certain tissues obtained from the dissected cadavers appears to be suitable for generating tissue sections and high enough quality for using them as teaching slides [5].

Nicholson H.D., Somalia L reviewed a comparison of different embalming fluids on the quality of histological preservation in human cadavers. He studied on 12 cadavers embalmed with four different formalin containing embalming fluids. The tissue blocks of liver, heart, kidney, skin and skeletal muscles were taken. They were processed and stained with H and E staining, Periodic acid Schiff based staining and Mallory trichrome. He observed no significant differences in the tissue morphology among the different stains, the clearest morphology was observed in the skin and skeletal muscle sections as tissues were embalmed with fluids which contain phenol. Phenol was added to the embalming fluid because of its fungicidal and bactericidal properties. Presence of glycerol in the embalming fluid helps the cadaver retain its natural colour [6]. In our study the skeletal muscle tissue obtained from cadavers after embalming needed less fixation time for the tissue in the embalming fluids as compared to tissue that availed from guinea pig and mice sample.

The reason may be embalming of the cadaver

added fixation properly of cadaveric tissues to preserve the morphology and chemical composition of the tissue but at the same time hardening of cadaveric tissue get doubled as that of guinea pig tissue. so the cadaveric tissue blocks prepared was getting difficulty to take serial sections [7].

At the end of slide prepared from post embalmed cadaveric tissues were having suitability for the use as teaching histology slides and for the purpose of research activities.

The aim behind the study was an attempt to overcome the shortage in procuring histology teaching slides from sacrificing guinea pig, mice and rat. The tissue obtained from forensic department at time of post mortem were crossed the time limit and difficult to rule out any pathologies [8,9]. The next venture of our study is to try to get other tissue from the post embalmed cadavers and stain them with other special staining. By doing such type of studies the anatomist will fulfill their wish of doing research on cadavers.

## ACKNOWLEDGEMENTS

I would like to acknowledge and extend my heartfelt gratitude to the following persons who have made the completion of this manuscript possible.

**Conflicts of Interests: None**

## REFERENCES

- [1]. Gupta T. and Gauba K. Cadaveric tissue histology: A viable alternative. Journal of clinical and diagnostic research 2011 DEC;5(8):1505-1509.
- [2]. Williams P L; Gray's Anatomy, 38<sup>th</sup> edition, Churchill Livingstone, Edinburgh; 1995: pp 1592-93.
- [3]. Inderbir Singh. Textbook of Human Histology; sixth edition:(123to132).
- [4]. Judy A. and Provoklimek. A novel method of preparing histology slides to integrate the teaching of gross and microscopic anatomy: J. vet. Med. Educ. 2002; (fall)29(3): 137-41.
- [5]. Andrew W. and Susan W. Histopathology from the dissecting room: are cadavers a suitable source of educationally useful histopathology specimen. International journal of experimental and clinical anatomy 2015;9(1):26-33.
- [6]. Nicholson H.D. and Samalia L. Comparison of different embalming fluid on the quality of histological preservation in human cadavers. Eur J morpho. 2005 oct-dec;42(4-5):178-84

- [7]. Uchenna N. and Ekele J. Effect of embalming fluid on histological appearance of organs from embalmed based African boat cadavers. Histologic June 13; vol XLVI No. 1:1-16.
- [8]. Alexander C.B. and Luiz A.U. Histological study of fresh vs. frozen semitendinous muscle tendon allograft. Clinics 2010;65(3):297-303.
- [9]. Richter G.T., Smith J.E., Spencer H.J., Fan C.Y., Vural E. Histological comparison of implanted cadaveric and porcine dermal matrix grafts. Pubmed: Otolaryngol Head Neck Surg. 2007 AUG; 137(2):239-42.

**How to cite this article:**

Archana Kalyankar, Shivaji Sukre, Santoshkumar Dope, Sanjog Pahade. MICROSCOPIC STUDY OF SKELETAL MUSCLE IN EMBALMED CADAVERS. Int J Anat Res 2016;4(3):2547-2551. DOI: 10.16965/ijar.2016.270

