

Case Study

ACCESSORY HEAD OF FLEXOR DIGITORUM PROFUNDUS: A CASE STUDY

Bhavya B.S *, Maheshwari Myageri, Smitha M.

Tutor, Department of Anatomy, Karnataka Institute Of Medical Sciences, Hubli, Karnataka, India.

ABSTRACT

Background: In 1813 Gantzer described 2 accessory muscles in the human forearm which bear his name, accessory head of flexor digitorum profundus and accessory head of flexor pollicis longus. The less frequently observed was accessory head of flexor digitorum profundus and hence this study was conducted.

Materials and Methods: 25 formalin-fixed cadavers (50 upper limbs) were dissected as per the standard methods. Detailed study of origin, insertion of accessory heads of flexor digitorum profundus muscle and various other parameters were recorded.

Results: Two out of fifty upper limbs (4%) were observed to have accessory head of flexor digitorum profundus. Origin and insertion of each case was different but all got its innervation through direct branch from Median nerve.

Conclusion: Accessory heads of flexor digitorum profundus may cause various syndromes and its knowledge of existence is important for surgeons operating in forearm.

KEY WORDS: Accessory head of flexor digitorum profundus, pronator teres, coronoid process of ulna, median nerve, ulnar artery, carpal tunnel syndrome.

Address for Correspondence: Dr. Bhavya B.S., Tutor, Department of Anatomy, Karnataka Institute of Medical Sciences, Hubli – 580021, Karnataka, India. Mobile: 09845197705

E-Mail: dr.bhavyabs1984@gmail.com

Access this Article online

Quick Response code



DOI: 10.16965/ijar.2016.376

Web site: International Journal of Anatomy and Research
ISSN 2321-4287
www.ijmhr.org/ijar.htm

Received: 18 Aug 2016
Peer Review: 18 Aug 2016
Revised: None

Accepted: 29 Sep 2016
Published (O): 31 Oct 2016
Published (P): 31 Oct 2016

INTRODUCTION

Flexor digitorum profundus is one of the deep muscles of anterior compartment of forearm. Flexor digitorum profundus arises deep to the superficial flexors from about the upper three-quarters of the anterior and medial surfaces of the ulna. It also arises from a depression on the medial side of the coronoid process, the upper three-quarters of the posterior ulnar border and the anterior surface of the ulnar half of the interosseous membrane. About halfway down the forearm four tendons are formed, although only that to index finger

appears to be separate. The tendons for the other fingers are interconnected by areolar tissue and tendinous slips as far as the palm. Anterior to their proximal phalanges, the tendons pass through the tendons of flexor digitorum superficialis to insert on the palmar surfaces of the bases of the distal phalanges. The tendons of the profundus undergo fascicular rearrangement as they pass through those of superficialis. The medial part of flexor digitorum profundus, i.e. the muscle bellies to the little and ring fingers, is innervated by the ulnar nerve. The lateral part, i.e. the muscle bellies to the middle and index fingers, is inner

vated by the anterior interosseous branch of the median nerve. Flexor digitorum profundus may be joined by accessory slips from the radius, flexor digitorum superficialis, flexor pollicis longus, the medial epicondyle or the coronoid process [1,2].

During the fourth week of development somatic mesoderm invades the limb buds and forms ventral and dorsal condensations. The ventral condensation gives rise to flexors and pronators of the upper limb [3]. The flexor muscles of the forearm that develop from flexor mass divide into 2 layers, superficial and deep. The Flexor digitorum superficialis, Flexor pollicis longus & Flexor digitorum profundus originate from deep layer. The existence of accessory muscles connecting the flexor muscles could be explained by the incomplete cleavage of the deep layer of the flexor mass during development, which represents an atavistic character [4-6].

Variations in muscles of the extensor compartment of forearm are quite common, however in flexor compartment not many variations are noted and occurrence of an additional muscle is very uncommon [7]. In 1813 Gantzer described 2 accessory muscles in the human forearm which bear his name, accessory head of flexor digitorum profundus and accessory head of flexor pollicis longus. The less frequently observed was accessory head of flexor digitorum profundus [4] and hence this study was conducted.

The muscular variations in the forearm have been recognized as causing neurovascular compressions. These variations are mostly detected during routine anatomical dissections or during operations. A clinician should have a thorough knowledge of these variations for understanding the unusual symptoms and signs due to nerve compression [8]. An anomalous muscle may simulate a ganglion or a soft tissue tumour or in close proximity to nerve, it may cause pressure symptoms such as carpal tunnel syndrome. Wrist is a common site for tendon injuries and presence of aberrant tendon in this region can mislead the surgeons during identification and repair of such injuries [7].

MATERIALS AND METHODS

This study was conducted on 25 formalin-fixed cadavers (50 upper limbs) irrespective of age and

sex were dissected as per the standard methods, over a period of 3 years (from 2010-2013). After being partly dissected by medical students, they were further dissected with reflection or removal of superficial muscles of the front of forearm. The forearm were examined to check for existence of accessory head of flexor digitorum profundus. Detailed study of origin, insertion and presence of accessory heads of flexor digitorum profundus muscle was observed. Careful isolation of variant heads of flexor digitorum profundus was done, their proximal and distal attachments were made clear. In addition to their pattern of innervations, shape were also recorded.

Following measurements were taken:

Total length of the accessory head.

Length of muscular part.

Length of tendinous part.

Maximum width.

RESULTS

Two out of fifty upper limbs (4%) were observed to have accessory head of flexor digitorum profundus. The accessory head of flexor digitorum profundus was seen in one right limb of male cadaver (2%) and one left limb of female cadaver (2%).

The accessory head of flexor digitorum profundus in right forearm took origin from the tendinous slip of ulnar head of pronator teres and coronoid process of ulna, in common with the origin of flexor digitorum superficialis. Whereas the accessory head of flexor digitorum profundus in left forearm took origin only from coronoid process of ulna, in common with the origin of flexor digitorum superficialis.

The accessory head of flexor digitorum profundus in right forearm crossed superficial to ulnar artery and was inserted in the middle of forearm, to tendon of flexor digitorum profundus for middle, ring & little finger.

The accessory head of flexor digitorum profundus in left forearm crossed superficial to ulnar artery and was inserted to tendon of flexor digitorum profundus for middle finger on its radial side near wrist joint. Both accessory head of flexor digitorum profundus were innervated by a direct branch from median nerve.

Fig. 1: Shows attachment of Accessory Head of Flexor Digitorum Profundus in right forearm.

FDP - Flexor Digitorum Profundus,
FDPah - Accessory Head of Flexor Digitorum Profundus ,
MN - Median nerve, PTu - Ulnar Head of Pronator Teres,
UA - Ulnar artery.

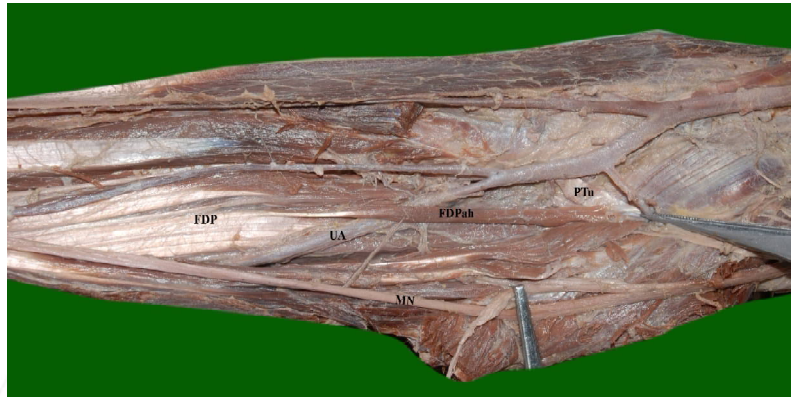


Fig. 2: Showing nerve supply to Accessory Head of Flexor Digitorum Profundus by a branch from median nerve in right forearm.

FDP - Flexor Digitorum Profundus ,
FDPah - Accessory Head of Flexor Digitorum Profundus ,
MN - Median nerve, PTu - Ulnar Head of Pronator Teres,
UA - Ulnar artery.



Fig. 3: Shows Accessory Head of Flexor Digitorum Profundus in left forearm.

FDP - Flexor Digitorum Profundus ,
FDPah - Accessory Head of Flexor Digitorum Profundus ,
MN - Median nerve,
UA - Ulnar artery.



The accessory head of flexor digitorum profundus in right forearm showed the following measurements. The total length of the accessory head was 106mm, out of which the proximal muscular part was 72mm and distal tendinous part was 34mm. It was slender in shape with maximum width of 4mm. All the muscular components of the left forearm were normal.

The accessory head of flexor digitorum profundus in left forearm showed the following measurements .The total length of the accessory head was 145mm, out of which the proximal muscular part was 54mm and distal tendinous part was 91mm. It was slender in

shape with maximum width of 4.2mm. All the muscular components of the right forearm were normal.

DISCUSSION

Table1: Comparison of prevalence percentage of accessory head of flexor digitorum profundus by various authors.

Authors	Prevalence	Male	Female	Right	Left
Wood	18.60%	11%	16.70%	-	-
Mangini	2.90%	-	-	-	-
Kida	35.20%	-	-	-	-
Jones et al [4]	27.5% (80)	12.50%	15%	25%	4.20%
El Domiaty [3]	14.24% (84)	-	-	NO	25%
Our Study	4%	-	-	2%	2%

In 1813, Gantzer described two accessory muscles in the forearm. The less frequent of the two accessory muscles was accessory head of flexor digitorum profundus.[4]

Many authors have described the origin from coronoid process, which coincided with one of our specimen of accessory head of flexor digitorum profundus on left forearm. Jones et.al. noted 1/15 cases with origin from pronator teres, whereas in our study accessory head took origin from pronator teres as well as coronoid process of ulna [3,4].

Jones et.al. described that the tendon of accessory head ended near the level of the wrist, in one of our case it was same but in other case it ended in the middle of forearm and got inserted into one of the tendons of flexor digitorum profundus [4].

Macalister has mentioned 9 different possible combinations of insertion via 1, 2 or 3 slips. Among them we observed that tendon of accessory head in right limb got inserted to tendon of middle, ring, little finger & in left limb to tendon of middle finger [4].

A muscular slip arising from the coronoid process and ending by a long tendon on one or another (usually the index or middle) of the tendons of the muscle has been reported in about 20% of bodies. Mori reported 40% in his subjects. In our study we observed similar course of accessory head of Flexor digitorum profundus in 2% of cases [9].

Various authors have described the nerve supply to be originating from the median nerve [3,7,10] which is same in our case study.

Table 2: Comparison of measurements of accessory head of flexor digitorum profundus seen in various studies.

Measurements	Length	Muscular Part	Tendinous Part
El domiaty [3]	208.33mm	83.33mm	125mm
Jones et al [4]	161.5mm	67mm	107.4mm
Nayak et al [5]	152mm	55mm	97mm
Rakesh et al [13]	239mm	72mm	167mm
Kopuz et.al [10]	175mm	80mm	95mm
Present study (right)	106mm	72mm	34mm
Present study (left)	145mm	54mm	91mm

Many authors have mentioned that during its course, accessory head crossed over the ulnar

artery & on the ulnar side of the anterior interosseous nerve which coincided with our case study [4].

The shape of gantzer's muscle has been described as fleshy and fusiform or either fusiform or flat slip but in our study they were slender as described by Jones [4].

CONCLUSION

In our present study we found two accessory heads of flexor digitorum profundus among 50 forearm specimens which signify its rare incidence. Both cases were different with respect to its attachments but both crossed ulnar artery which could cause vascular compression. Such variations may cause nerve compression causing pronator syndrome, anterior interosseous nerve syndrome or carpal tunnel syndrome. They may also present as enlarging tumor-like mass simulating a ganglion and hence it is of great importance to orthopedicians, surgeons & radiologists.

Conflicts of Interests: None

REFERENCES

- [1]. Standring S. Gray's Anatomy - The anatomical basis of clinical practice. 40th ed. London: Elsevier Churchill Livingstone; 2008:847-848.
- [2]. Hollinshead HW. Anatomy for surgeons. 2nd edition, vol 3. Philadelphia: Harper and Row; 1969:408-409.
- [3]. El Domiaty MA, Zoair MM, Sheta AA. The prevalence of accessory heads of the flexor pollicis longus and the flexor digitorum profundus muscles in Egyptians and their relations to median and anterior interosseous nerves. Folia Morphol 2008;67(1):63-71.
- [4]. Jones M, Abrahams PH, Sanudo JR, Campillo M. Incidence and morphology of accessory heads of flexor pollicis longus and flexor digitorum profundus (Gantzer's muscles). J Anat 1997;191:451-455.
- [5]. Nayak SR et.al. Multiple muscular anomalies of upper extremity: a cadaveric study. Romanian Journal of Morphology and Embryology 2008;49(3):411-415.
- [6]. Vollala et.al. Multiple accessory structures in the upper limb of a single cadaver. Singapore Med J 2008;49(9):e254-e258.
- [7]. Rodrigues V et.al. Abnormal muscle in the anterior compartment of the forearm: a case report. Cases journal 2009;2:9125.

- [8]. Kumar S, Verma R, Mehra RD. An anomalous origin of accessory head of flexor digitorum profundus in forearm: A rare variant. Journal of anatomical society of india. 2016, DOI: 10.1016/j.jasi. 2016. 04.001.
- [9]. Bergman RA, Afifi AK, Miyauchi R. Illustrated Encyclopedia of Human Anatomic Variation: Opus I: Muscular System: Alphabetical listing of muscles: F [cited 2016 july 21]. Available from: <http://www.anatomyatlases.org/AnatomicVariants/MuscularSystem/Text/F/16Flexor.shtml>[10]. Kopuz C, Fidan B, Islam A. An unusually distal and complete additional flexor profundus muscle to the index finger. J Anat 1997;199:465-467.
- [11]. Narayana K, Narendiran K, Prakash KS, Prashanthi N. A case of coexistence of three anatomical variations in the forearm: Ganzer's muscles, Martin – Gruber anatomosis and nerve of Henle. Eur J Anat 2004;8(2):81-84.
- [12]. Nayak SR, Ramanathan L, Prabhu LV, Raju S. Additional flexor muscles of the forearm: case report and clinical significance. Singapore Med J 2007;48(8):e231-e233.
- [13]. Rakesh GV et.al. Rare origin of two accessory bellies from the undersurface of flexor digitorum superficialis muscle. Eur J Gen Med 2009;6(1):57-59.
- [14]. Jones M, Abrahams PH. Case report: accessory head of the deep forearm flexors. J Anat 1997;191:313-314.

How to cite this article:

Bhavya B.S, Maheshwari Myageri, Smitha M. ACCESSORY HEAD OF FLEXOR DIGITORUM PROFUNDUS: A CASE STUDY. Int J Anat Res 2016;4(4):2931-2935. DOI: 10.16965/ijar.2016.376