

## MORPHOLOGICAL STUDY OF THE MENISCOFEMORAL LIGAMENTS

Geetharani BG <sup>\*1</sup>, Betty Anna Jose <sup>1</sup>, Shashirekha M <sup>2</sup>, Varsha Mokhasi <sup>3</sup>.

<sup>\*1</sup> Assistant Professor, Department of Anatomy, Vydehi Institute of Medical Sciences and Research Centre, Bengaluru, Karnataka, India.

<sup>2</sup> Professor, Department of Anatomy, Vydehi Institute of Medical Sciences and Research Centre, Bengaluru, Karnataka, India.

<sup>3</sup> Professor and Head, Department of Anatomy, Vydehi Institute of Medical Sciences and Research Centre, Bengaluru, Karnataka, India.

### ABSTRACT

**Background:** A thorough understanding on the support or restraint system of knee joint is of significant importance considering the stress and strain imparted to it as man adopted the erect posture and performed various movements during evolution. The main support of knee joint is formed by collateral and cruciate ligaments. Secondary supports are formed by meniscofemoral, transverse meniscal and coronary ligaments. This study is endeavoured to understand the meniscofemoral ligaments and their attachments in cadavers belonging to south Indian population.

**Material and Methods:** This study was conducted in the Department of Anatomy, Vydehi institute of medical sciences, Bengaluru. Knee joints were studied in 40 human adult cadavers aged above 50 years. Menisco femoral ligaments and cruciate ligaments were dissected and exposed. All their attachments, length and mid width measurements were noted.

**Results:** Anterior menisco femoral ligament alone was seen in 12.5 % of knee joints, posterior menisco femoral ligament alone was seen in 30 % of knee joints and both ligaments were present in 37.5%. Both ligaments were absent in 20% of knee joints. Average length of posterior menisco femoral ligament was 2.02 centimetres and its mid width was 0.95 centimetres. Average length of anterior menisco femoral ligament was 2.79 centimetres and its width was 1.27 centimetres. Posterior menisco femoral ligament was more prevalent and larger than anterior menisco femoral ligament in aged cadavers.

**Conclusions:** This study shows the predominance of posterior meniscofemoral ligaments in its incidence and morphometrics compared to anterior meniscofemoral ligaments. Meniscofemoral ligaments degenerate with age and among them anterior meniscofemoral ligaments degenerate earlier than posterior meniscofemoral ligaments.

**KEY WORDS:** Knee Joint, Meniscofemoral Ligament, Cruciate Ligament.

**Address for Correspondence:** Dr. Geetha Rani B.G, Senior tutor, Department of Anatomy, Vydehi Institute of Medical Sciences and Research Centre, Bengaluru – 560066, Karnataka, India.

**E-Mail:** [lalithgeetha246@gmail.com](mailto:lalithgeetha246@gmail.com)

### Access this Article online

#### Quick Response code



DOI: 10.16965/ijar.2016.418

**Web site:** International Journal of Anatomy and Research  
ISSN 2321-4287  
[www.ijmhr.org/ijar.htm](http://www.ijmhr.org/ijar.htm)

Received: 27 Sep 2016  
Peer Review: 28 Sep 2016  
Revised: None

Accepted: 02 Nov 2016  
Published (O): 30 Nov 2016  
Published (P): 30 Nov 2016

### INTRODUCTION

Knee joint is a complex synovial joint, supported

by capsule, primary and secondary ligaments.

Primary supports of knee joints are medial

Knee joint is a complex synovial joint, supported collateral ligament, lateral collateral ligament and cruciate ligaments. Secondary supports are menisco femoral ligaments, transverse meniscal ligament and coronary ligament. Among them Menisco femoral ligaments (MFL) connect the posterior horn of lateral meniscus to inner (lateral) aspect of medial femoral condyle. They are named in relation to their position with posterior cruciate ligament (PCL). The anterior menisco femoral ligament (aMFL) is also called as ligament of Humphrey (Sir George Murray Humphrey, English anatomist) passes anterior to posterior cruciate ligament. The posterior menisco femoral ligament (pMFL) also called as ligament of Wrisberg (Sir Heinrich August Wrisberg, German anatomist) passes posterior to posterior cruciate ligament [1]. A little or no mentions of these ligaments are made in some anatomical text books. Previously little was described on meniscofemoral ligaments but of late increasing number investigations are done to elucidate the signs of menisco femoral ligament.

During MRI on knee joint, MFL is best seen on sagittal views, although occasionally Wrisberg ligament can also be seen on coronal views. During arthroscopy aMFLs are often confused for PCL but they can be differentiated by meniscal tug test.

MFLs increase the congruity between the mobile lateral meniscus and lateral femoral condyle. They perform a protective role for posterior horn of lateral meniscus. Support the posterior cruciate ligament in minimising displacement caused by posteriorly directed forces on tibia. They are involved in controlling the motion of lateral meniscus in conjunction with tendon of popliteus during knee flexion. They have reciprocal and non isometric tensioning pattern. The aMFL is taut during flexion and lax during extension. The pMFL is taut during extension and lax during flexion. MFLs could act as a splint during injuries of posterior cruciate ligament reconstruction giving the proper time for conservative healing [2].

Since, the incidence of MFLs reduces with age as they degenerate with age. The attachments of menisco femoral ligaments are a source of uncertainty and are often confused for poste-

rior cruciate ligament during arthroscopy and during MRI imaging [3,4]. Therefore, this study was interested in finding the incidence of MFLs and their attachments in embalmed human cadaveric lower limbs.

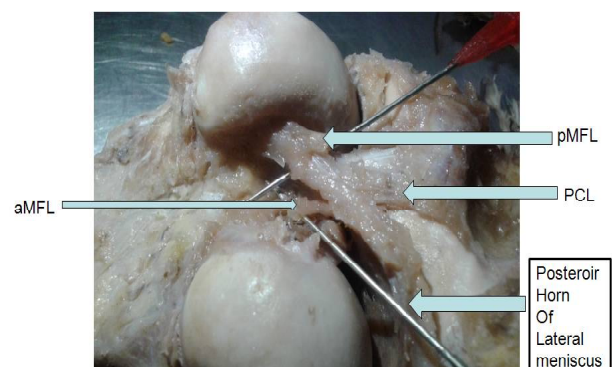
## MATERIALS AND METHODS

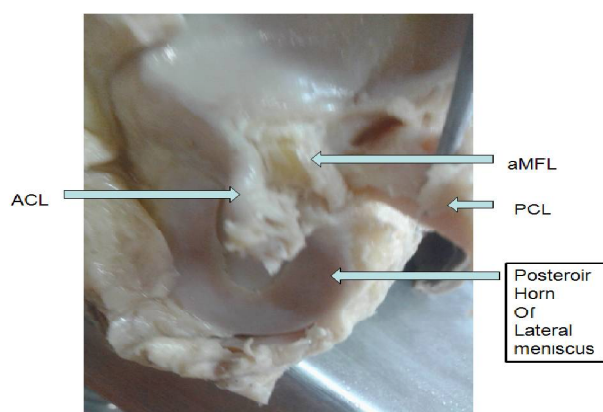
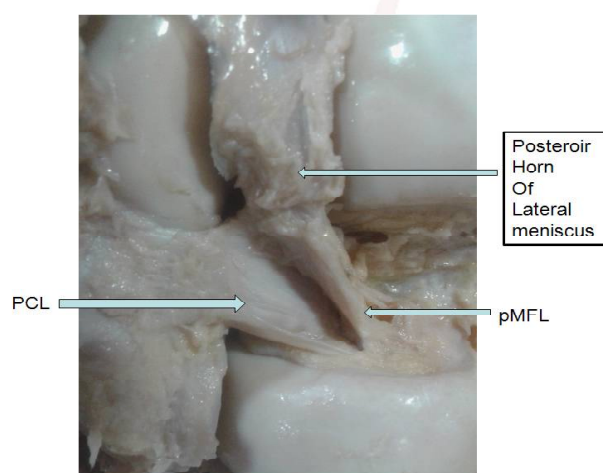
Forty embalmed human cadaveric lower limbs of age above 50 yrs were obtained from Department of anatomy, Vydehi institute of medical sciences, Bengaluru. For exposing aMFL, the lower limb is kept in an extended position. A longitudinal inverted 'U' incision done around the patella reflected upwards. Later lower limb was flexed to expose the anterior cruciate ligament (ACL). ACL was detached from its femoral attachments to reach for aMFL. Its presence, length and mid width measurements were noted using digital vernier callipers. For exposing pMFL, the lower limb was kept in prone position, all the muscular attachments and vessels and nerves were reflected aside on popliteal fossa, a similar 'U' shaped longitudinal incision was done and the capsule was carefully reflected over to look for pMFL, its presence, length and mid width was noted.

## RESULTS

Posterior menisco femoral ligaments arose as a single thick band from posterior horn of lateral meniscus a little lateral to its tibial attachment. It continued obliquely upwards medially to insert into the lateral aspect of medial femoral condyle slightly posterior and inferior to insertion of posterior cruciate ligament (figure 1 and 3). Few cases showed variation in their attachments. In 6 specimens Posterior menisco femoral ligaments fibres blended with PCL, in one specimen, they inserted to intercondylar area.

**Fig. 1:** Showing both the meniscofemoral ligaments.



**Fig. 2:** Showing anterior meniscofemoral ligament.**Fig. 3:** Showing posterior menisco femoral ligament.**Table 1:** Shows the presence of menisco femoral ligaments in right and left lower limbs.

	Right n=20	Left n=20	Total n=20
Presence of both MFLs	12	3	15 (37%)
Presence of aMFL only	0	5	5 (12%)
Presence of pMFL only	4	8	12 (30%)
Absence of both MFLs	4	4	8 (20%)

**Table 2:** Shows the length of menisco femoral ligaments in right and left lower limbs.

	Right	Left	Combined
Average length of aMFL	1.8 cms	2.24 cms	2.02
Average Mid circumference of aMFL	1cmsq	0.9 cmsq	0.95
Average length of pMFL	3 cms	2.58 cms	2.79
Average Mid circumference of pMFL	1.30 cmsq	1.24 cmsq	1.27

Anterior menisco femoral ligament also arose as a single but thin band from posterior horn of lateral meniscus. It continued obliquely upwards to insert into the lateral aspect of medial femoral condyle slightly anterior and inferior to insertion of posterior cruciate ligament (figure 1 and 2). This ligament was also varying its attachments (bilamellae). In 1 specimen it had two bands which finally got inserted to lateral part of medial femoral condyle. In 5 specimens few

fibres blended with anterior cruciate ligament.

The incidence of aMFL and pMFL is shown in tables 1. It shows that the incidence of pMFL (30%) was more than the aMFL (12%). The length of menisco femoral ligaments in right and left lower limbs are shown in table 2. It can be seen that pMFL had more length and mid circumference.

## DISCUSSION

In 1892 Poirier and Charpy first described menisco femoral ligaments and published it later. Initially it was mistakenly named as 3<sup>rd</sup> cruciate ligament. Naming these structures as ligament is a misnomer as these connect menisci to bone instead of bone to bone [5].

**Embryology:** During last 10 days of embryonic period the knee joint and its associated structures arise from the blastemal inter zone and develop in situ with out any evidence of migration development of Wrisberg is seen at o"rahiely stage 21.

Le Minor JM et al noted that pMFLs always present in animals such as sheep, horse and dog. It is sometimes absent in man. There are no reports of description of aMFLs animals. He concluded that in man pMFL is a regressive structure while aMFL is progressive. However this was not supported by this study, where none of the leg specimen had only aMFL [6].

Poynton AR et al in his studies on MFLs held that pMFLs tend to be larger than aMFLs. They noticed that aMFLs if present was often blended with PCL. But in this study it was noticed that aMFL was blending with ACL [7]. Gupte et al conclude that MFLs control the move of post horn of left during flexion of knee and this their MFL become tense during extension to pull the post horn anterior and medially. They also said that MFLs antagonise the distal posterior horn anterior and medially. Last et al in his studies hypothesised that MFLs and popliteus together protect the lateral meniscus from tears by their attachment [8]. Kimura M et al in his studies said that in surgical repairs of meniscal tears, if alongside MFLs are not repaired there is an associated increased recurrence of meniscal tears [9]. Ikeuchi H et al however contradicted by saying that he could not find any interrelation between MFLs and lateral meniscus [10].



Watanabe AT et al studied MRI of MFLs and commented that they can be mistaken for a pseudo tear of lateral meniscus. This may be because of parallel course of two parts of MFLs near their insertion into posterior horn of lateral meniscus. This study also showed similar finding in one of the specimen [11]. Yamamoto Y et al studied 100 knees and showed menisco femoral ligaments draw posterior horn of lateral meniscus in anterior, medial and superior direction during flexion of knee joint. Thus it helps in maintaining the congruency between femoral condyles and lateral meniscus and increase the overall stability of knee joint [12]. Gupte CM et al also said the same.

Kaplan PA proposed that aMFL originate from pMFL as its anterior branch. But in this study, most of the tim aMFL and pMFL arose as two separate structures though from posterior horn of lateral meniscus. aMFL arose as a single thin band from posterior horn of lateral meniscus [13]. Wan AC et al found 93% pmfl and 33% of aMFLs. He also suggested renaming MFLs as pre cruciate pmfl and post cruciate posterior menisco femoral ligaments as the anterior horns of both menisci were also attached to the intercondylar area by anteromedial and anterolateral menisco femoral ligaments separate from anterior cruciate ligament. He also said that because posterior horn of medial meniscus had no femoral attachment it was prone for injury [14].

Nagasaki S et al found an aMFL incidence of 36.8%, pMFL incidence of 71% and both ligaments seen in 26.7% cases. It was also concluded that MFLs contribute significantly to cross section area of posterior cruciate ligament [15]. Harner CD et al regarding morphometrics of MFLs said that they were more circular than cruciate ligament and sometimes just similar to posterior cruciate ligament showed mediolateral widening. Menisco femoral ligaments cross section area was approximately found to be 22% of posterior cruciate ligament. This study showed more mediolateral widening than being circular [16].

Finally, this study shows the predominance of pMFL in its incidence and morphometrics compared to aMFL. MFLs degenerate with age and among them aMFL degenerate earlier than pMFL.

## CONCLUSION

Being an incongruent joint by nature of its articular surfaces, knee joint is made indispensable to man by its great supportive ligaments, muscles and with menisco femoral ligaments being part of them. This makes appreciation and understanding morphology of these ligaments of great help to orthopaedicians and radiologists. With this study on cadavers with age above 50 years, it was found that there is predominance of pMFL in its incidence and morphometrics compared to aMFL. This study infers from theses studies MFLs degenerate with age and among the two aMFL degenerate earlier than pMFL. Yet further studies are advocated to correlate role of MFLs degenerating menisci or cruciate ligaments.

**Conflicts of Interests: None**

## REFERENCES

- [1]. Amis AA, Gupte CM, Bull AM, Edwards A. Anatomy of the posterior cruciate ligament and the meniscomfemoral ligaments. *Knee Surgery, Sports Traumatology, Arthroscopy*. 2006 Mar 1;14(3):257-63.
- [2]. Gupte CM, Smith A, McDermott ID, Bull AM, Thomas RD, Amis AA. Meniscomfemoral ligaments revisited. *Bone & Joint Journal*. 2002;84(6):846-51.
- [3]. Anderson CJ, Ziegler CG, Wijdicks CA, Engebretsen L, LaPrade RF. Arthroscopically pertinent anatomy of the anterolateral and posteromedial bundles of the posterior cruciate ligament. *J Bone Joint Surg Am*. 2012 Nov 7;94(21):1936-45.
- [4]. Vahey TN, Bennett HT, Arrington LE, Shelbourne KD, Ng J. MR imaging of the knee: pseudotear of the lateral meniscus caused by the meniscomfemoral ligament. *AJR. American journal of roentgenology*. 1990 Jun; 154(6):1237-9.
- [5]. Poirier A, Charpy *Traite d'Anatomie Humaine*, Masson, Paris (1912) p. 270-6
- [6]. Le Minor JM. Comparative morphology of the lateral meniscus of the knee in primates. *Journal of anatomy*. 1990 Jun;170:161.
- [7]. Poynton AR, Javadpour SM, Finegan PJ, O'Brien M. The meniscomfemoral ligaments of the knee. *Bone & Joint Journal*. 1997 Mar 1;79(2):327-30
- [8]. Last R. The popliteus muscle and the lateral meniscus. *J Bone Joint Surg [Br]* 1950;32-B:93-9.
- [9]. Kimura M, Shirakura K, Hasegawa A, Kobayashi Y, Udagawa E. Anatomy and pathophysiology of the popliteal tendon area in the lateral meniscus: 2: clinical investigation. *Arthroscopy* 1992;8:424-7
- [10]. Ikeuchi H. Arthroscopic Treatment of the Discoid Lateral Meniscus Technique and Long-term Results. *Clinical orthopaedics and related research*. 1982 Jul 1; 167:19-28.

- [11]. Watanabe AT, Carter BC, Teitelbaum GP, Seeger LL, Bradley WG. Normal variations in MR imaging of the knee: appearance and frequency. American Journal of Roentgenology. 1989 Aug 1;153(2).
- [12]. Yamamoto Y, Hsu WH, Woo SL, Van Scyoc AH, Takakura Y, Debski RE. Knee stability and graft function after anterior cruciate ligament reconstruction a comparison of a lateral and an anatomical femoral tunnel placement. The American journal of sports medicine. 2004 Dec 1;32(8):1825-32.
- [13]. Kaplan PA, Walker CW, Kilcoyne RF, Brown DE, Tusek D, Dussault RG. Occult fracture patterns of the knee associated with anterior cruciate ligament tears: assessment with MR imaging. Radiology. 1992 Jun;183(3):835-8.
- [14]. Wan AC, Felle P. The menisco-femoral ligaments. Clin Anat 1995; 8:323-6.
- [15]. Nagasaki S, Ohkoshi Y, Yamamoto K, Ebata W, Imabuchi R, Nishiike J. The incidence and cross-sectional area of the meniscomfemoral ligament. The American journal of sports medicine. 2006 Aug 1;34(8):1345-50.
- [16]. Harner CD, Xerogeanes JW, Livesay GA, et al. The human posterior cruciate ligament complex: an interdisciplinary study: ligament morphology and biomechanical evaluation. Am J Sports Med 1995;23:736-45

**How to cite this article:**

Geetharani BG, Betty Anna Jose, Shashirekha M, Varsha Mokhasi. MORPHOLOGICAL STUDY OF THE MENISCOFEMORAL LIGAMENTS. Int J Anat Res 2016;4(4):3129-3133. DOI: 10.16965/ijar.2016.418