

MORPHOMETRIC STUDY OF THIRD WEB SPACE BRANCH OF MEDIAN NERVE: ITS CLINICAL IMPLICATIONS ON NERVE GRAFTING

Raviprasanna.K.H ^{*1}, Anand L Kulkarni ², Aditya Krishna Das ³.

^{*1} Assistant Professor, Department of Anatomy, Sree Narayana Institute of Medical Sciences, North Kuthiathode, Chalakka, Ernakulam, Kerala, India.

² Professor and Head, Department of Anatomy, Sree Narayana Institute of Medical Sciences, North Kuthiathode, Chalakka, Ernakulam, Kerala, India.

³ Assistant Professor, Department of Anatomy, Sree Narayana Institute of Medical Sciences, North Kuthiathode, Chalakka, Ernakulam, Kerala, India.

ABSTRACT

Background: Nerve injuries are more common in superior extremities because of trauma and can lead to motor & sensory deficits and development of intractable pain. Cutaneous nerves can be harvested for grafting to bridge the gap created by injuries.

Purpose of the study: To know the available length of third webspace branch of median nerve for nerve grafting.

Materials and Methods: The study included 33 human cadaver upper limb specimens from Department of Anatomy, Sree Narayana Institute of Medical Sciences, Ernakulam. The specimens were fixed with 10% neutral buffered formalin solution and the third webspace branch of median nerve was measured.

Results: In the present study we observed that the mean length available for grafting from distal end of flexor retinaculum to the webspace is 6.45 cm with the range of 4.5 cm to 7.57 cm.

Conclusion: The present study has revealed the length of third webspace branch of median nerve which can be used for bridging the gap in ulnar nerve injury in the hand or median nerve injury in 1st webspace.

KEY WORDS: Median nerve, Grafting, Peripheral nerve injuries, Webspace.

Address for Correspondence: Dr. Raviprasanna. K. H, Assistant Professor, Department of Anatomy, Sree Narayana Institute of Medical Sciences, North Kuthiathode, Chalakka, Ernakulam, Kerala - 683594. Phone no- +919496752619 Fax No- 91484-2478093.

E-Mail: pravi_kh81@yahoo.in / pravikh8124@gmail.com

Access this Article online

Quick Response code



DOI: 10.16965/ijar.2016.447

Web site: International Journal of Anatomy and Research
ISSN 2321-4287
www.ijmhr.org/ijar.htm

Received: 21 Oct 2016
Peer Review: 21 Oct 2016
Revised: None

Accepted: 28 Nov 2016
Published (O): 31 Dec 2016
Published (P): 31 Dec 2016

BACKGROUND

Peripheral nerve injuries are more common in superior extremity mainly due to traumatic causes [1]. Nerve injuries can have a devastating impact on patient's quality of life. Typical symptoms are due to loss of sensation or due to paralysis of muscles or development of intrac-

table neuropathic pain [2]. Many injuries require surgical nerve reconstruction [3]. The primary goal of nerve repair is to allow reinnervation of the affected organ [4]. Nerve injuries occurred 81% of the time in the upper extremities and 11% in the lower extremities, with the balance in other locations [5].

Some nerve injuries require external intervention in order to regain the nerve functions. Commonly used procedure is to suture the 2 ends of the injured nerve. If a large segment of the nerve is damaged or the injured nerve has developed painful neuroma at the site of lesion then it is required to bridge the gap [nerve grafting] using nerve of relatively less importance. Most of the donor nerves are supplying the skin [cutaneous], lie immediately underneath skin and can be removed easily, without creating major unsustainable damage. Recipient nerves vary according to the site of injury but there are only few nerves that could be used as donor nerves. To have better prognosis, knowledge regarding length of donor nerves available for grafting is required. Nerves are made up of long cytoplasmic extensions called axons which start from the nerve cells [neurons] located mainly in brain or spinal cord. Axons are grouped together in spatially arranged motor or sensory bundles called fascicles. Median nerve in the hand divides into lateral and medial ramus at the distal border of flexor retinaculum. The medial ramus subdivides into two common palmar digital nerves which supply adjacent sides of index, middle and ring fingers. Medial common digital branch supplies the third web space formed by adjacent sides of middle & ring fingers by dividing into proper digital nerves.

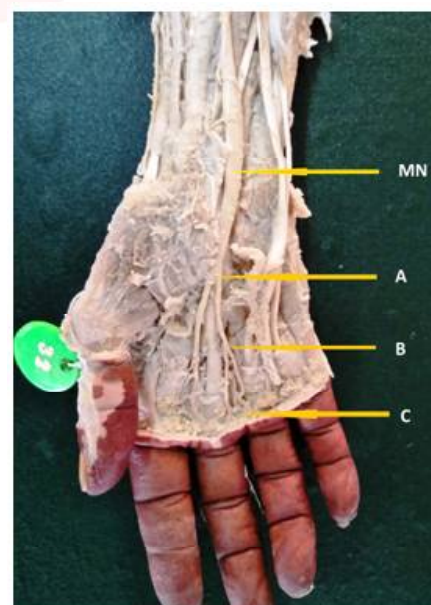
The digital nerves lie deep to superficial palmar arch and at the sides of the fingers, the nerve appears in front of vessels to provide rich communication to the sensitive pulp of the finger tips. Each proper digital nerve gives articular branches to metacarpophalangeal joint, interphalangeal joint, skin of palmar aspect of digit including pulp space, nail bed & skin over dorsal surface of middle & terminal phalanges. In clinical practice only around 3% of hand injuries include injury to peripheral nerve trunks. Even a minor injury to a finger causing a digital nerve injury [Incidence 6.2/100 000 inhabitants/year] may induce dysfunction of the hand. Although costs of nerve injuries burden the health care sector, the main part of the total cost is caused by loss of productivity [sick leave] [6].

MATERIALS AND METHODS

The 33 human cadaver upper limb specimens were obtained from Department of Anatomy,

Sree Narayana Institute of Medical Sciences, Ernakulam. These specimens were fixed in 10% neutral buffered formalin. Specimens which exhibited damaged nerves, malformations/deformities, surgical scars were excluded. The gross dissection was done by dividing flexor retinaculum in the midline avoiding damage to underlying structures. Superficial palmar arterial arch, branches of median nerve and lumbricals were identified. The branches of median nerve in the hand were traced to identify the third webspace branch of median nerve. The three markings A) Distal end of flexor retinaculum, B) Division into proper digital nerves and C) Proximal transverse crease of digits at the webspace were taken as landmarks for measuring the length of the available nerve for grafting. First reading was measured from the distal end of flexor retinaculum to its division as proper digital branches [from A to B] & second reading was measured from division to proximal transverse crease of digits at webspace [from B to C] with the help of vernier callipers and measurements were noted down.

Fig. 1: Showing the three landmarks for measuring the length of nerve available for grafting. MN- Median nerve, A) Distal end of flexor retinaculum, B) Division of common digital into proper digital branches, C) From proper digital branch to proximal transverse crease of digits at webspace.



RESULTS

The observations of the present study done on 33 upper limb specimens are shown in the tables 1 to 6. Table no.1 shows the overall length of

third webspace branch of median nerve from distal end of flexor retinaculum to web space available for grafting. The mean length available being 6.45 cm which can be used for reinnervation of the recipient nerve injury in ulnar or median nerves. 69.7 % of donor length [Table no.2] lies in the range of 5.1 to 7.5 cm which can be adequately used to bridge the gap of 3–6 cm injury. The mean available length of third webspace branch of median nerve from distal end of flexor retinaculum to its division into proper digital branches is 2.8 cm with S.D of 0.65 [Table no.3] and table no.4 shows that 91% of available length for grafting in between point A to B lies in the range of 2 to 4 cm. If the donor length required is less than 3 cm, then the surgeon can take only the length of nerve from distal end of flexor retinaculum till its division so that he can suture the distal stump to the adjacent branch to retain innervation in digits. The mean length of nerve available from point B to C is 3.6 cm with S.D of 0.58. [Table no.5] and 90.9% of available length lies in the range of 3.1 cm to 5 cm [Table no.6]. In three specimens we observed the loop of common digital nerve fibres around the adjacent common digital arteries of palmar arch.

Table 1: Measurement from point A to C.

Number of specimens	Mean (cm)	S.D	Range (cm)
33	6.45	0.656	4.52 – 7.57

Table 2: Length of third webspace branch of median nerve from point A to C.

Range	Number	%
<2.5cm	0	0
2.6- 5 cm	9	27.3
5.1-7.5cm	23	69.7
>7.5cm	1	3

Table 3: Measurement of from point A to B.

Number of specimens	Mean (cm)	S.D	Range (cm)
33	2.841	0.6517	1.83 – 4.08

Table 4: Length from point A to B.

Range	Number	%
1.1 - 2 cm	3	9
2.1 - 3 cm	22	66.7
3.1 – 4 cm	8	24.2

Table 5: Measurement from point B to C.

Number of specimens	Mean (cm)	S.D	Range (cm)
33	3.606	0.5869	2.42 – 4.65

Table 6: Length from point B to C.

Range	Number	%
1.1 – 2 cm	0	0
2.1 – 3 cm	3	9
3.1 – 4 cm	24	72.7
4.1 – 5 cm	6	18.2

DISCUSSION

Nerve injuries range from simple nerve compression lesions to severe lacerations. A thorough knowledge of anatomy of peripheral nerve trunk as well as of basic neurobiological alterations in neurons & schwann cells induced by the injury are crucial for the surgeon in making adequate decisions on how to repair and reconstruct nerves [7]. A potential graft material should fulfil many conditions like the relationship between surface area, diameter and length of the graft and allow rapid revascularisation. The donor site defect from sacrifice of any given nerve must be acceptable for the patient. The harvested nerve must be long enough to ensure a tension free anastomosis with the adjacent joints in full extension, finally the cross-sectional area and number of fascicles should match those of recipient nerve at the level of injury as closely as possible. For these reasons most of the available grafts are cutaneous nerves.

Nerve grafting acts as an important reconstructive technique for acute management of nerve injuries. Modern nerve-to-nerve transfers represent one of the greatest advances in peripheral nerve surgery. Lessons of tendon transfers have taught that nerves to specific musculotendinous units are expendable, and greater understanding of peripheral nerve topography has revealed redundant fascicles in peripheral nerves. Transfer of these redundant or expendable nerves to recipient nerves close to the end organ allows for earlier reinnervation and preservation of those musculotendinous units. Such nerve transfers provide significantly better treatment options in many cases of nerve injury where previous outcomes were expected

to be poor, such as with proximal injuries, long nerve gaps, or unavailability of the proximal injured segment [8].

The autogenous donor nerve grafts are used for providing continuity between the two ends of the injured nerve [Recipient nerve]. Multiple upper extremity nerves are being utilised as autograft donors; those include medial antebrachial cutaneous nerve, third web space branch of median nerve, lateral antebrachial cutaneous nerve, palmar cutaneous and dorsal cutaneous branch of ulnar nerve, posterior cutaneous nerve of forearm, superficial radial nerve, posterior interosseous nerve and anterior interosseous nerve. From lower extremity the donor nerves are sural nerve, superficial peroneal nerve, lateral femoral cutaneous nerve and saphenous nerve. Since the donor nerves are produced from the same person [Autogenous graft] likely chances of rejection are very less [9]. Higgins [10] provided criteria for the selection of donor sites for nerve harvesting in digital nerve reconstruction. He investigated the cross-sectional area & number of fascicles of both donor nerves and specific digital nerve segments.

A study done by Ross D, Mackinnon SE, Chang YL [11] stated that the average length of the third web-space fascicular group that could be separated from the median nerve proper prior to plexus intermingling was 24.5 cm. Cross-sectional areas of the graft and the remaining nerve were 4.43 mm² and 13.76 mm², respectively. The number of nerve fibres in the third web-space group was 4,847 and in the remaining median nerve were 13,486. Between February 1989 and October 1991, this technique was used on 11 patients to provide donor nerve material for nerve gaps of 3 to 6 cm in the median nerve. In the present study, we have measured the length of third webspace branch within the palm distal to flexor retinaculum up to webspace which can be used for grafting within the palm injuries. This gives an advantage to surgeons that there is no need of dissecting flexor retinaculum to take the donor nerve. In the palm, the third webspace branch of the median nerve can also be used to restore more critical ulnar border digit sensation in a high ulnar nerve injury or upper brachial plexus palsy. This transfer can also be performed in the palm or as a sensory fascicu-

lar transfer in the distal forearm [12]. If the length of donor nerve necessary is around 5 cm, the length of nerve from point A to B can be harvested by suturing the distal end of proper digital nerve to adjacent branch. If the thickness of the nerve required for grafting is less, then the length of nerve from point B to C can be harvested.

In case of injury to ulnar side of hand the nerve graft from third web space can be used to bridge the gap of ulnar nerve branch and the distal stump of third webspace nerve can be sutured to adjacent nerve. For incomplete median nerve lesions or upper brachial plexus injury (C5 to C6), the sensory fascicle to the third webspace can be transferred to the first webspace for critical thumb and index finger sensation. The third webspace branch of median nerve can be used to restore sensation either in ulnar border or in first webspace for thumb and index finger. The distal stump of the donor fascicle can be coapted end-to-side back to the median nerve as reviewed by Amy M. Moore, Michael Franco and Thomas H Tung [13]. The looping of few fibres around the adjacent blood vessel as seen in 3 cases might get injured while procuring graft. It is advisable to know the branching pattern, communications and variants before taking nerve for grafting to avoid unwanted complications.

CONCLUSION

Upper-extremity nerve reconstruction can be successfully accomplished using donor nerves from the ipsilateral limb in the majority of cases. Judicious selection of donor nerves can reduce patient morbidity and operative time but necessitates a thorough understanding of internal nerve topography and availability of expendable donor nerve length. The present study gives an available length for grafting from third webspace branch of median nerve which can be used in cases of distal injury to ulnar or median nerve requiring interposition grafting. We recommend use of available graft material of third webspace branch of median nerve for autogenous grafting according to the need.

ACKNOWLEDGEMENTS

We wish to thank with due respect and deep gratitude to the other teaching and non-teach-

ing staff from the Department of Anatomy, Sree Narayana Institute of Medical Sciences, Ernakulam for suggestions and advice that helped us to a great extent.

Conflicts of Interests: None

REFERENCES

- [1]. Kouyoumdjian JA. Peripheral nerve injuries: a retrospective survey of 456 cases. *Muscle & Nerve*, 2006;34(6):785-788.
- [2]. Siemionow M, Brzezicki G. Current techniques and concepts in peripheral nerve repair. *International Review of Neurobiology*, 2009;87(C):141-172.
- [3]. Thomson JG. Median and ulnar nerve injuries: A meta-analysis of predictors of motor and sensory recovery after modern microsurgical nerve repair: Discussion. *Plastic and Reconstructive Surgery*, 2005;116(2):495-496.
- [4]. Brushart TME. The mechanical and humoral control of specificity in nerve repair. In *Operative Nerve Repair*. R.H.Gelberman, Ed., JB Lippincott, Philadelphia, PA, USA;1991:215-230.
- [5]. Scholz T, Krichevsky A, Sumarto A, Jaffurs D, Wirth GA, Paydar K, Evans G. Peripheral nerve injuries: an international survey of current treatments and future perspectives. *J Reconstr Microsurg*. 2009;25(6):339-44.
- [6]. Rosberg HE, Carlsson KS, Hojgard S, Lindgren b, Lundborg g, Dahlin LB. Injury to the human median and ulnar nerves in the forearm—analysis of costs for treatment and rehabilitation of 69 patients in southern Sweden. *J Hand Surg (br)* 2005;30:35-39.
- [7]. Dahlin LB. Techniques of peripheral nerve repair. *Scandinavian Journal of Surgery*, 2008;97:310-316.
- [8]. Mackinnon SE, Colbert SH. Nerve transfers in the hand and upper extremity surgery. *Tech Hand up Extreme Surg*. 2008 Mar;12(1):20-33.
- [9]. David J Sultsky. A Practical Approach to Nerve grafting in the upper extremity. *Atlas of the Hand Clinics*. 2005;(10):73-92.
- [10]. Higgins JP, Fisher S, Serletti JM, Orlando GS. Assessment of nerve graft donor sites used for reconstruction of traumatic digital nerve defects. *J Hand Surg [Am]* 2002;27:286-92.
- [11]. Ross D, Mackinnon SE, Chang YL. Intraneural anatomy of the median nerve provides “third web space” donor nerve graft. *J Reconstr Microsurg*. 1992 May;8(3):225-32.
- [12]. Tung TH, Mackinnon SE. Nerve transfers: Indications, techniques, and outcomes. *J Hand Surg Am*. 2010;35:332-341.
- [13]. Amy M. Moore, Michael Franco, Thomas H Tung. Motor and sensory nerve transfers in the forearm and hand. *Hand/Peripheral nerve. Plastic and reconstructive surgery*. October 2014;134(4):721-730.

How to cite this article:

Raviprasanna.K.H, Anand L Kulkarni, Aditya Krishna Das. MORPHOMETRIC STUDY OF THIRD WEB SPACE BRANCH OF MEDIAN NERVE: ITS CLINICAL IMPLICATIONS ON NERVE GRAFTING. *Int J Anat Res* 2016;4(4):3232-3236. **DOI:** 10.16965/ijar.2016.447