

## MORHOMETRIC STUDY OF SEPTOMARGINAL TRABECULAE (MODERATOR BAND)

Praveen Shenoy <sup>\*1</sup>, Martin Lucas <sup>2</sup>, Vinay KV <sup>3</sup>, Amith Ramos <sup>4</sup>.

<sup>\*1</sup> Post Graduate, Department of Anatomy, K.S. Hegde Medical Academy, Nitte University, Karnataka, India.

<sup>2</sup> Professor & HOD, Department of Anatomy, K.S. Hegde Medical Academy, Nitte University, Karnataka, India.

<sup>3</sup> Associate Professor, Department of Anatomy, K.S. Hegde Medical Academy, Nitte University, Karnataka, India.

<sup>4</sup> Assistant Professor, Department of Anatomy, K.S. Hegde Medical Academy, Nitte University, Karnataka, India.

### ABSTRACT

**Background and objectives:** Septomarginal trabeculae or Moderator band is a specialized bridge connecting interventricular septum to the base of the anterior papillary muscle. It contains Right Bundle branch of HIS, it is also Known to prevent the over distension of the right ventricle. The literature review shows the paucity of articles related to morphological and morphometric evaluation. Since it has a great clinical importance its, further studies become Mandatory. Here we have measured the angle of the Moderator band to its origin from the interventricular septum and the anterior papillary muscle is measured. The superficial marking of Moderator band on the sternocostal surface of the right ventricle is marked.

**Materials and Methods:** 50 Formalin soaked cadaveric Hearts were taken from the department of Anatomy of KSHEMA. 36 Males and 14 Female Hearts were tagged according to ascending order of the age. Moderator band, surface marking on sternocostal surface, the angle with the anterior papillary Muscle ect are Noted.

**Result:** The morphological variations are noted. The results are compared with gender, with the previous results.

**Conclusion:** There is a difference in the course of moderator band. In 60% the moderator band runs downwards and to the right, in 30% it is found to be horizontal and in 10% runs upwards and to the right. The difference is found in males and females as well. The surface marking of moderator band on sternocostal surface of the heart measures more due to the convexity of the right ventricular surface. This knowledge will help in accurate detection of the moderator band by echocardiography and in surgeries.

**KEY WORDS:** Septomarginal trabeculae, Moderator Band, surface marking, Right ventricle.

**Address for Correspondence:** Dr. Praveen Shenoy, Post Graduate, Department of Anatomy, K.S. Hegde Medical Academy, Nitte University, Karnataka, India. Mobile No.: +919591422543

**E-Mail:** shenoy1100@gmail.com

### Access this Article online

#### Quick Response code



DOI: 10.16965/ijar.2016.467

**Web site:** International Journal of Anatomy and Research  
ISSN 2321-4287  
[www.ijmhr.org/ijar.htm](http://www.ijmhr.org/ijar.htm)

Received: 04 Nov 2016  
Peer Review: 04 Nov 2016  
Revised: None

Accepted: 13 Dec 2016  
Published (O): 31 Dec 2016  
Published (P): 31 Dec 2016

### INTRODUCTION

A muscular band, well-marked in sheep and some other animals, frequently extends from the

base of the anterior papillary muscle to the ventricular septum. From its attachments it may assist in preventing over distension of the ven-

tricle, and so has been named the moderator band [1]. In spite of numerous studies devoted to the septomarginal trabecula, the opinion of researchers is not uniform. The controversies focus mostly on its structure, phylogenies, and function. Only a few papers precisely describe its morphology, but the still incoherent nomenclature imposes some significant limitations [2]. In 1837 King named it as the “moderator band” since, according to his concept, the trabecula limited the excessive expansion during diastole of the right ventricle [3].

The term “septomarginal trabecula” was first used by Tandler [4] based on its attachments: proximal (the septum), and distal (the wall). Nowadays, both terms are used interchangeably.

The moderator band, another marker for the morphologically right ventricle, takes off from the body of the ventricular septum to cross to the parietal wall carrying within it a fascicle of the right bundle branch of the atrioventricular conduction system [5] allowing coordinated contraction of the anterior papillary muscle. The right branch of ‘His’ bundle within the muscular part of the septum located is proved to be continuous with the moderator band. The results of analyses prove a relatively constant character of the presence of the conduction system within the moderator band [6].

Some probable pathologies occurring within the band, most often the ischemic in origin, can constitute an important aetiology of conduction disturbances of the heart [2,7].

The morphometric study of moderator band may help the surgeons during surgical procedures conducted for correction of such defects [8].

The moderator band artery has anastomotic connections at the base of the anterior papillary muscle of the right ventricle with various branches of the right coronary artery, which means that it can play a key role in collateral circulation following obstruction of the coronary arteries [9].

Collateral flow to the right ventricular myocardium, especially through the moderator band artery, protects against massive infarction in the presence of proximal right coronary artery occlusion [10]. The moderator band can be a source of premature ventricular contractions, monomor-

phic ventricular tachycardia, and idiopathic ventricular fibrillation [11].

Moderator band is a normal structure and identifies a morphological Right Ventricle. If not properly evaluated it may be confused with a mass near Right Ventricular apex [12]. Superior displacement of the moderator band is quantifiable by 2-dimensional echocardiography and may help to predict which infants with a Ventricular septal defect are at risk to develop sub pulmonary obstruction [13].

Features which help differentiate the anatomic Right Ventricle from anatomic Left Ventricle include 1) the more apical insertion point of the septal leaflet of the tricuspid valve relative to the anterior leaflet of the mitral valve 2) the presence of a moderator band 3) the presence of more than 2 papillary muscles, and 4) the trileaflet configuration of the tricuspid valve [14].

This present study intends to throw more light on morphology and morphometric evaluation of the moderator band. The length, the angle it forms with the interventricular septum and with the anterior papillary muscle is measured. The depth of moderator band to anterior papillary junction and the depth of junction of moderator band to the interventricular septum is measured from the sternocostal surface of the right ventricle and the surface marking of the moderator band is measured by noting its distance from the moderator band –papillary junction, moderator band –interventricular septal junction to the right border of the heart and to the apex of the heart. The results are tabulated and compared with previous results. Since there is less studies done on morphology of moderator band, our study is more aimed at differentiating the male and female characteristics, variations and the superficial surface marking of the moderator band on the wall of the right ventricle, on sternocostal surface in precise. The directions given in locating the moderator band will be of importance in anatomical dissection, guide to the surgeons and radiologists.

## MATERIALS AND METHODS

50 formalin soaked cadaveric heart chosen from the department of anatomy, KS Hedge Medical Academy, aged between 30 to 75, as obtained

from the registry. 36 male and 14 female cadaveric hearts were taken. The hearts were tagged in accordance to ascending age, both in male and in female. Age is approximated as in registry wherever it was difficult to get the exact figure and labelled with 'star sign', as superscript in the results.

Only the adult male and female hearts were taken between the age group of 30 to 75. The heart with gross pathology, if any, externally or internally is excluded from the study. No foetal or neonatal hearts were taken.

The surgical blade with scalpel, toothed and non-toothed forceps, and needle pointer, measuring tape, transparent protractor, digital Vernier calipers, ordinary thread, magnifier lens, Light source, display signs, hand digital camera and markers were used in each step during the study.

**Methodologies:** First a parallel incision is placed along the upper border of right ventricle, around 1.5 to 2cm below and to the right of the surfacement of the pulmonary trunk. Starting from the left end; the incision is dragged till the right border, making sure of the feel of cutting through the thickness of the ventricular wall. Care is taken not to cut the chordae tendinae of the anterior papillary muscle by introducing a finger and extending the incision.

The incision is extended from the right end, downwards .1cm parallel along the right border, continuously visualising the interior as some of the papillary muscle will be attached at the higher end or towards the right border. Clots, debris found is washed with running water and/or removed with help of toothed forceps. In case of hard mass, first the mass is broken into pieces by sharp needle, such method will prevent any damage which can be caused in abrupt removal of the debris.

Once the anterior papillary muscle is visualised the incision from the left upper end is carried out, in parallel and, 0.5 cm from interventricular groove, visualising the interventricular septum, tracing down extending the incision to reach the origin of the moderator band. Care is taken not to pull the wall too anteriorly, as this might cause the tear of anterior papillary muscle.

Once the moderator band is defined, further careful extensions of the incisions are done in

order to ease out the measurements.

In case of very thick walled heart, where the retraction and reflection becomes difficult, the upper sternocostal wall is dissected and detached completely till proximal to the papillary attachment. The fine clots or blood is removed with forceps and running water. A jet spray of water is used to remove all the fine particles which makes the view will be clearer for pictures to be taken.

**Measurement of the Angle:** The Angle between the longitudinal axis of the moderator band to the longitudinal axis of interventricular septum is measured using the transparent protractor. The angle between the longitudinal axis of anterior papillary muscle and longitudinal axis of moderator band to its base is also measured.

**Measurement of the depth:** Measurement of the depth of the junction between the base of the anterior papillary muscle and the papillary insertion of the moderator band is noted by piercing needle probe through the anterior wall of the right ventricle, followed by its measurement. The depth of the junction of moderator band to the interventricular septum is also measured in the same way.

**Surface marking of moderator band on sternocostal surface of right ventricle:** Measurement of the superficial surface marking of the moderator band on the sternocostal surface of the right ventricle is done in following steps

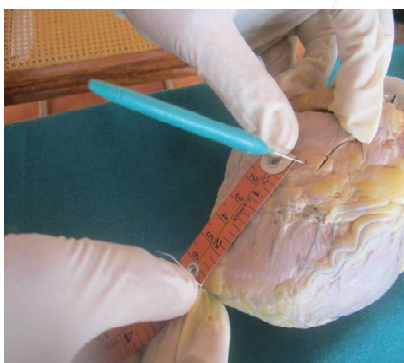1. A needle is inserted at the junction of band and the anterior papillary muscle. The distance from the right border and the apex is measured by keeping the heart in anatomical position and measuring the distance along line in horizontal direction meeting the right border, and line joining the point of the needle to the tip of apex of the heart.
2. The needle is inserted at the origin of the moderator band from the interventricular septum. The distance from it to the right border and to the apex of the heart is measured.
3. Distance between above two points is measured and the direction is noted on the sternocostal surface of the right ventricle.

**Collection and recording of data:** The measurements taken are statistically analysed using SPSS software with the help of the statistician.

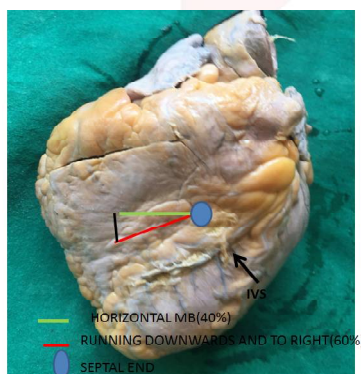


All measurements are taken in millimetres except the surface marking, of which the readings are taken in centimetres. The results are compared with previous studies and variation in morphology and morphometry in males and in females are plotted in different tables and graphs.

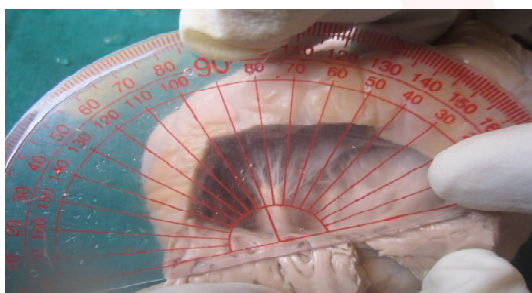
**Fig. 1:** Measuring the distance between the junctions of moderator band and interventricular junction to apex of the heart.



**Fig. 2:** Surface marking of moderator band on sternocostal surface of the heart.




**Fig. 3:** Measuring the Angle APM/MB junction.



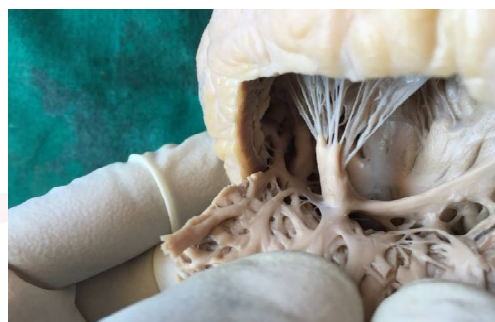**Fig. 4:** Most laterally, deeply placed APM and note MB /septal junction slightly lower than the APM/ MB junction. (No F 02).



**Fig. 5:** Low located MB/APM and MB/septal junction, and MB/septal located slightly lower than the MB/APM (No M 26).



**Fig. 6:** Laterally Placed APM. also note the mesh like branches orininating from the lower border of MB(No F 14).



## RESULTS AND OBSERVATIONS

**Length:** The length of the moderator band is measured from the septal end to the papillary end using digital Vernier Callipers, the pointed divider or by placing the tread through the course of the moderator band on its upper and lower border and measuring its Length on scale. This method helps in getting accurate measurements.

In our study we found the mean length of the Moderator Band to be 15.06 mm.

**Measurement of the Depth:** The insertion of MB to APM is noted. A needle is passed through the anterior wall of sternocostal surface to this point; penetrated depth of the needle is marked and measured over scale. In similar way the septal end depth is also measured. The average depth in male and female, the difference is noted, compared and recorded on the graph and table.

**Surface Marking of the Moderator Band Distance and Direction on the Sternocostal Surface of the right ventricle:** The measurements are taken at two points.

1. A sharp Needle is inserted through the anterior wall or sternocostal surface of the right ventricle, at the junction of anterior Papillary Muscle to the base of the Moderator Band.

Further the distance between these points to the right border of the Heart is measured by keeping Heart in Anatomical Position and the distance between these points to the apex of the Heart. The average distance from this point to the right border is found to be 3.15cm and average distance from this point to the apex of the Heart is found to be 5.08cm. The Male and Female difference and variation are plotted in the graph.

2. The sharp needle is inserted through the anterior wall or sternocostal surface of the right ventricle, to the junction of Interventricular septum to the origin of the Moderator band. The distance between this point to the right border is measured by keeping the Heart in anatomical Position and the distance between this point to the apex of the Heart is Measured. The average distance from this Point the right border of the Heart is found to be 4.71cm and average distance from this point to the apex of the Heart is found to be 5.40cm The Deference in Male and Female and the variation are plotted in the graph and the table. The distance between the junction of the anterior Papillary Muscle to the base of the Moderator Band and junction of Interventricular septum to the origin of the Moderator band on the sternocostal surface of the right ventricle is measured. The average distance is found to be 1.7cm. The Male and Female difference and variation are plotted in the graph. Moderator band found to run from MB/septal junction to the right, downwards to join MB/papillary junction .however 10% it can be found running upwards and to the right as MB/septal junction is found to be located lower than the MB/papillary junction.

## DISCUSSION

Septomarginal trabeculae or the moderator band is a well-known structure present in the right ventricle of the heart. it connects the interventricular septum to the base of the anterior papillary muscle. it is proved that it carries a moderator band artery and right bundle branch of His. Within our study specimens, even though the size of the moderator band is variable it is clearly visible and well developed structure. There were many misleading names given in the past such as muscular string, left ventricular

chordae tendinae, fascicles ect.Histology of moderator band in left ventricle was described by Turner [18].

During the development of moderator band the right ventricular inlet tract outgrowth results in division of the primary fold of the septal part, with its lateral part, which extends laterally as moderator band upto the right atrioventricular ring. The electro physiological readings taken in the embryonic heart, supports the atrioventricular connection via the moderator band .the observations provide the functional and morphological importance of septomarginal trabeculae in carrying accessory pathway in mahaim tachycardia [19].

The hypertrophy of moderator band can lead to double chambered right ventricle and which in turn leads to the stenosis of pulmonary outlet [20].

In moderator band anatomy is of important in correction of high located congenital ventricular septal defects [21].

The various parameters studied are discussed in respective headings.

**Morphometry of Moderator band angle:** In our study the mean angle at septal junction of moderator band is found to be  $115^{\circ}$  with variation of  $\pm 5^{\circ}$  , when angle measured from the axis of the IVS to the axis of the MB from its upper end or  $60^{\circ}$  when measured from the axis of the IVS to the MB from its lower attachment.

In Adam Kosinski et al [2] study they divided arising of the secondary trabeculae with respect to the angle of moderator band to the axis of the IVS to into 3 groups. 1).  $0^{\circ}$  to  $30^{\circ}$  2).  $30^{\circ}$  to  $60^{\circ}$  and 3)  $60^{\circ}$  to  $90^{\circ}$ . In 100 heart they studied 22 hearts belong to group 1. And gave rise to only one secondary trabeculae. 14 hearts belong to group 2 and gave only one secondary trabeculae. 29 hearts belong to group 3, out of which only one gave one secondary trabeculae, 12 hearts gave two trabeculae and 3 hearts gave three trabeculae. In our study 15 hearts found to be group 1 type, 10 hearts found to be group 2 , and remaining 25 belongs to group 3. This grouping in agreement with adam study, however secondary trabeculae pattern Varies. 10 heart belongs to group 1 had one secondary trabeculae, 3 had 2 secondary trabeculae, in group 2

we got one trabeculae in 9 hearts 2 trabeculae, 2 trabeculae in 2 hearts and 3 trabeculae in 3 hearts. In group in we had one trabeculae in 3 heart, 2 trabeculae in one heart and 3 trabeculae in one heart.

Further in our study we documented more than 3 secondary trabeculae and we also classified the branches given from upper border and lower border. A mesh like trabeculae pattern can be noted in one of the female specimen., There is one evidence of false chordate tendinae originating from the upper border of the moderator band . In one case a accessory papillary muscle originate of the junction of APM to IVS.

We further measured the angle of MB to papillary junction. The average angle recorded to be  $91^{\circ}$  with the standard deviation of  $23^{\circ}$ . These two measurements helps to find the course of MB. In 50% of the cases it is found to be Horizontal, 48% it is found to be running downwards and to the right, in 2% it runs above and to the right , since the low location of MB / septal junction when compared to MB /papillary junction.

**Morphometry of Moderator band Depth:** It is measured at two junctions, one at the moderator band/APM junction and other at the moderator band /IVS junction. Since MB/APM junction lies on the anterior wall itself, the depth almost equivalent to the thickness of the right ventricle. The average depth of this junction is found to be 3.7mm. The MB/septal junction lies usually deeper, upper and to the left of MB/papillary junction. This average of this depth is found to be 4.2mm. In 2 cases the MB/IVS junction is found to be Laing lower than the MB/APM. The moderator band /septal junction is found to be more in superficial plane in females than in males.

In S.T.F Bandeira et al [16] study the type 1 septomarginal trabeculae was found to be 8%.which referrers to the attachment of moderator band only to the base of anterior papillary muscle without ramification to the anterior ventricular wall.

In our study in agreement with the above study. And hence the depth at moderator band to the papillary junction is found in deeper plane when compared with other types.

### **Surface marking of the moderator band on the sternocostal surface of the right ventricle:**

In our study average distance of the moderator band/papillary junction to the right border of the heart is found to be 3.13mm,the average distance of moderator band/papillary junction to the apex of the heart is found to be 5.06mm,. Average distance of the moderator band/septal junction to the right border of the heart is found to be 4.71mm,, and Average the distance of the moderator band/septal junction to the apex of the heart is found to be 5.4mm .through this we can find that the moderator band is located almost mid region of the sternocoastal surface of the right ventricle, in 60% of specimens the moderator band is directed downwards and to the right. in 36% it is found to be having a horizontal course. But in 4%of the cases where the moderator band/septal junction is located lower than the moderator band/papillary junction, the direction of the moderator is running upwards and to the right. The average distance between the two junctions is found to be 17.3mm. the difference in distance is due to the low lying junction, mainly the moderator band/sepal and also the convexity of the right ventricle.

In R.C Traux et al [17] study, the mean septal attachment distance is found to be 3.91cm with range of 1.5 cm to 7.2cm. They reported the incidence of moderator band in 56% of specimens. The distance taken was to the apex of the right ventricle.

### **CONCLUSION**

#### **Morphometry of angles of moderator band:**

The angle of origin of moderator band from the interventricular septum and the angle formed at its insertion to the anterior papillary muscle give a clear picture about the direction of the band. In 4%of cases moderator band is found to be running upwards and to the right, as the junction of moderator band/interventricular septum lies slightly at the lower level than the moderator band and papillary junction .there is a difference in male had female specimens.

#### **Morphometry of depth of moderator band:**

The depth measured from the sternocostal surface to the moderator band/interventricular junction and of the moderator band /papillary junction differs as the latter lies in deeper plane.



Measurements of the former also shows the thickness of the right ventricle as moderator band is found to be attached at its base in most of the cases. there is a difference found both in male and female measurements.

Surface marking of moderator band on the sternocostal surface of the right ventricle.

We took the measurements from the right border and from the apex of the heart to the moderator band /papillary junction and moderator band/septal junction. In more than 60% of cases, the moderator band found to run downwards and to the right. and location is found to lie in the mid region on the sternocostal surface of the right ventricle.

**Conflicts of Interests: None**

## REFERENCES

- [1]. Peter L Williams: Grays Anatomy, 39th edition, Churchill Living stone. 2005, pp 1002-3.
- [2]. Adam Kosiński, Dariusz Kozłowski, Janusz Nowiński. Morphogenetic aspects of the septomarginal trabecula in the human heart, Arch Med Sci. 2010 Oct; 6(5): 733–743.
- [3]. Grant RP, Downey FM, MacMahon H. The architecture of the right ventricular outflow tract in the normal human heart and in the presence of ventricular septal defects. Circulation. 1961;24:223–35.
- [4]. Tandler J. Anatomie des Herzens [German] Gustav Fischer, Jena. 1913;1-3.
- [5]. SY Ho, P Nihoyannopoulos. Anatomy echocardiography and normal right ventricular Dimensions Heart. 2006; 92(Suppl 1):2–13.
- [6]. Kosiński A, Grzybiak M, Nowiński J, Kędziora K, Kuta W, Dłubowska-Kugacka. Morphological remarks regarding the structure of conduction system in the right ventricle. Kardiologia Pol. 2012;70(5):472-6.
- [7]. Geoffrey farrer-brown, Vascular Pattern of Myocardium of Right Ventricle Of Human Heart. Brit. Heart J., 1968;30:679.
- [8]. Loukas M, Klaassen Z, Tubbs RS, Derderian T, Paling D, Chow D, Patel S, Anderson RH. Anatomical observations of the moderator band. 2010 May;23(4):443-50.
- [9]. Reig J, Albertí N, Petit M. Arterial vascularization of the human moderator band: an analysis of this structure's role as a collateral circulation route. Clin Anat. 2000;13(4):244-50.
- [10]. H M Haupt, G M Hutchins, G W Moore . Right ventricular infarction: role of the moderator band artery in determining infarct size. Circulation. Jun 1983;67(6):1268-72.
- [11]. Sadek MM, Benhayon D, Sureddi R, Chik W, Santangeli P, Supple GE et al . Idiopathic ventricular arrhythmias originating from the moderator band: Electrocardiographic characteristics and treatment by catheter ablation . Heart Rhythm. 2015 Jan;12(1):67-75.
- [12]. SR Mittal . Moderator Band Wrongly Interpreted as RV Mass. JAPI. August 2012;60:1-3.
- [13]. Wong PC, Sanders SP, Jonas RA, Colan SD, Parness IA, Geva T, Van Praagh R, Spevak PJ. Pulmonary valve-moderator band distance and association with development of double-chambered right ventricle. The American journal of cardiology. 1991 Dec 15;68(17):1681-6.
- [14]. Haddad F, Couture P, Tousignant C, Denault AY., The right ventricle in cardiac surgery, a perioperative perspective: II. Pathophysiology, clinical importance, and management Anesth Analg. 2009 Feb;108(2):422-33.
- [15]. Mamatha H, Divya Shenoy , Antony Sylvan D' Souza, Prasanna LC, Suhani Sumalatha. Morphometric Study on the Septomarginal Trabeculae in South Indian Cadavers. RRJMHS 2013;2(2):65-70.
- [16]. S.T.F. Bandeira, G.C. Wafae, C. Ruiz, S.R. Nascimento, J.R. Fernandes, N.Wafae. Morphological classification of the septomarginal trabecula in humans, Folia Morphol. 2011;70(4):300–304.
- [17]. R. C. Truex, L. J. Warshaw. The incidence and size of the moderator band in man and in mammals. Anat. Rec., 1942;82:361–372.
- [18]. W. Turner Moderator Band in Left Ventricle and Tricuspid Left Auriculo-Ventricular Valve. J Anat Physiol. 1898 Apr;32(Pt 3):373–376.
- [19]. M.R.M. Jongbloed, M.C.E.F. Wijffels, Development of the Right Ventricular Inflow Tract and Moderator Band. A Possible Morphological and Functional Explanation for Mahaim Tachycardia. Circulation Research. March 10, 2005;96:776-783.
- [20]. Theodoros Xanthos, Ioannis Dalivigkas, Konstantinos A. Ekmektzoglou. Anatomic variations of the cardiac valves and papillary muscles of the right heart. IJAE 2011;116(2):111-126.
- [21]. Richard A Jonas., Comprehensive Surgical Management of Congenital Heart Disease. J R Soc Med. 2004 Aug; 97(8):407–408.

**How to cite this article:** Praveen Shenoy, Martin Lucas, Vinay KV, Amith Ramos. MORHOMETRIC STUDY OF SEPTOMARGINAL TRABECULAE (MODERATOR BAND). Int J Anat Res 2016;4(4):3302-3308. **DOI:** 10.16965/ijar.2016.467