

Case Study

CHARACTERIZATION OF LOBSTER HAND/FOOT MALFORMATIONS WITH GENETIC EXPRESSION: A FAMILIAL STUDY

M.Yesender *, N.Himabindu, S.Saritha, B. Sadananda rao, T.V. Ramani , Nagajyothi.

Department of Anatomy, KAMS & RC, Hyderabad Telangana, India.

ABSTRACT

Introduction: The Lobster Claw Deformity is a form of Ectrodactyly and is a rare combination of ectodermal dysplasia. The Lobster claw deformity is also known as the split hand /foot malformation (SHFM) it is a heterogeneous limb developmental disorder characterized by missing digits and fusion of remaining digits. The pathophysiology of split hand and foot is mainly because of wedge shaped defect of the apical ectoderm of the limb bud.

Aim: The present study aims to provide prominent roots in transmitting and expressivity of lobster claw hand and foot linked to genetic expression.

Materials and Methods: We present two cases of split hand and foot which includes two female siblings aged 7 and 6 years old during routine cases attending the OPD in a private nursing home. The ethical committee permission was taken. Permission was also taken from their parents of respective cases to publish the article.

Conclusion: This scientific paper adopted to illustrate this rare congenital disorder Lobster claw hand/foot malformations. These examples demonstrate understanding of Ectrodactyly coordinating with clinical examination, radiological and genetic investigations.

KEY WORDS: Split hand/foot malformation (SHFM), Ectrodactyly, lobster claw hand/foot Autosomal dominant, autosomal recessive.

Address for Correspondence: Dr. M.Yesender, Department of Anatomy, KAMS & RC, Hyderabad Telangana, India. **E-Mail:** matteda.yesender@gmail.com

Access this Article online

Quick Response code



DOI: 10.16965/ijar.2016.428

Web site: International Journal of Anatomy and Research
ISSN 2321-4287
www.ijmhr.org/ijar.htm

Received: 06 Oct 2016
Peer Review: 06 Oct 2016
Revised: None

Accepted: 17 Dec 2016
Published (O): 31 Jan 2017
Published (P): 31 Jan 2017

INTRODUCTION

The split hand /foot malformation (SHFM) is the form of Ectrodactyly which is derived from Greek ektroma (abortion) and daktylos (finger)= literally, abortion of a finger characterized by deep median clefts, congenital absence of one or more missing fingers or toes and associated with fusion of remaining digits. It is synonymous to lobster claw because it gives a claw like appearance of the distal extremities [1].

A typical cleft hand or foot is V- shaped or U - shaped defect. The V- shaped defect presents

with missing phalanges and metacarpals and it is usually linked with X-linked dominant trait. There is syndactyly of small, ring and thumb, index fingers.

A typical claw hand/ foot is U- shaped defect where index, long and ring fingers are absent and metacarpals are present [2].

The SHFM has been mapped to 7q21.3-q22.1 on chromosomal rearrangement [3].

Prenatal diagnosis of Ectrodactyly was first reported in 1980 where most of them live a normal life with very little functional defects of

limbs [4].

We report two female siblings of lobster hand / foot cases correlating their external features with radiological and karyotype investigations.

MATERIALS AND METHODS

Both the sisters were affected with lobster hand/ foot (fig1), parents were from consanguineous marriage and appeared normal with no external limb defects.

OBSERVATIONS AND RESULTS

CASE 1: Lobster claw hands and feet

General Physical examination revealed malformations of both hands and feet. (fig2)

A) X-ray of the hand impression (fig3).

There is a simple soft tissue syndactyly involving 4th and 5th digits on both the sides. Agenesis of 1st, 2nd & 3rd Digits on both the sides. An extra metacarpal noted on the right side.

B) X-ray of the feet impression (fig3)

There is complex syndactyly of 1st and 2nd, 4th and 5th digits. Agenesis of third meta carpal and digit.

Typical V-shaped lobster claw feet was observed.

C) Genetic report (fig2):

The Cytogenetic analysis shows 46,xx,22p+ female karyotype with band resolution of (ISCN 2013) 500.

CASE 2: Lobster claw feet(fig4) .

The General Physical examination revealed malformations of both feet. Both the hands are normal.

A) X-ray of the hand normal(fig5)

B) X-ray of the feet (fig5):

Left side: 4th and 5th toes fused with single set phalanges for both the toes.

Right side: 1st and 2nd toes are fused to form a single toe with two separate set of phalanges for both the toes.

An atypical V-shaped lobster foot was observed.

C) **Genetic report** (fig4):

The Cytogenetic analysis shows 46,xx normal female karyotype with band resolution of (ISCN 2013) 500.

Pedigree chart for CASE 1 and CASE 2 results:

A) Showing four generations.

B) Consanguineous marriage between parents of case 1 and case 2 belongs to second and third generation are with normal phenotype.

C) Affected siblings(sisters) are from fourth generation.

D) Pedigree chart shows a spontaneous abortion between the affected siblings

E) It is also observed a death of six years girl child affected by carcinoma of the skin in the fourth generation in the adjacent family.

Impression : autosomal recessive inheritance.

Fig. 1: Sisters with Lobster (Split) Hand/Foot.



Fig. 2: Case 1: lobster (Split) hand/foot Karyotype: Cytogenetic analysis shows 46,XX,22p+.

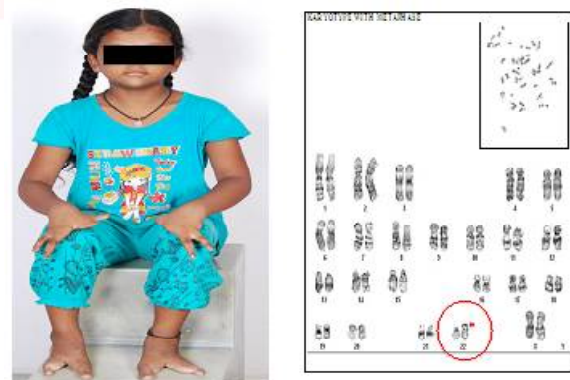


Fig. 3: Case 1 Radiograph of Hand and Foot.

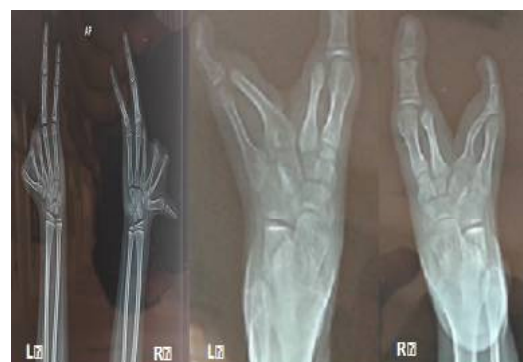

Fig. 4: Case2: lobster foot Karyotype : Cytogenetic analysis shows 46 XX.

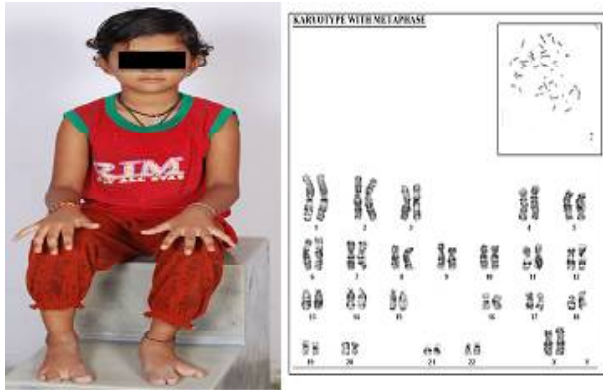
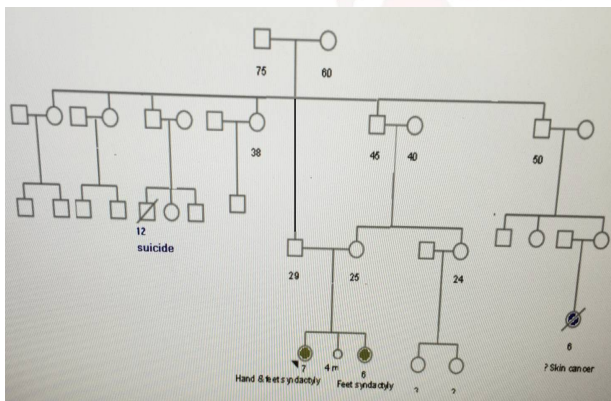


Fig. 5: Case 2: Radiograph of Hand and Foot.

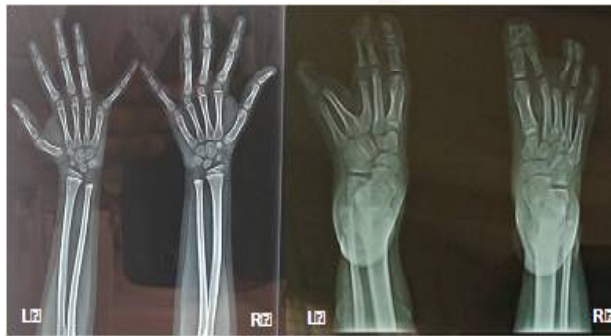

Fig. 6: Pedigree of Case 1 & Case 2: showing Autosomal Recessive trait in the 4th generation.



DISCUSSION

The English name of Ectrodactyly is lobster claw deformity or split hand/ foot malformation. This congenital human limb anomaly was first described in 1936. The Incidence of Ectrodactyly 1 in 90,000 live births [5,6].

The Rudimentary upper and lower limb buds appear as a small out pocketings from the ventro lateral part of the embryonic fetus body wall at around fourth week of intra uterine life. The upper limb bud appears at 24th day opposite to C4 - T2 somites and lower limb buds develop at 28th day opposite to L1 - S3 somites. Homeobox containing HOX gene regulate the pattern of limb development

The role of HOX gene in the limb development is illustrated by two abnormal phenotypes produced by mutations in these genes. HOXA 13 results in hand /foot genital syndrome affected females have bicornuate or didelphic divided uterus with abnormal urethral orifice. Affected males have hypospadias with mutations in HOXD 13 [7]. The SHFM cases occur sporadically, majority showing autosomal dominance inheritance while some autosomal recessive or X-linked inheritance [8,9].

Peculiar patterns of transmission have been reported in SHFM pedigree charts in which 30% are obligate carriers with no phenotypic abnormality [10].

Familial Ectrodactyly is sporadic in nature. The SHFM occurs as isolated entity or as a part of syndrome or in combination of anomalies. The Different phenotypes ranging from mild abnormalities of single limb to severe defects of all four limbs. Excessive transmission of SHFM from affected father to sons has been detected in some pedigrees [11].

The HOXD gene expresses the distal limb bud development, post axial and pre axial border of the limb bud. Therefore HOXD gene domains can be distinguished and prompted to suggest why they should be five fingers and toes. The mutation of this gene leads to syndactyly or polydactyly expression or missing of the fingers or toes [12].

The combination of Ectrodactyly or lobster claw deformity, ectodermal dysplasia and with cleft lip with or without cleft palate (EEC syndrome) is a rare type of congenital anomaly occurs as an autosomal dominant trait or less commonly in sporadic form. In this complex any of the three cardinal manifestations maybe present with variable expression management of EEC syndrome requires multidisciplinary approach [13].

EEC syndrome was first described by Cockayne in 1936 but the acronym was coined by Rudiger et.al [13,14].

The apparent origin of this disease lies in the mutation of chromosome 3q27 that regulates ectodermal development [15].

Gene development malformations do not interfere with reproductive life. However medical literature shows sporadic for familial phenotypes

with malformations of the limbs. Split hand deformity is inherited as an autosomal dominant or as an X linked recessive trait or as random mutation. When one limb is affected the cause is new gene mutation where as two or four limbs are affected the cause is often an inherited gene mutation. Many studies postulated that syndactyly and cleft hand and foot have the same teratogenic mechanism [16].

The current study reports two female siblings from consanguineous marriage, first sister presented with affecting of all four limbs with abnormal genetic report 46,xx,22p+ and the second sister had only lower limb defect with normal genetic report 46xx. Both the siblings were not associated with manifestation of EEC syndrome with no visible cleft lip or ectodermal dysplasia and were diagnosed as lobster claw hand/ foot malformations. Probably the manifestations of lobster claw deformity in the siblings may be autosomal recessive inheritance as parents were from consanguineous marriage.

CONCLUSION

The clinical and cytogenetic description of these two patients requires a proper surgical approach that includes an orthopedicians and plastic surgeons for cosmetic purpose.

In present days limb anomalies are detected by high-resolution ultra sound examination of the developing fetus. Prevention can be achieved by proper genetic counseling which includes risk in reoccurrence in subsequent pregnancies. The morpho-etiology of this study can provide a valuable additional data to the anatomical literature.

ACKNOWLEDGEMENTS

I Humbly acknowledge my two patients and their parents who cooperated to write this article. I also thank to Genetic and Radiology departments.

Conflicts of Interests: None

REFERENCES

- [1]. M.J.Cyrlac, E.Lashpa. Lobster- claw hand: A manifestation of EEC syndrome. *Indian J Dermatol Venereal Leprol.* January- February 2006;72:1.
- [2]. Moore Keith L, Persaud T.V.N: The developing human clinically oriented embryology, Chapter 17, The Limbs, 7th Edition, SAUNDERS First Indian Reprint 2003, pp 410-23.
- [3]. Michael A et al. Characterization of the split hand / split foot malformation locus SHFM1 at 7q21.3-q22.1 and analysis of a candidate gene for its expression during limb development. *Human Molecular Genetics.* 1996;5(5):571-579.
- [4]. Henrion R, and et al. Prenatal diagnosis of Ectrodactyly. *Lancet* 1980;2:319 (Medline).
- [5]. Arbus J. and et al. Typical isolated Ectrodactyly of hands and feet: early antenatal diagnosis: *Journal of maternal fetal neonatal medicine,* 2005;17:299-01(Medline).
- [6]. Pinette Micheal, and et al. Familial Ectrodactyly: *Journal of ultrasound medicine* November 1, 2006;25(11):1465-67.
- [7]. Langmans Medical Embryology T.W. Sadler, edition 13th chapter 12, Lippincott Willkins published by wolters kulwer Health India private ltd. New Delhi 2011, 170-171.
- [8]. Verma, I., Joseph, R., Bhargava, S. and Mehta, S. Split -hand /split- foot deformity inherited as an autosomal recessive trait. *Clini.Genet.*, 1976;9:8-14.
- [9]. Faiyaz-ul-Haque, M., Uhlhaas, S., Knapp, M., Schuler, HJ., Friedl, W., Ahmad, M. and Propping, P.(1993) Mapping of the gene for X-chromosomal split-hand/ split-foot anomaly to Xq26-q26.1. *Hum. Genet.*, 1993;91:17-19.
- [10]. Temtamy, S.A and McKusick, V.A. In the Genetics of Hand malformations. Alan R. Liss, Inc., New York, 1978;53-71.
- [11]. Jarvik, G.P., Patton, M.A., Homfray, T. and Evans, J.P.(1994) Non -mendelian transmission in a human developmental disorder: split hand /split foot. *Am.J.Hum. Genet.*, 1994;55:710-713.
- [12]. Susan Standring. *Gray's Anatomy, 40th Edition. Anatomical basis of clinical practice,* Churchill livingstone, London.2008;51:902.
- [13]. Rudiger RA , Haase W , Passarge E. Association of Ectrodactyly , ectodermal dysplasia and cleft lip-palate – the EEC syndrome. *Am J Dis Child* 1970;120:160-3.
- [14]. Cockayne EA. Cleft palate -lip , hare lip , dacryocystitis, and cleft hand and foot. *Biometrika* 1936;28:60-3.
- [15]. South AP, Ashton GH, Willoughby C, Ellis IH, Bleck O, Hamada T, et al. EEC(Ectrodactyly, Ectodermal dysplasia, Clefting) syndrome: heterozygous mutation in the p63 gene (R279H) and DNA- based prenatal diagnosis. *Br J Dermatol.* 2002;146:216-20.
- [16]. Karl-Heinz Grzeschik Human limb malformations; an approach to the molecular basis of development *Int.J.Dev.Biol.* 2002;46:983-991.

How to cite this article: M.Yesender, N.Himabindu, S.Saritha, B. Sadananda rao, T.V. Ramani, Nagajyothi. CHARACTERIZATION OF LOBSTER HAND/FOOT MALFORMATIONS WITH GENETIC EXPRESSION: A FAMILIAL STUDY. *Int J Anat Res* 2017;5(1):3457-3460. **DOI:** 10.16965/ijar.2016.428