

MORPHOLOGICAL VARIATIONS AND MORPHOMETRIC ANALYSIS OF FORAMEN OVALE WITH ITS CLINICAL IMPLICATIONS

B Sadananda Rao ^{*1}, M Yesender ¹, B H Shiny Vinila ².

^{*1} Associate Professor, Department of Anatomy, Kamineni Academy of Medical Sciences, Hyderabad, Telangana, India.

² Senior Lecturer, Department of Anatomy, Panineeya Mahavidyalaya Institute of Dental Sciences and Research Center, Hyderabad, Telangana, India.

ABSTRACT

Background: Foramen ovale (FO) plays an important role in the diagnostic and surgical procedures related to middle cranial fossa. So the knowledge on the variations, dimensions and the topographic location is must to the neurosurgeons while dealing with this region. The present study aimed at finding the anatomical variations, dimensions and the location of foramen ovale.

Materials and Methods: Present study was carried out on 100 foramina ovalia using 50 dry adult human skulls of South Indian origin. The incidence of the presence of any accessory bony structure like bony plate, spine, tubercle and septa were noted. The size of the foramen ovale was measured by taking Antero-posterior length and the width. The location was determined by measuring the distance from the centre of the foramen ovale (CF) to the tubercle of root of zygoma and distance from the CF to the midline of the base of the skull bilaterally using double tipped compass and digital vernier calipers.

Results: Among 50 skulls studied 4 skulls (8%) were bearing bony structures in which 2 skulls (4%) were showing the complete septum dividing the foramen ovale into two parts and in 2 skulls (4%) bony spines were observed which were partially covering the foramen ovale bilaterally. The average anteroposterior length of FO was 7.17 ± 0.94 mm and the width was 3.75 ± 0.69 mm. The average distance from the centre of foramen ovale to the tubercle of root of zygoma was 33.04 ± 2.11 mm and the average distance from the centre of foramen ovale to the midline of the base of the skull was 24.26 ± 1.68 mm. There was no significant difference between the right and left sides.

Conclusion: Proper knowledge on the location, dimensions and variations of foramen ovale will be providing guidance to neurosurgeons while performing various procedures through foramen ovale.

KEY WORDS: Foramen ovale (FO), Anatomical variations, Neurosurgeons, Tubercle of root of zygoma.

Address for Correspondence: B Sadananda Rao, Associate Professor, Department of Anatomy, Kamineni Academy of Medical Sciences, L B Nagar, Hyderabad, Telangana, India.
Contact number: 9908892376 **E-Mail:** sadanand.anat@gmail.com

Access this Article online

Quick Response code



DOI: 10.16965/ijar.2016.487

Web site: International Journal of Anatomy and Research
ISSN 2321-4287
www.ijmhr.org/ijar.htm

Received: 22 Nov 2016
Peer Review: 22 Nov 2016
Revised: None

Accepted: 20 Dec 2016
Published (O): 31 Jan 2017
Published (P): 31 Jan 2017

INTRODUCTION

Foramen ovale (FO) is located in the greater wing of the sphenoid bone, posteriolateral to the foramen rotundum which opens into the infratemporal fossa. Mandibular nerve, the

accessory meningeal artery, lesser petrosal nerve and an emissary vein passes through the foramen ovale [1-3]. The foramen ovale is not present in the class reptilia and was acquired in mammal during the process of evolution. The

foramen is absent in some living mammals including the mammalian embryo, where the semilunar ganglion develops outside the skull and its intracranial position is secondary in ontogeny. Exit of mandibular nerve through foramen ovale is an advanced character acquired during the evolution process [4].

Knowledge on the development of foramen ovale in humans is important to know its topography, morphology and the morphological variations. The foramen ovale is located in the greater wing of sphenoid bone. This sphenoid bone develops from both intramembranous and endochondral ossification centers. Sphenoid consists of the body, the paired lesser wings and the greater wings. The basis sphenoid is derived mainly from presphenoid and postsphenoid centres and the postsphenoid centre is the one which is associated with the development of the greater wing of sphenoid. The first ossification centre appears for the greater wing of sphenoid by membranous ossification. The mandibular nerve becomes surrounded by cartilage to form the foramen ovale. At 22 weeks of age the foramen ovale can be seen as discrete ring shaped opening in the area of unossified cartilage that can be well recognised by 3 years after birth [5,6]. The morphological variations of the foramen ovale, such that it can be occasionally covered by ossified ligaments stretching between the lateral pterygoid process and the spine of sphenoid resulting in the formation of double foramen ovale [7,8].

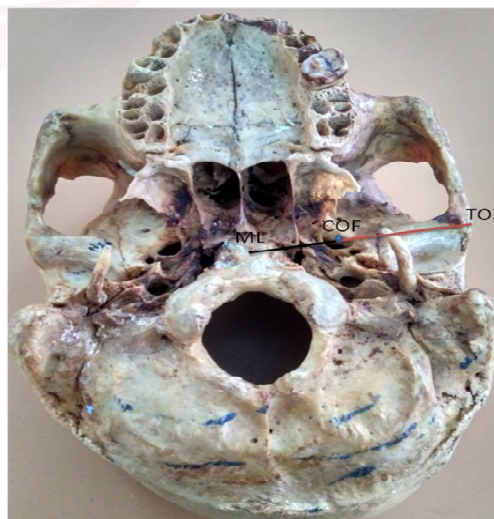Foramen ovale plays an important role in many neurosurgical and diagnostic procedures related to middle cranial fossa. Electroencephalographic analysis of seizure by placing electrode at FO provided good neurophysiological information in candidates for selective amygdalo-hippocampectomy [9]. 100% success rate was achieved in the treatment of trigeminal neuralgia when foramen ovale was punctured with the help of radiofrequency ablation under the guidance of X-ray real time imaging [10]. Foramen ovale permits biopsy of deep lesions of middle cranial fossa such as biopsy of cavernous tumors, percutaneous trigeminal rhizotomy for trigeminal neuralgia due to easy access of the gasserian ganglion through CT guided fine needle aspiration technique which is better than

the open surgical biopsy or craniotomy, thus decreasing cost and patient morbidity [11-14]. The present study was carried out to provide proper knowledge on the location, dimensions and variations of foramen ovale, which will be providing guidance to neurosurgeons while performing various procedures through foramen ovale.

MATERIALS AND METHODS

Present study was carried out on 100 foramina ovalia using 50 dry adult human skulls of South Indian origin. Skulls with damage at the surroundings of foramen ovale were excluded from the study. All the skulls were observed to note the presence of any accessory bony structure like bony plate, spine, tubercle and septa. The size of the FO was measured by taking Antero-posterior length and the width. The location was determined by measuring following parameters. Distance from the centre of the foramen ovale (COF) to the tubercle of root of zygoma and distance from the COF to the midline of the base of the skull was also measured bilaterally using double tipped compass and digital vernier calipers (Figure 1).

Fig. 1: Distance from the centre of the foramen ovale (COF) to the tubercle of root of zygoma (TOZ) and distance from the COF to the midline (ML) of the base of the skull.



RESULTS

Among 50 skulls studied 4 skulls (8%) were bearing bony structures around FO. 2 skulls (4%) were showing the complete septum dividing the foramen ovale into two parts (Figure 2) and in 2 skulls (4%) bony spines were observed which were partially covering the foramen ovale bilaterally (Figure 3).

Fig. 2: Arrows showing the septa dividing the FO into 2 foramina. (Green probe - Foramen ovale; Blue probe – Accessory foramen ovale; White probe – Foramen spinosum).

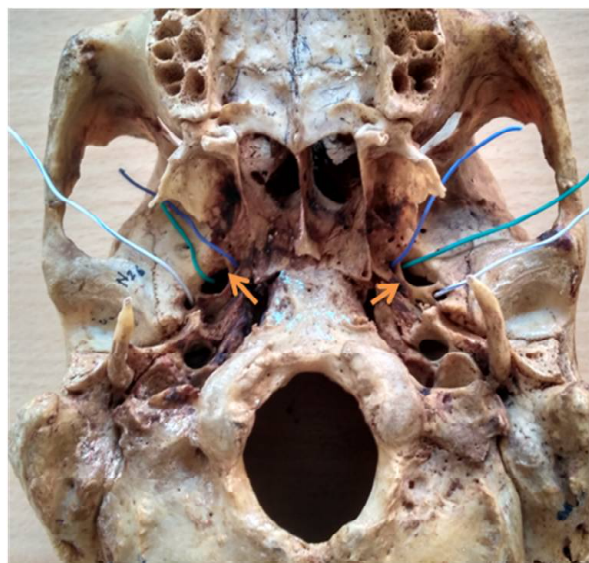
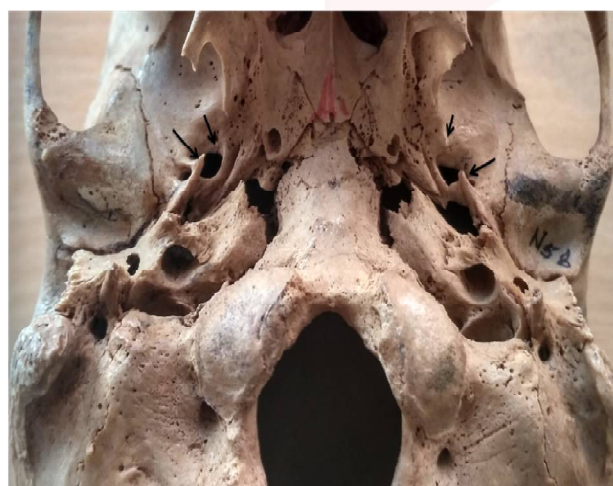

Fig. 3: Arrows showing the spines partially covering the foramen ovale bilaterally.



The average anteroposterior length of FO was 7.17 ± 0.94 mm and the width was 3.75 ± 0.69 mm. There was no significant difference in the anteroposterior length and width of foramen ovale in between the right and left sides.

Table 1: Mean and standard deviations of the anteroposterior length and width of the foramen ovale.

Dimensions	Right side	Left side
Anteroposterior length	7.24 ± 0.89 mm	7.11 ± 1.00 mm
Width	3.75 ± 0.71 mm	3.75 ± 0.67 mm

The average distance from the centre of foramen ovale to the tubercle of root of zygoma was 33.04 ± 2.11 mm and the average distance from the centre of foramen ovale to the midline of the base of the skull was 24.26 ± 1.68 mm. There was no significant difference between the right and left sides.

Table 2: Showing the mean and standard deviations of the various parameters to locate the foramen ovale.

Parameter	Right side	Left side
CF to the tubercle of root of zygoma	32.99 ± 2.07 mm	33.08 ± 2.17 mm
CF to the midline of the base of the skull	24.28 ± 1.55 mm	24.24 ± 1.83 mm

DISCUSSION

Foramen ovale is one of the important foramina situated in the greater wing of sphenoid bone through which middle cranial fossa can be approached for micro neuro surgical and diagnostic procedures without performing craniotomy. So the knowledge of anatomical variations, location and diameters of foramen ovale is essential for surgeons.

In the present study 8 % of skulls were bearing bony structures around FO among that bony tubercles were observed in 4% of cases bilaterally and complete septum dividing the foramen into 2 parts was observed in 4% cases bilaterally. Presence of bony structures around the foramen ovale may manipulate the anatomical organization of the nerves transmitted through the foramen namely mandibular and lesser petrosal nerves which often results in the lateral disposition of mandibular nerve resulting in the entrapment of its branches between bony structure and the neighbouring muscles which might lead to neuralgia [15].

The size of the foramen ovale in the present study was determined by measuring maximum anteroposterior length and maximum width. The anteroposterior length was ranging from 5.71 to 9.46mm where as width was ranging from 2.42 to 6.61mm. Narrow size of foramen ovale is a common manifestation in the clinical scenario of Paget's disease or osteopetrosis [16]. The average anteroposterior length and width of FO were 7.17 ± 0.94 mm and 3.75 ± 0.69 mm respectively. Our results were coinciding with the study of Suniti Raj Mishra et al., where the mean length was 7.5mm and width was 4.2mm [17]. The anteroposterior length of the present study was lesser than the study by Magi muruganet al., where it was 8.4mm [5]. Karishma Ravintha et al., reported the mean length on right side as 6.7mm and left side 5.7mm whereas width was 3.56mm on right side and 4.28mm on left side which were less when compared to the results of the present study [18].

Localizing the exact position of foramen ovale is important for various surgical and diagnostic procedures. In the present study the distance from the tubercle of root of zygoma to center of FO and the distance between the midline to center of FO was considered to locate the FO. The average distance between the centre of foramen ovale to the tubercle of root of zygoma was 32.99 ± 2.07 mm on right side and 33.08 ± 2.17 mm on left side which was correlating with study of Jyothsna Patil et al., where it was observed to be 32.58 ± 1.72 mm on right side and 32.75 ± 1.76 mm on left side. The average distance between the centre of FO to midline was also correlating with the Jyothsna Patil et al. [19].

CONCLUSION

The variations observed in the present study and the data on its location and dimension is of immense value to the neurosurgeons while performing various diagnostic and surgical procedures through foramen ovale. The distance measured between the centre of foramen ovale to the tubercle of root of zygoma provides guidance to the neurosurgeons while performing trans zygomatic approach of foramen ovale to reach the middle cranial fossa.

Conflicts of Interests: None

REFERENCES

- [1]. Reymond J, Charuta A, Wysocki J: The morphology and morphometry of the foramina of the greater wing of the human sphenoid bone. *Folia Morphologica*. 2005;64(3):188-193.
- [2]. Soames RW: *Gray's Anatomy of the Human Body*, 38th ed. London: Churchill Livingstone. 1995;425-736
- [3]. Standring S. *The Anatomical Basis of Clinical Practice*, Gray's Anatomy, 39th edit. Elsevier Limited. 2006;460-462.
- [4]. Edinger T, Kitts DB. The foramen ovale. *Evolution*. 1954;8:389-404.
- [5]. Magi Murugan, Shaik Hussain Sahe. Morphometric and morphological study on foramen ovale. *International journal of anatomy and research*. 2014;2(4):664-67.
- [6]. Yanagi S. Developmental studies on the foramen rotundum, foramen ovale and foramen spinosum of the human sphenoid bone. *The Hokkaido Journal of Medical Science*. 1987;62(3):485-496.
- [7]. Blaszczyk B, Kaszuba A, Kochanowski J. Atypical foramina of the base of the skull. *Folia Morphol*. 1980;93:201-209.
- [8]. Kapur E, Dilberovic F, Redzepagic S, Berhamovic E. Variation in the lateral plate of the pterygoid process and the lateral subzygomatic approach to the mandibular nerve. *Med Arh*. 2000;54:133-137.
- [9]. Wieser HG, Siegel AM. Analysis of foramen ovale electrode-recorded seizures and correlation with outcome following amygdalohippocampectomy. *Epilepsia*. 1991;32: 838-50.
- [10]. He YQ, He S, Shen YX. Application of a new method of revealing foramen ovale under X-ray in radiofrequency ablation in the treatment of trigeminal neuralgia. *Br J Neurosurg*. 2011;25(6):674-6.
- [11]. Dresel SH, Mackey JK, Lufkin RB, Jabour BA, Desalles AA, Layfield LJ, et al. Meckel cave lesions: Percutaneous fine needle-aspiration biopsy cytology. *Radiology*. 1991;179:579-82.
- [12]. Barakos JA, Dillon WP. Lesions of the foramen ovale: CT-guided fine-needle aspiration. *Radiology*. 1992;182:573-575.
- [13]. Yi W, Ohman K, Brännström T, Bergenheim AT. Percutaneous biopsy of cavernous sinus tumor via the foramen ovale. *Acta Neurochir (Wien)*. 2009;151(4):401-7.
- [14]. Gusmao S, Oliveira M, Tazinaffo U, Honey CR. Percutaneous trigeminal nerve radiofrequency rhizotomy guided by computerized tomography fluoroscopy: Technical note. *J Neurosurg*. 2003;99:785-786.
- [15]. Krmpotic, Nemanic J, Vinter J, Hat J, Jalsovec. Mandibular neuralgia due to anatomical variation. *Eur Arch Otorhinolaryngol*. 1999;256:205-08.
- [16]. Kim JS, Lee MK, Bae YH, Kim DJ. Trigeminal neuralgia in a patient with osteoporosis. *J Koreana Neurosurg Soc*. 1998;27:1147-51.
- [17]. Suniti Raj Mishra, Sushobhana, Shailendra Singh, Raveena Singh, Anamika Gaharwar. Morphometric and Topographic Study of Foramen Ovale in Indian Skulls. *Malaysian Journal of Medical and Biological Research*. 2016;3(2):75-84.
- [18]. Karishma Ravinthar, Thenmozhi. Morphometric Study of Size and Symmetry of Foramen Ovale in Dry Skulls. *Journal of pharmaceutical science of research*. 2015;7(10):830-833.
- [19]. Jyothsna Patil, Naveen Kumar, Mohandas Rao K.G, Swamy Ravindra S, Somayaji S N, Satheesha Nayak B, Sapna Marpalli, Ashwini L.S. The Foramen Ovale Morphometry of Sphenoid Bone in South Indian Population. *Journal of Clinical and Diagnostic Research*. 2013;7(12):2668-2670.

How to cite this article:

B Sadananda Rao, M Yesender, B H Shiny Vinila. MORPHOLOGICAL VARIATIONS AND MORPHOMETRIC ANALYSIS OF FORAMEN OVALE WITH ITS CLINICAL IMPLICATIONS. *Int J Anat Res* 2017;5(1):3394-3397. DOI: 10.16965/ijar.2016.487