International Journal of Anatomy and Research,
Int J Anat Res 2017, Vol 5(2.1):3759-65. ISSN 2321-4287
DOI: https://dx.doi.org/10.16965/ijar.2017.169

Original Research Article

MORPHOMETRIC STUDY OF GLENOID CAVITIES OF SCAPULAE IN MARATHWADA POPULATION

S.N.Shewale *[1], Md. Laeeque [2], S.B.Sukre [3], S.C.Patil [4].

*[1] Assistant Professor, Department of Anatomy, Government Medical College, Aurangabad, Maharashtra, India.

[2] Associate Professor, Department of Anatomy, Government Medical College, Aurangabad, Maharashtra, India.

[3] Professor and Head, Department of Anatomy, Government Medical College, Aurangabad, Maharashtra, India.

[4] Tutor, Department of Anatomy, Government Medical College, Aurangabad, Maharashtra, India.

ABSTRACT

Background: Morphometric study of glenoid cavity in 142 dry human scapulae of known sex in Marathwada population to calculate the various diameters of glenoid cavity.

Materials and Methods: This study was done on 142 dry human scapulae (102 were of males and 40 were of females) available in Bone bank of Department of Anatomy at Govt. Medical College, Aurangabad. The three glenoid diameters measured were the superior-inferior diameter, antero-posterior diameter (AP-I) of lower half and antero-posterior diameter (AP-II) of upper half of the glenoid cavity. The morphometric values were analyzed statistically by using unpaired t-test.

Results: All the three glenoid diameters studied were statistically significant with P value <0.005. The mean superior-inferior diameter of glenoid cavity in males and females were 35.95±2.3mm and 31±2.5mm respectively. The mean AP-I diameter of glenoid cavity was 24.6±1.96mm in males and 20.3±2.25mm in females. The mean AP-II diameter of glenoid cavity was 17.46±2.52mm in males and 14.8±1.91mm in females.

Conclusion: All the values observed in the present study were more in male glenoids as compared to female glenoids. Most of the previous workers studied the parameters on left and right scapulae separately. The differences seen between values of the present study and that of the other groups could be explained on the basis of gender segregation, ethnic and racial variations. This fact should be kept in mind while designing glenoid prosthesis for different population.

KEY WORDS: Glenoid Cavity, Shoulder Arthroplasty, Scapula.

Address for Correspondence: Dr.S.N.Shewale, Assistant Professor, Department of Anatomy, Government Medical College, Aurangabad, Maharashtra, India. Mobile no: 9860249148
E-Mail: shilpashewale11@gmail.com

Access this Article online

Quick Response code

DOI: 10.16965/ijar.2017.169

Web site: International Journal of Anatomy and Research
ISSN 2321-4287
www.ijmhr.org/ijar.htm

Received: 03 Mar 2017
Peer Review: 03 Mar 2017
Revised: None

Accepted: 03 Apr 2017
Published (O): 30 Apr 2017
Published (P): 30 Apr 2017

INTRODUCTION

The Scapula a large, flat, triangular bone lies on the posterior chest wall between the level of second and seventh ribs. It has two surfaces, three borders and three angles. The three angles are medial, inferior & lateral. The lateral angle is truncated & broad which is considered as head of scapula. It has shallow glenoid cavity

which provides socket for head of humerus to form shoulder joint. It is pyriform in shape, narrower above as compared to lower part [1].

Morphologically various shapes of glenoid cavities are observed. Anterior margin of glenoid rim has a notch in its upper part [2]. Depending on prominence of glenoid notch, various shapes of glenoid cavity were observed like pear-shaped, oval or inverted comma shaped [3,4].

The glenoid margin provides attachment to glenoid labrum, a fibro-cartilaginous rim except at the supra-glenoid tubercle. The glenoid labrum makes the glenoid cavity deep for the head of humerus.

The fibrous capsule of shoulder joint is attached around the periphery of glenoid cavity outside the labrum, so it includes supraglenoid tubercle but excludes the infraglenoid tubercle. The laxity of fibrous capsule and shallow glenoid cavity provides great range of mobility to the joint, but loses its stability. The stability of the joint is maintained by various factors such as coraco-acromial arch, glenoid labrum and musculo-tendinous cuff. Most frequently shoulder joint is dislocated inferiorly as it is having less support in this region [5]. Dislocation of joint is mostly associated with the fracture of glenoid cavity. For the management of such injuries, prosthesis, arthroplasty and rotator cuff tear repairs are frequently required. The “total shoulder replacement” is also treatment of choice [6-8]. The detailed knowledge of different shapes &various diameters of glenoid cavity is an important factor for designing & fitting of glenoid component for total shoulder arthroplasty.

Total shoulder replacement gives a predictable relief in pain and function in patients with degenerative shoulder disease and rotator cuff intact.

The presence of notch on anterior margin of glenoid rim gives different shapes of glenoid cavity. When it is prominent, it gives inverted comma shape and the glenoid labrum is not fixed to glenoid rim properly but bridge the notch. This may be the one of the causes of dislocations of shoulder joint [7].

The aim of present study was to collect morphometrical data of glenoid cavity including the different diameters of glenoid cavity in Marathwada region and to compare the data obtained in present study with earlier studies.

MATERIALS AND METHODS

The study was performed on 142 dry human scapulae of known sex belonging to Marathwada population in Department of Anatomy, Govt. Medical College, Aurangabad (Maharashtra). The scapulae were of adult and of known sex. Out of these, 40 were of female and 102 were of male. All the scapulae studied were dry, complete and showed normal anatomical features. Broken, damaged or scapulae showing degenerative changes were excluded from the study. Scapulae having clear and intact glenoid cavity were selected for the study. All the measurements were carried out manually with the help of digital vernier callipers. The readings were taken in millimeters.

The following parameters of glenoid cavity were studied:

Superior-Inferior glenoid diameter(SI): It was measured as maximum distance between the most prominent point of supra-glenoid tubercle to inferior margin of glenoid cavity in the same vertical plane.(Fig.1)

Fig. 1: Showing measurement of the Superior-Inferior (SI) Glenoid Diameter.

Antero-posterior glenoid diameter (AP-I): It was measured as maximum breadth of the articular margin of the glenoid cavity perpendicular to the glenoid cavity height in lower half. (Fig. 2)

Fig. 2: Showing measurement of the Anerior-Posterior (AP-I) Glenoid Diameter.

Antero-posterior glenoid diameter (AP-II): It was measured as breadth of the upper half of the glenoid cavity at the mid-point between superior margin and mid-equator. (Fig. 3)

Fig. 3: Showing measurement of the Anterior-Posterior (AP-II) Glenoid Diameter.

Fig. 4: Various diameters of Glenoid cavity.

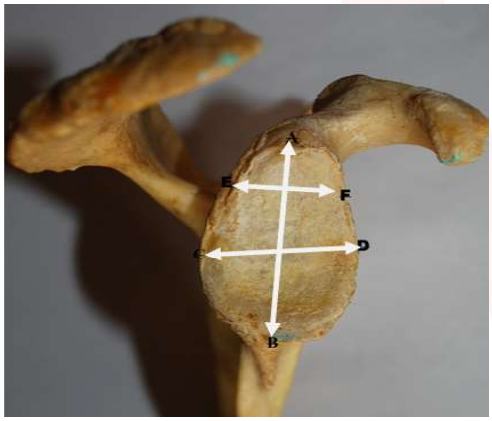

A-B: Superior-inferior diameter (SI)
C-D: Anterior-Posterior diameter(AP-I)
E-F: Anterior-Posterior diameter(AP-II)

OBSERVATION AND RESULTS

A total of 142 dry human scapulae were studied. Out of these 40 were of females and 102 were of males. The supero-inferior diameter, antero-posterior I and antero-posterior II diameters of glenoid cavity were studied. The mean & standard deviation of the diameters of the glenoid cavity were calculated and tabulated. The morphometric values were analyzed using an unpaired t-test.

Supero-inferior (SI) diameter: In present study, SI diameter in male & female was statistically significant with p value < 0.05. The superior-inferior diameter of glenoid cavity in males varied from 28.4 mm to 41.6 mm with a mean of 35.95±2.3 mm. The statistical value of mean±3 SD is 29.05-42.85mm. The demarcating point for male was > 38.5mm.

The SI diameter of glenoid cavity in female was in the range of 22.2mm to 34.5 mm with a mean of 31±2.5 mm. The statistical value of mean ± 3 SD is 23.50-38.5mm. The demarcating point for female was < 29.05mm.

Table 1: SI diameters in males & females.

	Male	Female
Range (mm)	28.4 to 41.6	22.2 to 34.5
Mean ± SD (mm)	35.95±2.3	31±2.5
Mean ± SD (mm)	29.05-42.85	23.50-38.5.
D.P. (mm)	> 38.5.	< 29.05
P value	< 0.05	< 0.05

Antero-posterior (AP-I) diameter: In present study, Antero-posterior(AP-I) diameter in male & female was statistically significant as having P value < 0.05.

AP-I diameter in glenoid cavity in males varied from 16.9 mm to 29.6 mm with mean of 24.6± 1.96 mm. The statistical value of AP-I diameter mean ± 3SD was 18.7-30.5 mm. The demarcating point for AP-I in males was > 27.05mm.

The AP-I diameter in females ranged between 12.8 mm to 23.7 mm with a mean of 20.3± 2.25 mm. The statistical value of AP-I diameter mean ±3 SD was 13.55-27.05mm. The demarcating point for AP-I in females was < 18.7.

Table 2: AP-I diameters in males & females.

	Male (mm)	Female (mm)
Range (mm)	16.9 to 29.6	12.8 to 23.7
Mean ± SD (mm)	24.6±1.96	20.3±2.25
Mean ± SD (mm)	18.7-30.5	13.55-27.05
D.P. (mm)	> 27.05	< 18.7
P value	< 0.05	< 0.05

Scale is in mm.

Antero-posterior (AP-II) diameter: In present study, AP-II diameter is statistically significant

as having P value < 0.05.The range of AP-II diameter in male glenoids was 11.3 mm to 21.3 mm with a mean of 17.46 ± 2.52 mm. The value of mean ±3 SD was 9.9-2.5 mm. The demarcating point for AP-II diameter for males was > 20.53mm.

The range of AP-II diameter in female glenoids was 9.7mm to 18.4mm with a mean of 14.8± 1.91 mm. The value of mean ±3SD was 9.07-20.53 mm. The demarcating point for AP-II diameter for females was < 9.9mm.

Table 3: AP-II diameters in males & females.

	Male	Female
Range (mm)	11.3 to 21.3	9.7 to 18.4
Mean ± SD (mm)	17.46±2.52	14.8±1.91
Mean ± SD (mm)	9.9-25	9.07-20.53
D.P. (mm)	> 20.53	< 9.9
P value	< 0.05	< 0.05

DISCUSSION

In present study, various diameters of glenoid cavity were studied and compared these diameters with others which were done previously by various workers. Various workers used various methods to study glenoid cavity including direct measurements on dry scapulae, direct measurements on scapulae derived from embalmed bodies and radiographic measurements in living individuals. These studies were done on different groups and different races of population. The present study was done on Marathwada population. The data obtained in present study was compared with others, differences and similarities in the observations of present study and previous studies were noted. The differences may be due to different group of population studied and different methods of measurements used.

Superior-inferior (SI) Diameters: In the present study, mean SI diameter of glenoid cavity in males was 35.95± 2.3mm and in females was 31±2.5mm.

The average SI diameter of male glenoids measured by Churchill et al [9] was 37.5±2.2mm, L R Frutos [10] was 36.08±2mm and Ozer et al [11] was 38.71±2.71mm. The average diameter in males observed in present study was similar to L R Frutos [10] study.

The SI diameter of female glenoids measured by Churchill et al [9] was 32.6±1.8mm, LR Frutos [10] was 31.17±1.7mm and Ozer et al [11] was 33.79±3.8mm. The finding of present study in females was more or less similar to these studies. The findings are corroborative with previous studies that SI diameter was more in male glenoids as compared to female glenoids. This may be due to small size or built of female glenoids.

Various workers observed SI diameter in right and left glenoid cavities. Rajput et al [8] observed mean SI diameter (in Gujarat population) on right side was 34.76±3mm and on left side was 34.43±3.21mm. Kavita et al [12] observed mean SI diameter in right glenoids was 35.2±3mm and in left glenoids was 34.7±2.8mm. Gosavi et al [13] reported mean SI diameter of both sides was 35.16mm. The findings in this study were very near to that of present study. Neeta Chhabra et al [14] had values of average SI diameter on right glenoids 38.46±2.81mm and left glenoids 39.03±3.18mm. The values are more than in the present study. Mallon et al[15] and Md. J. Akhtar et al [16] had reported mean SI diameter of glenoid cavity was 35.80±3.14mm and 35±4.1mm respectively which is quite similar to values in current study.

The values on right side were greater than left in various studies. In present study, we compared the SI diameter in male & female glenoid cavities. We observed the value of SI diameter in female glenoids was less as compared to male glenoid which was similar to the previous studies.

Antero-posterior(AP-I) diameter:

The mean AP-I diameter is the maximum diameter of lower half of glenoid cavity. In present study, it was 24.6±1.96 mm in male glenoids and 20.3±2.25 mm in female glenoids. This indicates that the male glenoids were broader than female glenoids.

The mean AP-I diameter was studied by various authors in male and female. Churchill et al [9] recorded mean AP-I 27.8±1.6 mm in male glenoids and 23.6±1.5 mm in female glenoids. The mean AP-I diameter in male glenoids and in female glenoids observed by LR Frutos [10] was 26.31±1.5mm and 22.31±1.4 mm respectively. Ozer et al [11] also studied AP-I diameter in male

Table 4: Comparison of Superior-inferior diameter (SI), Antero-posterior diameter (AP-I), Antero-posterior diameter (AP-II) by various authors.

Sr no.	Author	No. of specimens		Mean SI diameter (mm)	Mean AP-I Diameter (mm)	Mean AP-II diameter (mm)
1	Mallon et al (1992) [15]	28		35± 4.1	24±3.3	`-
2	Rajput H. B. et al (2012) [8]	Right	43	34.76±3	24.31±3.0	15.10±2.54
		Left	57	34.43±3.21	22.92±2.80	13.83±2.45
3	Kavita et al (2013) [12]	Right	67	35.2±3	25.07±2.7	16.8±1.8
		Left	62	34.7±2.8	24.9±2	16.3±2.0
4	Gosavi et al (2014) [13]	Right	62	35.03±5.25	24.17±2.57	14.56±2.03
		Left	80	35.3±3.41	23.9±2.66	14.6±1.85
5	Neeta Chhabra et al(2015) [14]	Right	55	38.46±2.81	25.04±2.69	18.70±2.22
		Left	71	39.03±3.18	24.85±2.46	18.6±2.07
6	Md. Jawed Akhtar et al(2016) [16]	Right	126	36.03±3.15	23.67±2.53	16.30±2.16
		Left	102	35.52±3.12	23.59±2.47	16±2.34
7	Ozer et al (2006) [11]	Male	94	38.71±2.71	27.33±2.4	`-
		Female	92	33.79±3.08	22.72±1.72	`-
8	L R Frutos (2002) [10]	Male	65	36.08±2	26.31±1.5	`-
		Female	38	31.17±1.7	22.31±1.4	`-
9	Churchill et al (2001) [9]	Male	200	37.5±2.2	27.33±2.4	`-
		Female	144	32.6±1.8	27.8±1.6	`-
10	G.V. Patil et al (2014) [17]	Right	`-	`-	`-	15.74±1.75
		Left	`-	`-	`-	16.81±1.74
11	Pranoti Sinha et al (2016) [18]	Right	`-	`-	`-	18.70±2.64
		Left	`-	`-	`-	18.01±2.56
12	Present study (2017)	Male	102	35.95±2.3	23.6±1.5	17.46±2.52
		Female	40	31±2.5	20.3±2.25	14.8±1.91

glenoids and in female glenoid cavities separately and he observed mean AP-I diameter in male was 27.33±2.4mm and in females it was 22.72±1.72 mm. All these studies including present study recorded that AP-I diameter in males were more as compared to female glenoids. This indicated that male glenoid cavities were broader in lower half than female glenoid cavities.Various authors had studies AP-I diameter of glenoid cavities on right & left sides and they didn't specify the sex of the scapulae. Rajput H.B et al [8] observed AP-I diameter 24.31±3.0mm on right side and 22.92±2.80 mm on left side. Kavita et al [12] reported average mean of AP-I diameter of both sides was 24.9±2.5mm .Mallon et al [15] recorded mean AP-I diameter was 24±3.3mm. The values observed by these authors were similar to those in present study.

Gosavi et al [13] observed mean AP-I diameter was 24.17±2.57mm on right side and 23.9 ± 2.66mm on left side. Neeta Chhabra et al [14] had findings 25.04±2.69mm on right and left sides of AP-I diameter respectively. Md. J Akhtar et al [16] observed mean AP-I of both sides was 23.63 +_2.50mm. AP-I diameter observed by Gosavi et al [13] on right side and Neeta Chhabra et al [14] on left side was similar to AP-I diameter in male glenoids in present study. The values observed by Md. J Akhtar [16] were less than present study. Lack of gender segregation is may be the reason of discrepancy Mean AP-I diameter observed by various authors previously was similar to findings in present study.

Antero-posterior(AP-II) diameter:

AP-II diameter is the breadth of the glenoid cavity in its upper half. In present study, mean AP-II diameter of glenoid cavity in males was 17.46± 2.52mm and mean AP-II diameter of glenoid cavity in females was 14.8± 1.91mm.

Various authors studied AP-II diameter on right and left sides. Rajput H.B et al [8] observed AP-II diameter 15.10±2.54mm in right glenoids and 13.83±2.45 mm in left glenoids. Kavita et al [12] observed AP-II diameter 16.8 ±1.8mm in right glenoids and 16.3±2.0mm on left glenoids. G.V. Patil et al [17] had findings 15.74±1.75mm on right side and 16.81± 1.74mm on left side. Rajput H.B et al[8] and Kavita et al [12] observed AP-II diameter was more on right side than left side in contrast to G.V. Patil et al [17] observed AP-II diameter was more on left side.

Neeta Chhabra et al [14] reported mean AP-II diameter was 18.70± 2.22mm in right glenoids

and 18.6 ±2.07mm in left glenoids. Pranoti Sinha et al[18] had readings of 18.70 ±2.64 mm & 18.01±2.56mm on right & left glenoids respectively. The observed values of Neeta Chhabra et al [14] and Pranoti Sinha et al [18] were very much greater than that of observed in present study.

Gosavi S.N. et al [13] observed mean of AP-II diameter was 14.58 mm and Md. J Akhtar [16] observed mean AP-II diameter of both sides was16.17±2.24mm. The value observed by Gosavi S.N. et al [13] was much lower than that observed in the present study.

Neeta Chhabra et al [14] and Pranoti Sinha et al [18] observed that there was not a significant difference in values of AP-II diameter on right and left side glenoids. All the previous studies compared mean AP-II diameter on right & left glenoids and observed that the mean AP-II diameter was greater on right side than left side except G.V. Patil et al [17]. These observations indicated that glenoid cavity was broader above on right side than left side. In present study, we compared the diameters in males and female glenoids. We observed that mean AP-II diameter was greater in male glenoids than in female glenoids. This may be due to greater size of glenoid cavities in male scapulae than in female scapulae.

CONCLUSION

It is important to study the different diameters of glenoid cavity as it may be very helpful to orthopedicians and prosthetists to design and fit to glenoid component during total shoulder arthroplasty. Knowledge of variations in glenoid cavity anatomy is essential to evaluate pathological conditions like Osseous Bankart lesions and osteochondral defects.

The present study was done on 142 dry human scapulae of adults of known sex & the glenoid diameters were studies. The observed glenoid diameters in present study were more or less similar to previous studies done on other groups of populations. Most of the previous studies done in Indian population were of right and left glenoids of unknown sex. The present study was done on male and female glenoids separately as male and female scapulae are available in our bone banks which were collected from different parts of Marathwada region. We observed that the mean values of all the three diameters of glenoid cavity i.e. supero-inferior diameter, Antero-posterior I and II diameters were less in female glenoids as compared to male glenoids. The findings are very much important and these are very useful to orthopedicians and prosthetists. However, the findings may be helpful to orthopedicians and prosthetists to select proper size of prosthesis during shoulder arthroplasty. It should be kept in mind that the prosthesis required for female patients should be of smaller size than that for male patients and further these values can also help in determination of gender from scapulae of unknown deceased residuals particularly in medico legal cases. Since current study was done on smaller number of scapulae as compared to population, it is difficult to conclude these readings as standard. So, further radiological and clinical studies should be conducted.

ABBREVIATIONS

Mm - milimetre
SI - Superior- Inferior glenoid diameter
AP-I - Anterior –Posterior diameter1
AP-II - Anterior- Posterior diameter2
SD - Standard deviation

Conflicts of Interests: None

REFERENCES

[1]. Susan Standring, Pectoral girdle, shoulder region and axilla. Gray's Anatomy : The Anatomical Basis Of clinical Practice 40th ed. Churchill Livingstone Elsevier, 2008;793-6 and 803-7.
[2]. Breathnach AS. Frazer Anatomy of The Human Skeleton 6TH Ed. London: Jand A Churchill Ltd ; 1965;63-70.
[3]. Prescher A, Klumpen T. Theglenoid notch and its relation to the shape of the glenoid cavity of the scapula. J Anat 1997;190(3):457-60.
[4]. Churchill RS, Brems JJ, Kotschi H. Glenoid size, inclination, and version: An anatomic study. J Shoulder Elbow Surg 2001;10(4): 327-32.
[5]. A. K. Datta. Bones of Upper Limb with Special Comments essentials of Human Anatomy (Superior and Inferior Extremities) part.III, 4th ed. Current Books International 60, lenin saranee, Kolkata, 2009:5-9.
[6]. Sinnatamby CS. Last's Anatomy, Regional and Applied.11th ed. London: Churchill Livingstone; 2006;50-52.
[7]. Prescher A, Klumpen T. Does the area of the glenoid cavity of the scapula show sexual dimorphism? Journal of anatomy 1995;186:223-226.

[8]. Rajput HB, Vyas KK, Shroff BD. A study ofmorphological patterns of the glenoid cavity of scapula. National J of Medical Research 2012;2(4):504-7.

[9]. Churchill RS, Brems JJ, Kotschi H. Glenoid size, inclination, and version: An anatomic study. J Shoulder Elbow Surg 2001;10:327-32.

[10]. Frutos LR. Determination of sex from the clavicleand scapula in a Guatemalan contemporary ruralindigenous population. Am J Forensic Med and Pathol 2002;23:284-8.

[11]. Özer I, Katayama K, Sagir M, Gulec E. Sex determination using the scapula in medievalskeletons from East Anatolia. CollAntropol2006;30:415-419.

[12]. Kavita P, Jaskaran S, Geeta. Morphology of coracoids process and glenoid cavity in adult human scapulae. IJAPBS 2013;2(2): 19- 22.

[13]. Gosavi S.N., Dr.Jadhav S.D, Dr. Garud R.S. Morphometric study of scapular glenoid cavity in Indian population. IOSR Journal of Dental and Medical Sciences, 2014;13(9) Ver III:67-69.

[14]. Neeta Chhabra, Suraj Prakash, B K Mishra. An Anatomical study of glenoid cavity: Its importance in shoulder prosthesis. Int J Anat Res 2015;3(3):1419-24.

[15]. Mallon WJ, Brown HR,Vogler JB 3rd, Martinez S, Radiographic and geometric anatomy of the scapula. Clin.OrthopRelat Res 1992;277:142-154.

[16]. Md. Jawed Akhtar,Bipin Kumar, Nafees Fatima, Vinod Kumar Int J res med. Sci. 2016;4(7):2770-2776.

[17]. Dr.Girish V Patil, Dr.Sanjeev I Kolagi and Dr.UmeshRamdurg, Morphological study of Scapular Glenoid cavities. Global Journal of Medical research: H Orthopedic and Musculoskeletal System. 2014;14(2).

[18]. Pranoti Sinha, Karma Lakhi Bhutia, Binod Kumar Tamang, Rohit Kumar sarda. Morphometrical Study of Glenoid Cavity of Dry Human Scapula. Int J Med Res Prof 2016;2(3):86-90.

How to cite this article:

S.N.Shewale, Md. Laeeque, S.B.Sukre, S.C.Patil. MORPHOMETRIC STUDY OF GLENOID CAVITIES OF SCAPULAE IN MARATHWADA POPULATION. Int J Anat Res 2017;5(2.1):3759-3765. **DOI:** 10.16965/ijar.2017.169