

## Case Report

# BILATERAL ABERRANT RENAL ARTERIES WITH ANOMALOUS RIGHT TESTICULAR ARTERY ARISING FROM ABERRANT RIGHT RENAL ARTERY ASSOCIATED WITH BILATERAL POLYCYSTIC KIDNEYS: A CASE REPORT

SP Thangaraj <sup>\*1</sup>, G Rajathi <sup>2</sup>, N Vishali <sup>3</sup>.

<sup>\*1</sup> Professor & Head, Department Of Anatomy- Ponnaiyah Ramajayam Institute Of Medical Sciences (PRIMS) Manamainallur, Chennai, Tamilnadu, India.

<sup>2</sup> Assistant Professor, Department Of Anatomy- Ponnaiyah Ramajayam Institute Of Medical Sciences (PRIMS) Manamainallur, Chennai, Tamilnadu, India.

<sup>3</sup> Associate Professor, Department Of Anatomy- Ponnaiyah Ramajayam Institute Of Medical Sciences (PRIMS) Manamainallur, Chennai, Tamilnadu, India.

## ABSTRACT

Anatomical variations in the origin of the arteries in the abdominal area are very common. The coeliac trunk, renal and gonadal arteries are the arteries that show frequent variations. During routine dissection of a male cadaver, two aberrant renal arteries (one on right & one on left) supplying bilateral polycystic kidneys and anomalous right testicular artery arising from aberrant right renal artery was found in the abdominal region. Both the aberrant renal arteries originated from the right antero lateral aspect of abdominal aorta, ran towards the lower pole of corresponding polycystic kidneys. We found that the origin of right and left aberrant renal arteries were not at the same level. Aberrant right renal artery arose at a lower level than the aberrant left renal artery. Origin of aberrant right and left renal arteries were 45mm and 20mm below the origin of main right and left renal arteries. It was also found that the right testicular artery was anomalous taking origin from the right aberrant renal artery and the left testicular artery arose from abdominal aorta below the origin of left aberrant renal artery. These anatomical variations and anomalies are important to know before performing any diagnostic or therapeutic procedures in the abdominal area. Knowledge of the presence of aberrant renal arteries with anomalous origin of gonadal arteries is important with increased use of laparoscopic renal surgeries and donor nephrectomy.

**KEY WORDS:** Aberrant Renal Artery, Anomalous Testicular Artery, Polycystic Kidneys.

**Address for Correspondence:** Dr. SP Thangaraj, Professor & Head, Department Of Anatomy- Ponnaiyah Ramajayam Institute Of Medical Sciences (PRIMS) Manamainallur, Chennai, Tamilnadu, India. **E-Mail:** [drspthangaraj@gmail.com](mailto:drspthangaraj@gmail.com)

## Access this Article online

### Quick Response code



DOI: 10.16965/ijar.2017.343

**Web site:** International Journal of Anatomy and Research  
ISSN 2321-4287  
[www.ijmhr.org/ijar.htm](http://www.ijmhr.org/ijar.htm)

Received: 12 Jul 2017  
Peer Review: 12 Jul 2017  
Revised: None

Accepted: 16 Aug 2017  
Published (O): 30 Sep 2017  
Published (P): 30 Sep 2017

## INTRODUCTION

Single renal artery arises at right angles from each side of the aorta slightly below the origin of superior mesenteric artery (SMA). In about 70% of individuals there is one renal artery on

each side and 30% of individuals have accessory renal artery [1]. The accessory renal artery may arise from aorta or it may arise from coeliac, superior mesenteric, common iliac artery. They are the persistent embryonic lateral

splanchnic arteries. The testicular artery usually arises from the abdominal aorta at the level of the second lumbar vertebra, 2.5-5 cm below the renal artery [2]. Variations relating to origin, course and number of these arteries have been reported in a number of studies [2-4]. Although variations in the position of the origin of the testicular arteries are rare, they can also arise from the renal, accessory renal, middle suprarenal, inferior phrenic, lumbar, or even common iliac or internal iliac arteries. Occasionally, the testicular arteries may even be absent. In such cases, the gonads receive oxygenated blood via vesical/prostatic arteries [5,6]. It has been stated in literature that the testicular artery is situated a little inferior to the renal artery [5]. However, the exact distance between them has not been explored. Testicular arteries were classified into four categories on the basis of origin. This variability was depending in relation to the renal and inferior mesenteric arteries [7]. Though mostly undiagnosed throughout the life the aberrant vasculature could provide a formidable challenge during surgery in this region. Preoperative aortography is often required to visualize the uncertain anatomy of the anomalous renal artery to minimize the risk of preoperative and postoperative hemorrhage associated with the vascular surgery [8].

**Polycystic kidneys:** Shortage of kidney donors has resulted in occasional use of abnormal kidneys as those affected by autosomal dominant polycystic kidney disease (ADPKD) with preserved renal function [9]. Polycystic kidney disease isn't limited to the kidneys, although the kidneys are the most severely affected organs. The disease can cause cysts to develop in liver and elsewhere in the body. A common complication of polycystic kidney disease is high blood pressure [10]. Knowledge and awareness of these possible variations of the renal arteries are important for sufficient surgical management during renal transplantation, repair of abdominal aorta aneurysm, urological procedures and angiographic interventions [11].

Information about the origin and course of the testicular artery is surgically significant since undue ligation during invasive procedures can cause testicular atrophy. Furthermore, unusual

course and location of the testicular artery is important in many different surgical procedures that involve it [12]. Surgeons need to understand the morphologic variations of these arteries and ensure that they are not neglected, compromising oxygenation of the gonads. So here we are reporting bilateral aberrant renal arteries and a clinically important variation of right testicular artery, associated with bilateral polycystic kidneys with its embryologic explanation.

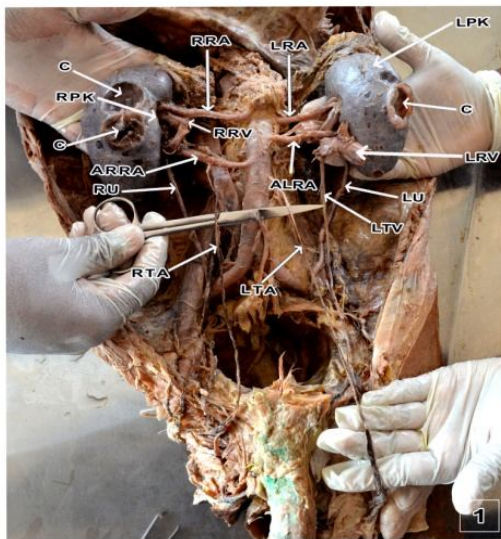
## CASE REPORT

During the routine dissection of a male cadaver of age around 50-55 years for medical undergraduate teaching in the Department of Anatomy, at Ponnaiyah Ramajayam Institute of Medical Sciences, Manamai Nallur, Chennai, we encountered bilateral aberrant renal arteries, variation in the origin of right testicular artery associated with bilateral polycystic kidneys. The abdominal cavity was opened, the small and large intestine was removed and the structures close to the posterior abdominal wall was dissected. We observed all unpaired and paired branches of the abdominal aorta, starting from the celiac trunk and superior mesenteric artery, renal arteries, gonadal and inferior mesenteric artery. We observed the position of right kidney which is slightly lower than the left kidney and both renal arteries arose from the abdominal aorta lateral to the superior mesenteric artery (Figure-1).

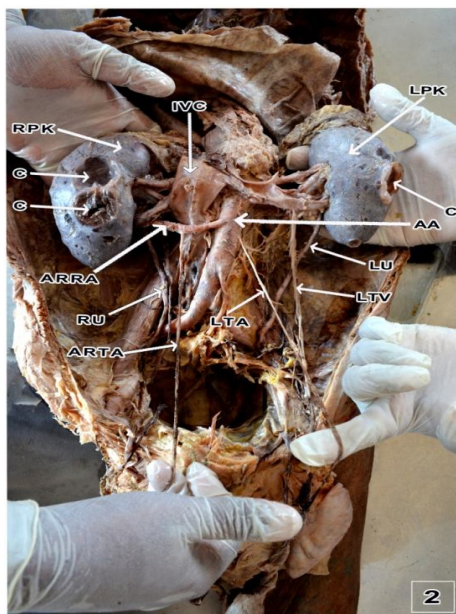
Figure 1 also shows bilateral aberrant renal arteries (right and left) in addition to right and left renal artery, arising from anterolateral aspect of the abdominal aorta, running towards the hilum of the kidneys. The origin of right aberrant renal artery and left aberrant renal artery were 45mm and 20mm below the origin of right and left renal arteries respectively. The origin of right and left aberrant renal arteries were not at the same level. Origin of right aberrant renal artery was 25mm below the left aberrant renal artery. From figure 1 & figure 2, we observed that the right testicular artery (RTA) was not arising from abdominal aorta. To view the origin of right testicular artery, the inferior vena cava (IVC) was reflected above the entry of renal veins and resutured downwards. The testicular artery was observed to arise along the



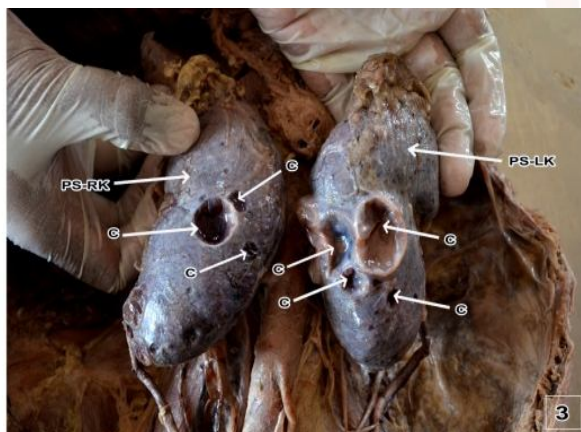
**Fig. 1:** Shows bilateral aberrant renal arteries (right and left) in addition to right and left renal artery, arising from anterolateral aspect of the abdominal aorta with bilateral polycystic kidneys.



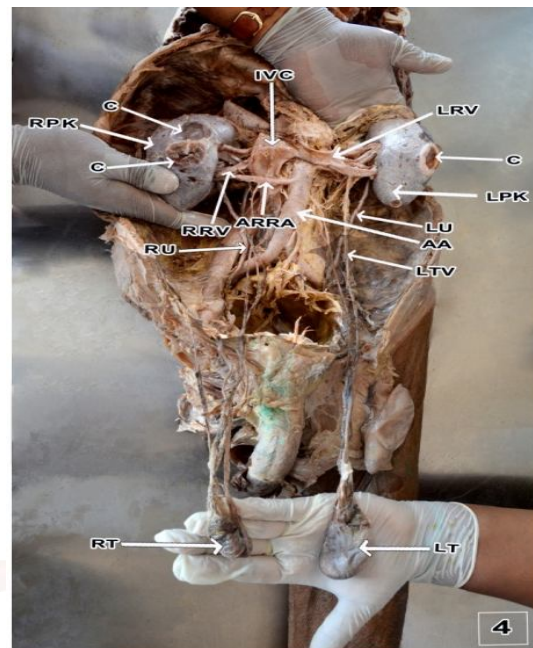
**Fig. 2:** anomalous right testicular artery taking origin from aberrant right renal artery (ivc was reflected downwards).



**Fig. 3:** shows multiple cysts on the posterior surface of both right & left kidneys.



**Fig. 4:** Shows aberrant right renal artery, anomalous right testicular artery, polycystic kidneys with both side ureters & testicular vessels with both testes.



inferior aspect of aberrant right renal artery hidden behind inferior vena cava and it passed lateral to right testicular vein (RTV) throughout its course and the origin of left testicular artery was from abdominal aorta 30mm below the origin of aberrant left renal artery and 50mm from the origin of left renal artery. Both the renal veins and testicular veins maintained normal course. The right and left renal veins and right testicular vein drained into IVC & left testicular vein into left renal vein. We also observed cysts on the anterior surface of right kidney, along the lateral border of left kidney and posterior surface of both the kidneys (Figure 1, 2, 3). Figure 4. Another view showing aberrant right renal artery, anomalous right testicular artery, polycystic kidneys with both side ureters & testicular vessels with both testes.

## DISCUSSION

Knowledge of embryology of the renal vasculature and development of the kidney is essential in order to understand the possibilities of the multiple anomalies and variations of the renal arteries [12]. The nomenclature of variations of the renal arteries is still not cleared, as different authors described them as additional, accessory, hilar, inferior and superior polar arteries [11].

The incidence of accessory renal arteries had

been reported as 30% by Henry Gray [1]. Presence of variations of renal arteries may be associated with other underlying renal pathological conditions as per Das S. [13] which coincides with this case report, where aberrant renal arteries were seen bilaterally, which arose at a lower level than the main renal arteries and it was associated with bilateral polycystic kidneys. The reported incidence of such variations of the renal arteries ranges from 8.7 to 75.7% [11].

The incidence of origin of gonadal arteries from the renal arteries has been reported to lie between 4.7 and 14% [14]. These variations were noted only on the right side. Moreover, case reports that document the origin of a gonadal artery from the renal artery are present in literature. Of these, the origin of the gonadal artery from an aberrant renal artery has only been reported in [15, 16] who reported the origin of the left testicular artery from a lower hilar renal artery and in the present case the origin of the right testicular artery is from the aberrant right renal artery.

**Embryological explanation of aberrant renal arteries:** According to Felix [17] the developing mesonephros, metanephros, suprarenal glands and gonads are supplied by nine pairs of lateral mesonephric arteries arising from dorsal aorta. Felix divided these arteries into three groups as follows:

**Group 1:** 1<sup>st</sup> and 2<sup>nd</sup> are cranial arteries.

**Group 2:** 3<sup>rd</sup> to 5<sup>th</sup> are middle arteries

**Group 3:** 6<sup>th</sup> to 9<sup>th</sup> are caudal arteries

The middle group gives rise to renal arteries and the persistence of more than one artery of the middle group results as multiple renal arteries. Thus the aberrant renal arteries in this case are as a result of bilaterally persisting mesonephric arteries of the middle group. Felix also stated that although any of these nine arteries may become the gonadal artery, it usually arises from the caudal group. In the present case the right testicular artery has originated from aberrant right renal artery so we believe that it has been derived from middle group as well Brenner explained that spermatic branches of renal origin were due to an early connection of a mesonephric artery with kidney which is normally lost [18].

Due to the increased demand for living donor graft in renal transplants, the knowledge of such variant anatomy of the renal and gonadal arteries is an important prerequisite for successful renal trans-plantation [19] and as such comprehensive arteriography of these vessels before surgery is recommended. The origin of the testicular artery from the accessory renal artery should be noted as injury to this vessel may result in testicular infarction [20]. The knowledge of this anomaly is important for surgical procedures related to the posterior abdominal wall, renal transplantation, abdominal aorta aneurysm, angiographic interventions. Every multiple renal artery is related to segmental arteries, so the risk of bleeding during urological surgery or renal transplantation, segmental ischemia and postoperative hypertension increases. In order to precisely plan the surgical procedure and avoid any vascular complication, arteriography should be performed before every nephrectomy [21].

## CONCLUSION

The testicular artery can arise from an aberrant renal artery. Renal artery variations can be associated with renal anomalies like polycystic kidneys. variations of the renal & testicular arteries is attributed to their embryonic origin from the lateral splanchnic arteries from the aorta. Even though the anomaly is revealed only on autopsy and may remain undiagnosed throughout life, the clinical implications are immense on proper diagnosis. Hence the anatomical knowledge of such anomaly would minimize the peroperative and postoperative morbidity related to surgical interventions and cadaveric transplantation procedures. These anatomical variations and anomalies are important to know before performing any diagnostic or therapeutic procedures in the abdominal area. Knowledge of the presence of aberrant renal arteries with anomalous origin of gonadal arteries is important with increased use of laparoscopic renal surgeries and donor nephrectomy.

## ABBREVIATIONS

**RPK-** Right polycystic kidney,

**LPK-** Left polycystic kidney,

**RRA-** Right renal artery,



**LRA-** Left renal artery,  
**ARRA-** Aberrant right renal artery,  
**ALRA-** Aberrant left renal artery,  
**RRV-** Right renal vein  
**LRV-** Left renal vein,  
**C-** Cyst, **RU-** Right ureter, **LU-** Left ureter,  
**LTA-** Left testicular artery,  
**LTV-** Left testicular vein,  
**RPK-** Right polycystic kidney,  
**LPK-** Left polycystic kidney,  
**IVC-** Inferior vena cava, **AA-** Abdominal Aorta,  
**ARTA-** Anomalous Right testicular artery,  
**PCRK-** Polycystic Right kidney,  
**PCLK-** Polycystic Left kidney,  
**RT-** Right testis, **LT-** Left testis.

**Conflicts of Interests: None**

## REFERENCES

- [1]. Standring S. 2016. Gray's Anatomy; Anatomical basis of clinical practice. 41<sup>st</sup> ed. London: Elsevier. pp 1243-1246.
- [2]. Williams PL, Bannister LH, Berry MM, Collins P, Dyson M, Dussek JE, Ferguson MW. Gray's Anatomy. 38<sup>th</sup> ed. London: Churchill Livingstone, 1995: 204, 318, 326, 361, 1548, 1557, 1559, 1826, 1827, 1920.
- [3]. Çiçekçibapı AE, Salbacak A, Peker M, Ziyilan T, Büyükmumcu M, Uysal YY. The origin of gonadal arteries in human fetuses: anatomical variations. Ann Anat 2002; 184: 275-279.
- [4]. Malcic-Gürbüz J, Akalın A, Gümüşçü B, Çavdar S. Clinical implications of concomitant variations of the testicular, suprarenal and renal veins: a case report. Ann Anat 2002; 184: 35-39.
- [5]. Williams PL, Warwick R, Dyson M, Bannister LH, editors. Gray's Anatomy. 37<sup>th</sup> ed. Edinburgh: Churchill Livingstone; 1989. p. 808-10.
- [6]. Bergman RA, Thompson SA, Afifi AK. Compendium of human anatomic variation: text, atlas, and world literature. Baltimore: Urban & Schwarzenberg; 1988. 83 p.
- [7]. Sushma R. Kotian, Arvind Kumar Pandey et al., A cadaveric study of the testicular artery and its clinical significance. J Vasc Bras. 2016 Oct.-Dec.; 15(4):280-286.
- [8]. Rachna Magotra et al., Anomalous left testicular artery arising from left accessory renal artery and its clinical implications. Int J Anat Res 2013;1(3):136-39. ISSN 2321- 4287
- [9]. Spees EK, Orlowski JP et al., Successful use of polycystic cadaver donor kidney. Transplant proc 1990;22: 374-375
- [10]. Henry mayala. A Case Report Of Polycystic Kidney Disease. www.iosrphr.org 2014;4(2):35-38.
- [11]. Satyapal KS, Haffjee AA, Singh B, Ramsaroop L, Robbs JV, Kalideen JM. Additional renal arteries: incidence and morphometry. Surg Radiol Anat. 2000;23:33-8
- [12]. Gupta A, Singal R, Singh D. Variations of gonadal artery: embryological basis and clinical significance. Int J Biol Med Res. 2011;2(4):1006-10.
- [13]. Das S. Anomalous renal arteries and its clinical implications. Bratisl. Lek. Listy., 2008;109:182-184
- [14]. Shoja MM, Tubbs RS, Shakeri AB, Oakes WJ. Origin of the gonadal artery: embryological implications. Clin Anat. 2007;20:428-432.
- [15]. Gurses AI, Kale A, Gayretli O, Bayraktar B, Usta A, Kayaalp ME, et al. Bilateral variations of renal and testicular arteries. IJAV. 2009;2:45-47.
- [16]. Thangaraj. SP, Vishali. N. Anomalous Origin of Left Testicular Artery From Left Accessory Renal Artery – A Case Report. Journal of Medical Research and Practice. 2017;6(2):43-45.
- [17]. Felix W. Mesonephric arteries (aa mesophriceae) In Kiebel F, Mall FP eds, Manual of human embryology Vol 2, Philadelphia, Lippincott 1912;820-25.
- [18]. Brenner JL, The origin of renal artery in mammals and its anomalies. Am J anat 1915;18:179-200.
- [19]. Kocabiyik N, Yalcin B, Yazar F, Ozan H. A persistent mesonephric artery: a rudimentary accessory renal artery. Gazi Med J. 2004;15:75-78.
- [20]. Siniluoto TM, Hellstrom PA, Paivansalo MJ, Leinonen AS. Testicular infarction following ethanol embolization of a renal neoplasm. Cardiovasc Intervent Radiol. 1998;11:162-164.
- [21]. Sampaio FJ, Passos MA. Renal arteries: anatomic study for surgical and radiologic practice. Surg Radiol Anat 1992;14:113-7.

### How to cite this article:

SP Thangaraj, G Rajathi, N Vishali. BILATERAL ABERRANT RENAL ARTERIES WITH ANOMALOUS RIGHT TESTICULAR ARTERY ARISING FROM ABERRANT RIGHT RENAL ARTERY ASSOCIATED WITH BILATERAL POLYCYSTIC KIDNEYS: A CASE REPORT. Int J Anat Res 2017;5(3.3):4378-4382. DOI: 10.16965/ijar.2017.343