

## ANATOMICAL STUDY OF POPLITEAL ARTERY BRANCHING PATTERNS AND SURGICAL CONSIDERATIONS

Wanderley, Annelise Passos Bispos <sup>1</sup>, Brito, Gabriel Amorim <sup>1</sup>, Rigolon, Luiz Paulo Junqueira <sup>1</sup>, Lessa, Pedro Fernandes <sup>1</sup>, Fernandes, Rodrigo Mota Pacheco <sup>1</sup>, Cisne, Rafael <sup>1</sup>.

<sup>1</sup> Department of Morphology, Biomedical Center, Fluminense Federal University, RJ, Brazil.

### ABSTRACT

**Background:** The pattern of popliteal artery branching and its variations still subject for discussions due to several procedures performed in the popliteal fossa by vascular surgeons and interventional radiologists daily. The aim of this survey is to describe and quantify these variations comparing the results to the data found in the literature.

**Material and Methods:** Twenty one anatomical specimens of the Department of Morphology from Fluminense Federal University, preserved in 10% formalin aqueous solution, were used in this study.

**Results:** From those specimens, 17 (80.95%) had the most common pattern which is anterior tibial artery (AT) arising first followed by bifurcation of tibial-peroneal trunk in the posterior tibial artery (PT) and peroneal artery (PR); 3 (14.28%) had the trifurcation pattern; and 1 (4.77%) had the PT as first branch and anterior tibial-peroneal trunk leading to AT and PR arteries posteriorly.

**Conclusions:** The results showed low frequency of the common pattern when compared to the literature and revealed the relevance of the trifurcation pattern. The relative position of the frequency of this pattern matches the results of other studies.

**KEY WORDS:** Anterior Tibial Artery, Tibiofibular Trunk, Trifurcation.

**Address for Correspondence:** Dr. Rafael Cisne, Department of Morphology – Biomedical Institute – Fluminense Federal University, 101 Prof. Ernani Mello St., PC: 24210-150, Niterói, RJ – Brazil. Phone 55-21-26292332 – Fax: 55-21-23292414 **E-Mail:** [rafael.cisne@gmail.com](mailto:rafael.cisne@gmail.com)

### Access this Article online

#### Quick Response code



DOI: 10.16965/ijar.2017.355

**Web site:** International Journal of Anatomy and Research  
ISSN 2321-4287  
[www.ijmhr.org/ijar.htm](http://www.ijmhr.org/ijar.htm)

Received: 18 Jul 2017  
Peer Review: 19 Jul 2017  
Revised: None

Accepted: 05 Sep 2017  
Published (O): 30 Sep 2017  
Published (P): 30 Sep 2017

### INTRODUCTION

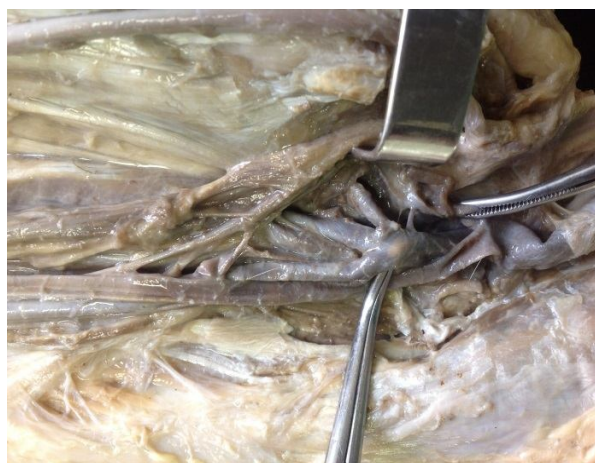The success of surgical procedures such as total knee replacement, ligament reconstruction, resection and vascular reconstruction, as well as radiological procedures, includes knowledge of the popliteal artery branching pattern and its variations [1-5]. The most frequent pattern consists of the anterior tibial artery (AT) arising first, followed by the bifurcation of tibial-peroneal trunk in posterior tibial artery (PT) and

peroneal artery (PR) [6-15]. However, it is possible to find variations with significant frequency and its knowledge is critical whereas it guides a good medical practice for vascular surgeons and interventional radiologists [3, 5, 6, 14-19].

The aim of this survey is to describe and quantify these variations comparing the results to the data found in literature based on the Kim et al classification [6].

## MATERIALS AND METHODS

**Fig. 1:** Popliteal artery trifurcation.



Twenty one anatomical specimens of the Department of Morphology from Fluminense Federal University, preserved in 10% formalin aqueous solution, were used in this study. The specimens were studied by gross anatomy dissection according to the Helsinki Declaration and approved by the Scientific Council. According to the classification of Kim et al<sup>(6)</sup>, were considered the distance between medial tibial plateau and arising at first popliteal artery branch (distance A), the posterior tibial-peroneal trunk length (distance B), the distance between first popliteal branch and its bifurcation (distance C) and the anterior tibial-peroneal trunk length (distance D). For such measurements a digital caliper rule was utilized.

## RESULTS

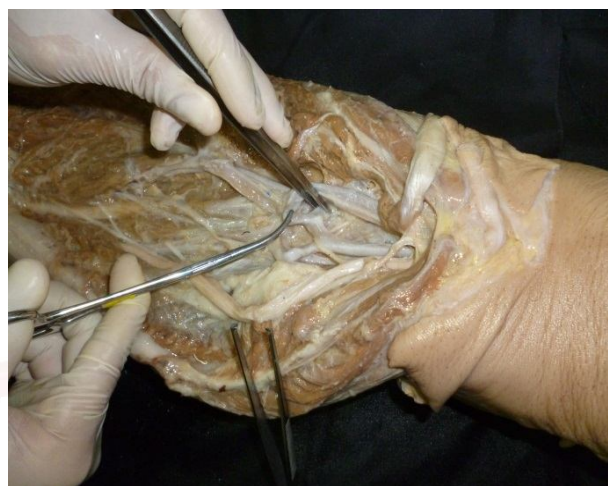The 21 anatomical specimens were classified by category I proposed by Kim et al [6]: normal level of popliteal artery branching. This means that, no specimen showed emission of arteries at the level of the femorotibial joint or above. We found all 3 types of division on this level (IA, IB, and IC) that are evidenced in Table 2. These frequencies were found: 80.95% (n=17) for the most common pattern; 14.28% (n=3) for trifurcation; 4.77% (n=1) for the emission of posterior tibial as the first branch and subsequent exit of the fibular and anterior tibial arteries by division of the anterior tibiofibular trunk (Table 1).

**Table 1:** Distribution of the Tibiofibular Division Patterns.

Ramification type	Number of pieces
Pattern IA	17 (80,95%)
Pattern IB	3 (14,28%)
Pattern IC	1 (4,77%)

The distance A had an average of  $6.2\text{cm} \pm 1.37$ . The distance B averaged  $2.2\text{ cm} \pm 1.4$ . The distance C appears only in cases of trifurcation (IB) and should be equal to or less than 0.5cm according to the criteria of Adachi [19]. The only value of distance D found was equal to 1cm.

**Fig. 2:** Anterior tibial-peroneal trunk. Length = 1cm (distance D).



## DISCUSSION

The frequency of the pattern IA (80.95%) is lower than all frequencies considered in the review by Kropman et al<sup>(7)</sup>. For this pattern, Kim et al. obtained 92.2%. The most remarkable, however, is not the most common pattern but the second most prevalent pattern. Trifurcation (Figure 1) is one of the most prevalent variations [6,7,20,21]. Its frequency in the literature ranges from 6.0% (Davies et al, 1989) [22] to 1.5% (Kil & Jung, 2009) [8]. Not even studies with a lower prevalence of the pattern IA presented values as expressive as this study, such as Mavili et al in 2011, which found 84.4% for the common pattern and 5.4% for trifurcation [9].

Probably, this is due to the patterns of category II of Kim et al [6], high tibiofibular division of the popliteal artery branch, which is representative in the literature [6,8,9,14,16,23]. In some cases, it exceeds trifurcation, 4.5% for the high division and 3.2% for trifurcation (Day & Orme, 2006) [10].

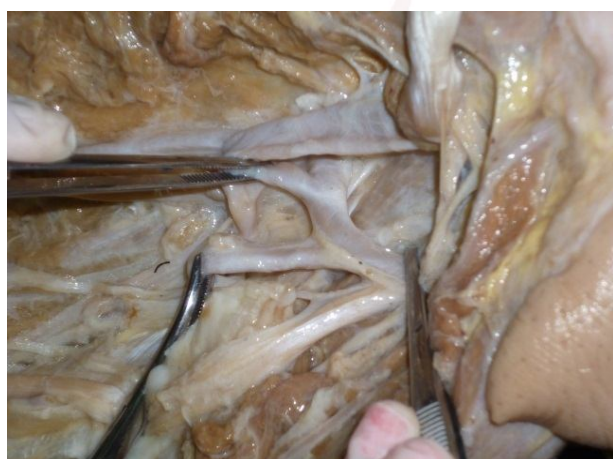
The anterior tibiofibular trunk (Figures 2 and 3), despite presenting an important frequency in this study, is a less expressive variant in the literature. Its values are sometimes exceeded by the frequency of Category III patterns [24], which is related to hypoplasia or proximal aplasia of

**Table 2:** Normal-level Tibiofibular Division Patterns.

Pattern IA	Pattern IB	Pattern IC
Tibiofibular trunk (most common pattern): emission of the anterior tibial at the level of the inferior border of the popliteal muscle and then the bifurcation of the tibiofibular trunk in tibial posterior A. and fibular A.	Trifurcation: is the division of popliteal A. into anterior tibial A., posterior tibial A. and fibular A. within a distance equal to or less than 0.5 cm. There is no tibiofibular trunk formation.	Anterior tibiofibular trunk: emission of the posterior tibial A. at the inferior border of the popliteal muscle and then bifurcation of the anterior tibiofibular trunk in anterior tibial A. and fibular A.

one popliteal branch. However, this category does not necessarily point to a different pattern of division of the tibiofibular trunk, but an altered vascular organization to supply the areas of defective branch irrigation.

**Fig. 3:** Anterior tibial-peroneal trunk on close capture.



## CONCLUSION

Arterial variations can be damaged through iatrogenic means if not properly documented. Therefore, the knowledge of variations in tibiofibular division pattern is indispensable for the exercise of surgical and radiological procedures in the proximal and distal regions of the lower limb, such as the treatment of popliteal artery aneurism, occlusive arterial disease and vascular injuries. On top of that, we must observe that trifurcation of the popliteal artery is maintained as a prominent pattern of tibiofibular division.

## REFERENCES

**Conflicts of Interests:** None

- [1]. Colborn GL, Lumsden AB, Taylor BS, Skandalakis JE. The surgical anatomy of the popliteal artery. *Am Surg* 1994;60(4):238-246.
- [2]. Ninomiya JT, Dean JC, Goldberg VM.. Injury to the popliteal artery and its anatomic location in total knee arthroplasty. *J Arthroplasty*. 1999;14(7):803-809.
- [3]. Mauro MA, Jaques PF, Moore M. The popliteal artery and its branches: embryologic basis of normal and variant anatomy. *American Journal of Roentgenology*. 1987;150(2):435-437.

- [4]. Zheng M, Chen C, Qiu Q, Wu C. Ultrasound in diagnosis of anatomical variation of anterior and posterior tibial arteries. *Med Ultrason*. 2016; 18(1):64-69.
- [5]. Sumalatha S, Periyasamy V, Bhatt R, Dsouza A S, Hosapatna M. Anomalous Branching Pattern of the Popliteal Artery (PA): A Case Report. *Journal of Clinical and Diagnostic Research*. 2014;8(6):AD01-AD02.
- [6]. Kim D, Orron DE, Skillman, J J. Surgical significance of popliteal arterial variants. A unified angiographic classification. *Annals of Surgery*. 1989;210(6):776-81.
- [7]. Kropman RHJ, Kiela G, Moll FL, de Vries JPPM. Variations in anatomy of the popliteal artery and its side branches. *Vascular and Endovascular Surgery*. 2011;45(6):536-540.
- [8]. Kil SW, Jung GS. Anatomical variations of the popliteal artery and its tibial branches: analysis in 1242 extremities. *Cardiovascular and Interventional Radiology*. 2009;32(2):233-240.
- [9]. Mavili E, Dönmez H, Kahrman G, Özaplamacı A, Özcan N, Ta°demir K. Popliteal artery branching patterns detected by digital subtraction angiography. *Diagnostic and Interventional Radiology*. 2011;17(1):80-83.
- [10]. Day CP, Orme R. Popliteal artery branching patterns — an angiographic study. *Clinical Radiology*. 2006;61(8):696-699.
- [11]. Ozgur Z, Ucerler H, Aktan Ikiz Z A. Branching patterns of the popliteal artery and its clinical importance. *Surgical and Radiologic Anatomy*. 2009;31(5):357-362.
- [12]. Keen JA. A study of the arterial variations in the limbs, with special reference to symmetry of vascular patterns. *Developmental Dynamics*. 1961;108(3): 245-261.
- [13]. Trotter M. The level of termination of the popliteal artery in the white and the negro. *American Journal of Physical Anthropology*. 1940;27(1):109-118.
- [14]. Lappas D, Stavropoulos NA, Noussios G, Sakellariou V, Skandalakis, P. Anatomic study of infrapopliteal vessels. *Folia Morphol*. 2012;71:164-167.
- [15]. Tomaszewski KA, Popieluszko P, Graves MJ, Pékala PA, Henry BM, Roy J, Hsieh WC, Walocha JA. The evidence-based surgical anatomy of the popliteal artery and the variations in its branching patterns. *J Vasc Surg*. 2017;65(2):521-529.
- [16]. Szpinda M. An angiographic study of the anterior tibial artery in patients with aortoiliac occlusive. *Folia Morphol*. 2006;65(2):126-131.
- [17]. Aktan Ikiz ZA, Ucerler H, Ozgur Z. Anatomic variations of popliteal artery that may be a reason for entrapment. *Surg Radiol Anat*. 2009;31:695.



- [18]. Demirtaş H, Değirmenci B, Çelik AO, Umul A, Kara M, Aktaş AR, Parpar T. Anatomic variations of popliteal artery: Evaluation with 128-section CT-angiography in 1261 lower limbs. *Diagn Interv Imaging*. 2016;97(6):635-42.
- [19]. Adachi B. Das arteriensystem der Japaner, *Journal of anatomy*. 1932;66(3):434-435
- [20]. Szpinda M. Digital-image analysis of the angiographic patterns of the popliteal artery in patients with aorto-iliac occlusive disease (Leriche syndrome). *Ann Anat*. 2006;188(4):377-382
- [21]. Calisir C, Simsek S, Tepe M. Variations in the popliteal artery branching in 342 patients studied with peripheral CT angiography using 64-MDCT. *Jpn J Radiol*. 2015;33(1):13-20.
- [22]. Davies BW, Husami TW, Lewis J, Retrum E. Developmental variations of the popliteal artery and its branches: a clinical correlation. *Contemp Surg*. 1989;34:28-32
- [23]. Yanik, B. Bulbul, E. Demirpolat, G. Variations of the popliteal artery branching with multidetector CT angiography. *Surgical and Radiologic Anatomy*. 2015;37(3):223-230.
- [24]. Çeltikçi P, Ergün O, Durmaz HA, Conkbayır I, Hekimoğlu B. Evaluation of popliteal artery branching patterns and a new subclassification of the 'usual' branching pattern. *Surg Radiol Anat*. 2017

**How to cite this article:**

Wanderley, Annelise Passos Bispos, Brito, Gabriel Amorim, Rigolon, Luiz Paulo Junqueira, Lessa, Pedro Fernandes, Fernandes, Rodrigo Mota Pacheco, Cisne, Rafael. ANATOMICAL STUDY OF POPLITEAL ARTERY BRANCHING PATTERNS AND SURGICAL CONSIDERATIONS. *Int J Anat Res* 2017;5(3.3):4410-4413. **DOI:** 10.16965/ijar.2017.355