

Original Research Article

A STUDY OF SURAL NERVE RELATIONSHIP WITH TENDOACHILLES IN HUMAN CADAVERS

M Shilpa ^{*1}, K R Dakshayani ².

^{*1} Assistant Professor, Department of Anatomy, Adichunchanagiri Institute of Medical Sciences, Mandya, Karnataka, India.

² Professor & Head, Department of Anatomy, Mysore Medical College & Research Institute, Mysore, Karnataka, India.

ABSTRACT

Background: The sural nerve is a major cutaneous nerve of the lower limb that courses through the posterolateral leg to supply the lateral margin of the hindfoot and midfoot and the ankle joint. The sural nerve accompanies the small saphenous vein as it descends in the posterior leg, traveling inferolateral as it crosses the lateral border of the calcaneal (Achilles) tendon. It then passes posterior to the lateral malleolus and terminates as the lateral dorsal cutaneous nerve supplying the lateral aspect of the foot. The precise knowledge of Sural Nerve crossing the lateral border of Achilles Tendon at particular distance proximal to Calcaneal tuberosity will help the surgeon to avoid Sural nerve injury at that point in a given leg length.

Aim: The objective of the study are: (1) To measure horizontal distance of the Sural nerve in relation to the lateral border of Achilles tendon. (2) To measure length of the lower limb from the base of the heel to flexor aspect of popliteal fossa.

Materials and Methods: The study was done on 64 lower limbs human cadaver specimens which were collected from dissection room from Department of Anatomy, Mysore Medical College, over a period of 2 years. The specimens obtained were fixed in 10% formalin and were finely dissected.

Results: In 64 dissected limbs the present study investigated the point at which the sural nerve crosses the lateral border of the Achilles tendon, as measured from the superior aspect of the calcaneal tuberosity. For example, in 42 cms leg length the average point of intersection was at 4.28 cms above the calcaneal tuberosity with an average horizontal distance of -0.85 mms from Achilles Tendon to Sural Nerve. Out of 64 dissected lower limbs, Type A (MSCN+LSCN) Sural nerve formation was seen in 78.1%, Type B (MSCN as Sural nerve) Sural nerve formation was seen in 14.1% and Type C (LSCN as Sural nerve) was seen in 7.8%.

Conclusion : In the present study an attempt is made to measure the exact distance at which the Sural nerve crosses the lateral border of Achilles tendon proximal to Calcaneal tuberosity and this measurement enables Surgeons to identify the location of the sural nerve with 95% confidence intervals, according to the patient's leg length. The present study concludes that the above said anatomic knowledge will assist surgeons in preoperatively predicting where the sural nerve crosses the lateral border of the Achilles tendon, thereby minimizing the risk of iatrogenic injury to Sural nerve.

KEYWORDS: Sural Nerve, Small Saphenous Vein, Achilles Tendon, Calcaneal Tuberosity.

Address for Correspondence: Dr. M Shilpa, Assistant professor, Department of Anatomy, Adichunchanagiri Institute of Medical Sciences, Mandya. Karnataka, India. Mobile No: 7411543525
E-Mail: shilpa_ramling@yahoo.co.in

Access this Article online

Quick Response code



DOI: 10.16965/ijar.2017.356

Web site: International Journal of Anatomy and Research
ISSN 2321-4287
www.ijmhr.org/ijar.htm

Received: 18 Jul 2017
Peer Review: 19 Jul 2017
Revised: None

Accepted: 15 Sep 2017
Published (O): 30 Sep 2017
Published (P): 30 Sep 2017

INTRODUCTION

Sural nerve is one of the major cutaneous nerves of the lower limb. It is a branch from Tibial nerve (TN) in the popliteal fossa, descends between the two heads of the gastrocnemius muscle, and pierces the deep fascia in the middle third of the posterior surface of the leg. It is usually joined by the peroneal communicating nerve (sural communicating nerve) which is a branch of common peroneal nerve (CPN) [1].

The sural nerve is a sensory nerve of the lower limb that supplies the lower posterolateral part of the leg and lateral part of the dorsum of the foot. It is generally described as a sensory nerve but may contain motor fibres [2]. The sural nerve is universally recognized by surgeons as a site for harvesting an autologous nerve graft [3]. The nerve is widely used for electrophysiological studies [4-7]. The formation and distribution vary in different individuals. The sural nerve is the most frequent donor nerve used for peripheral nerve grafting [3]. Despite the widespread use of the sural nerve, there is scant attention reported in the literature about associated donor site problem. The peroneal communicating nerve is readily accessible to surgical harvest as it lies superficially. When there is a situation requiring limited length of nerve graft material, the peroneal communicating nerve alone can be harvested and medial sural cutaneous nerve can be preserved and associated symptomatic neuroma of the sural nerve will be diminished. The sural nerve is at risk of iatrogenic injury even during minimal invasive operative procedures to repair the Achilles tendon. Damage to sural nerve have a profound effect on patients quality of life ranging from sensory disturbances to severe pain often associated with neuromas and potentially complete sensory loss [8].

MATERIALS AND METHODS

The study was done on 64 lower limbs human cadaver specimens which were collected from dissection room from Department of Anatomy, Mysore Medical College, for a period of two years. The specimens which were fixed in 10% formalin and were finely dissected.

OBSERVATIONS

To measure horizontal distance of the Sural nerve

in relation to the lateral border of Achilles tendon at 2cms interval taking calcaneal tuberosity as 0 cm upto 14 cms proximally. To measure length of the lower limb from the base of the heel to flexor aspect of popliteal fossa. To look for any variations in the sural nerve formation

RESULTS

Length of leg: Mean- 43.34 cm, Standard deviation - 4.57, Standard error – 0.57

Circumference: Mean- 18.31 cm, Standard deviation - 3.97, Standard error – 0.49

Fig. 1: Type A Sural Nerve Formation.

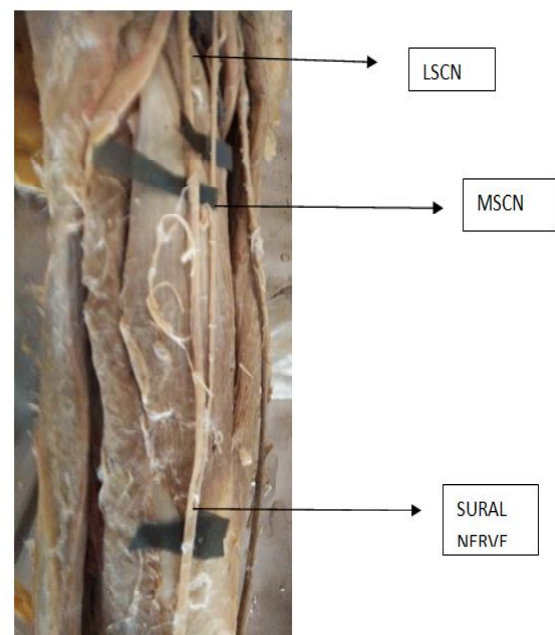


Fig. 2: Type B Sural Nerve Formation.

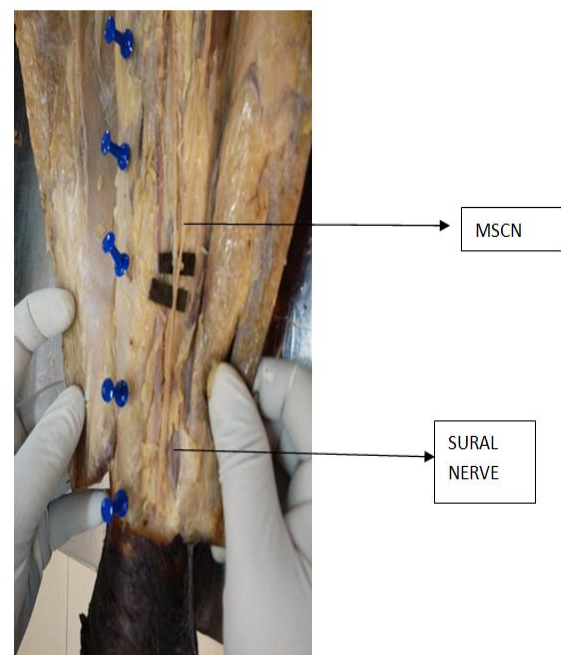


Fig. 3: Type C Sural Nerve Formation.

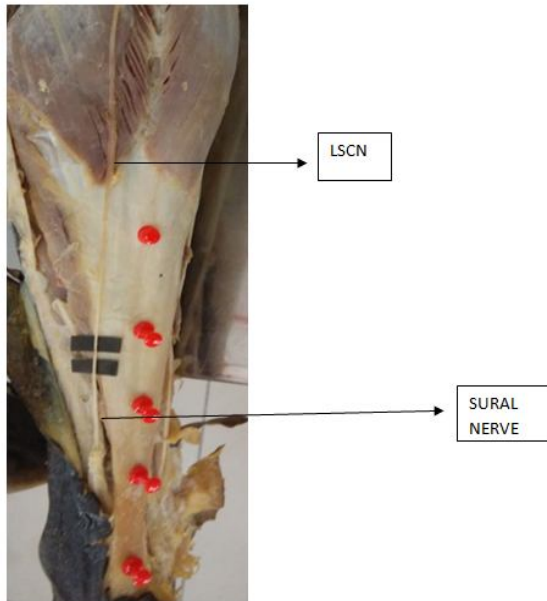


Table 1: Average horizontal distances of sural nerve to lateral border of Achilles at 8 reference points.

Distance from Superior aspect of Calcaneal tuberosity (cm)	Horizontal distances of sural nerve to lateral border of Achilles (mm)
0	3.27
2	1.82
4	0.003
6	-1.72
8	-3
10	-4
12	-4.74
14	-5.56

Regression analysis provided the equation:
 $\text{snlbTA} = -8.61 + 0.3 \times \text{leg length}$

p value = < 0.001 ; R = 0.94 ; R² = 0.883

Fig. 4: Scatter graph illustrating regression equation of point at which sural nerve crosses the lateral border of Achilles tendon and lower leg length. Solid line represents the regression line $\text{snlbTA} = 8.371 + 0.1 \times \text{leg length}$, dotted lines represent 95% confidence bands.

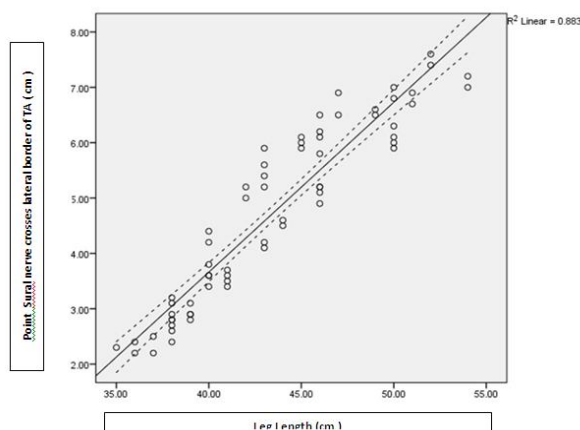


Table 2: Predicted values at which sural nerve crosses the lateral border of Achilles tendon at 95% confidence band values for lower leg length.

Lower Leg length	Predicted value of snlbTA (cm)	95% confidence bands for snlbTA	
		Lower	Upper
35	2.13	0.97	3.28
36	2.43	1.28	3.58
37	2.74	1.6	3.89
38	3.05	1.91	4.19
39	3.36	2.22	4.49
40	3.66	2.53	4.8
41	3.97	2.84	5.1
42	4.28	3.14	5.41
43	4.58	3.45	5.71
44	4.89	3.76	6.02
45	5.2	4.07	6.33
46	5.5	4.37	6.64
47	5.81	4.68	6.94
49	6.42	5.28	7.56
50	6.73	5.59	7.88
51	7.04	5.89	8.19
52	7.34	6.19	8.5
54	7.96	6.79	9.13

In 64 dissected limbs the present study investigated the point at which the sural nerve crosses the lateral border of the Achilles tendon, as measured from the superior aspect of the calcaneal tuberosity. For example, in 42 cms leg length the average point of intersection was at 4.28 cms above the calcaneal tuberosity with an average horizontal distance of -0.85 mms from Achilles Tendon to Sural Nerve. Out of 64 dissected lower limbs ,Type A (MSCN+LSCN) Sural nerve formation was seen in 78.1%,Type B(MSCN as Sural nerve) Sural nerve formation was seen in 14.1% and Type C (LSCN as Sural nerve) was seen in 7.8%.

The location of Sural nerve formation in relation to leg,17% was present in the upper 1/3rd,25.5% in the middle 1/3rd and 57.5% in lower 1/3rd of leg. Symmetricity of Sural Nerve in both the limbs of same cadaver was seen in 78% of dissected specimens and asymmetry was observed in 22% of specimens.

DISCUSSION

The importance of Sural nerve in relation to Tendo-Achilles is worth to know,as it is frequently injured during Tendo-Achilles rupture repair.So during any repair of Achilles Tendon the knowledge exact proximity of Sural nerve

with Achilles Tendon and if any crossing of the nerve to medial side in relation to Achilles Tendon is of immense help for surgeons [9].

Accordingly, a view of previous studies at different level of Achilles Tendon in relation to Sural nerve along with observations made in the present study is assessed through following important parameters.

Table 3: Comparison of sural nerve formation.

Author	Number of cases	MSCN+LSCN	MSCN as Sural Nerve	LSCN as Sural Nerve
William(1954)	257	83.70%	15.90%	0.40%
Heulke(1958)	198	80.30%	19.20%	0.50%
Mestdagh et al (2001)	37	67.60%	24.30%	8.10%
S R Seema (2013)	100	60%	39%	1%
Present study	64	78.10%	14.10%	7.80%

In the present study Type A Sural Nerve formation was more common. The present study is similar to the study done by William et al [10]., Heulke et al [11], Mestdagh et al [12], S R Seema et al [13]. Sural nerve was formed by union of MSCN & LSCN in 78.1% .Depending upon the formation of sural nerve the point of intersection of sural nerve with the lateral border of Achilles Tendon also varies .And complications related to Achilles Tendon repair particularly injury to sural nerve may be avoided if approximate intersection point is known.

According to Heulke et al [11] formation of SN was broadly classified into three types: Types A, B, and C.

In Type A: Sural Nerve was formed by the union MSCN of tibial nerve and PCN /Lscn of CPN. Occasionally the PCN of the CPN joins the MSCN by more than one branch. The union of these nerves occurs in the lower half of the leg.

In Type B: Sural Nerve was continuation of the MSCN and the PCN was absent.

In Type C: Sural Nerve was formed only by the PCN.

According to the studies of Coert and Dellon [14], and Uluttku et al [15], the typical sural nerve is formed by the union of MSCN with the PCN, branch of CPN. On the other hand Bannister et al [16], reported that the sural nerve is a branch of tibial nerve in the popliteal fossa and is usually joined by a peroneal communicating nerve arising from CPN.They considered MSCN as Sural nerve only. Haguy Kammar et al [17]

performed ultrasound examination of the posterior triangle of the ankle and Achilles tendon to determine the course of the sural nerve relative to the Achilles tendon in healthy participants. Three anatomical variants were reported, with the nerve crossing the lateral border of the Achilles low or high or with multiple branches yet to converge. Xiaohua Li et al [18] purpose was to compare outcomes of distally-based sural fasciocutaneous island flaps with and without inclusion of the sural nerve. In conclusion, preservation of the sural nerve is feasible during the creation of a distally-based sural artery flap, and can eliminate loss of sensation of the lateral foot.

CONCLUSION

The goal of the present cadaveric study was to identify the location at which the sural nerve crossed the lateral border of the calcaneal tendon (intersection point) to enable surgeons to identify its location with confidence. 95% confidence bands were determined from the results of 64 cadaveric leg dissections. The regression equation generated from the data in the present study showed a correlation between leg length and the point at which the sural nerve may cross the lateral border of the calcaneal tendon or the exact distance of sural nerve in relation to lateral border of Achilles Tendon. Specifically, as the leg length increased, this intersection point lay more proximally within the leg. These data enable a surgeon to approximate the location of the sural nerve at the lateral border of the calcaneal tendon to within 1 to 2 cm, depending on the patient's leg length and confidence level implemented. Therefore, these data provide the surgeon with a "danger zone" to avoid damage to the sural nerve when making incisions, placing retractors, or passing sutures along the lateral border of the Achilles tendon. When combined with other clinical and ultrasound methods of localizing the sural nerve, these data provide surgeons with another tool that is less intensive, to approximate the location of the sural nerve to avoid iatrogenic damage during operative procedures.

ABBREVIATIONS

MSCN - Medial Sural Communicating Nerve

LSCN - Lateral Sural Communicating Nerve

PCN - Peroneal Communicating Nerve

TN - Tibial Nerve

CP - Common Peroneal Nerve.

TA - Tendo Achilles

SnITA - Sural Nerve crossing lateral border of Tendon Achilles.

CT - Calcaneal Tuberosity.

Conflicts of Interests: None

REFERENCES

- [1]. L. H. Bannister, M. M. Berry, P. Collins et al., Gray's Anatomy. The Anatomical Basis of Medicine and Surgery, Churchill & Livingstone, 38th edition, 1995.
- [2]. C.-H. Kim, H.-Y. Jung, M.-O. Kim, and C.-J. Lee. The relative contributions of the medial sural and peroneal communicating nerves to the sural nerve. Yonsei Medical Journal, 2006;47(3):415-422.
- [3]. Buchgraber A, Passler HH. Percutaneous repair of Achilles tendon rupture immobilization versus functional postoperative treatment. Clin Orthop 1997;341:113-122.
- [4]. Li Z, Liu K, Lin Y, Li L. Lateral sural cutaneous artery island flap in the treatment of soft tissue defects at the knee. Br J Plast Surg 1990;43:546-550.
- [5]. McGillicuddy JE. Techniques of nerve repair. In: Neurosurgery, ed 2, pp. 3185-3186, edited by RH Wilkins, SS Rengachary, McGraw-Hill, New York, 1996.
- [6]. Walton RL, Bunkis J. The posterior calf fasciocutaneous free flap. Plastic Reconstruction Surgery 1984;74:76-85.
- [7]. Wei FC, Chuang SS, Yim KK. The sensate fibula osteoseptocutaneous flap: a preliminary report. Br J Plast Surg 1994;47:544.
- [8]. Majewski M, Rohrbach M, Czaja S, Ochsner P. Avoiding sural nerve injuries during percutaneous Achilles tendon repair. Am J Sports Med 2006;5:793-798.
- [9]. J.A. Blackmon, Stavros Atsas, Mackenzie J. Clarkson, Jacob N. Fox, Blake T. Daney, Sean C. Dodson, et al. / The Journal of Foot & Ankle Surgery 2013;52:42-47.
- [10]. Williams PL, Warwick R, Dyson M, Bannister LH (1989) Gray's Anatomy, 37th edn Edinburgh: Churchill Livingstone
- [11]. Huelke DF. A study of the formation of the sural nerve in adult man. Am J Physiol Anthropol 1957;15:137-147.
- [12]. Mestdagh H, Drizenko A, Maynou C, Demondion X, Monier R. Origin and makeup of the human sural nerve. Surg Radiol Anat 2001;23:307-312.
- [13]. S. R. Seema Study of Sural Nerve Complex in Human Cadavers ISRN Anatomy Volume Mestdagh H, Drizenko A, Maynou C, Demondion X, Monier R. Origin and makeup of the human sural nerve. Surg Radiol Anat 2001;23:307-312. 2013, Article ID 827276, 7 pages. <http://dx.doi.org/10.5402/2013/827276>.
- [14]. Coert and A. L. Dellon. Clinical implications of the surgical anatomy of the sural nerve. Plastic and Reconstructive Surgery 1994;94(6):850-855.
- [15]. Uluutku, M. A. Can, and Z. Kurtoglu. Formation and location of the sural nerve in the newborn. Surgical and Radiologic Anatomy 2000;22(2):97-100.
- [16]. L. H. Bannister, M. M. Berry, P. Collins et al., Gray's Anatomy. The Anatomical Basis of Medicine and Surgery, Churchill & Livingstone, 38th edition, 1995.
- [17]. Haguy Kammar, MD; Michael R. Carmont, MD; Eugene Kots, MD; Lior Laver, MD; Gideon Mann, MD; Meir Nyska, MD; Omer Mei-Dan, MD. Anatomy of the Sural Nerve and Its Relation to the Achilles Tendon by Ultrasound Examination March 2014;37(3):298-301 Posted March 1, 2014 DOI:10.3928/01477447-20140225-64.
- [18]. Xiaohua Li, Huidong Wang, Chunlin Xia, Lei Zhuang, Shimin Chang, Baozhi Ding, Zelu Li. Fasciocutaneous sural nerve flap for lower extremity reconstruction: include or exclude the sural nerve? Int J Clin Exp Med 2016;9(11):22289-22295 www.ijcem.com /ISSN:1940-5901/IJCEM0022111.

How to cite this article:

M Shilpa, K R Dakshayani. A STUDY OF SURAL NERVE RELATIONSHIP WITH TENDOACHILLES IN HUMAN CADAVERS. Int J Anat Res 2017;5(3.3):4414-4418. DOI: 10.16965/ijar.2017.356