

STUDY OF VARIATIONS IN THE BRANCHING PATTERN AND DISTANCE OF ORIGIN OF BRANCHES OF POSTERIOR CORD OF BRACHIAL PLEXUS

Santosh Bhosale ¹, Raghavendra A.Y ^{*2}.

^{*1,2} Associate Professor, Department of Anatomy, S.S.I.M.S & R.C, Davangere, Karnataka, India.

ABSTRACT

Background: Keeping in mind the frequency at which the surgical procedures are performed in the axilla, the organization and branching of brachial plexus and its topography becomes clinically significant and it is extremely complicated. Brachial plexus is the seat of explorations for oncosurgeons operating for breast carcinoma, schwannoma, neurofibroma, Anesthesiologists performing brachial plexus block, Plastic surgeons harboring myo-cutaneous flaps, Orthopedicians dealing with shoulder arthroplasty, humeral and clavicular fractures and for clinicians to explain the inexplicable signs of nerve compressions. The clinical importance of the variations in posterior cord is discussed in the light of various medical scenarios.

Objective: To study and compare the variations in the diverse branching pattern of the posterior cord and the distance of origin of each branch in a Central Karnataka population.

Materials and Methods: Branching pattern was studied by gross dissection of Brachial plexus. Origin and branching pattern and also the distance of the origin of branches of the posterior cord from mid-clavicular point on both sides were recorded.

Results: UTA (L) R is the most frequent branching pattern examined in 55% of cases on right side and 60% cases on left side. Two upper subscapular nerves were found in 13% of cases on left side. Thoracodorsal nerve originated from axillary nerve on the right side in 20% cases and 15% from common trunk on left side. Lower subscapular nerve had origin from axillary nerve in 60% of cases on left side and 55% on right side. 15% of axillary nerve had origin from common trunk on left side. Radial nerve arose from the Posterior cord in 100% cases.

Conclusions: Understanding the extensive array of variations involving the posterior cord and its branches, the clinicians can have a meticulous approach to axilla, respecting the facts and can utilize the facts in different cases to have a better outcome. Further study of the branching pattern of infraclavicular part of the brachial plexus is recommended.

KEY WORDS: Posterior cord, Upper subscapular, Thoracodorsal, Lower subscapular, Axillary, Radial.

Address for Correspondence: Dr.Raghavendra A.Y, Associate Professor, Department of Anatomy, S.S.I.M.S & R.C, Davangere-05, Karnataka, India. Mobile-9972134242

E-Mail: raghav4n72@gmail.com

Access this Article online

Quick Response code



DOI: 10.16965/ijar.2017.364

Web site: International Journal of Anatomy and Research
ISSN 2321-4287
www.ijmhr.org/ijar.htm

Received: 25 Jul 2017
Peer Review: 27 Jul 2017
Revised: None

Accepted: 05 Sep 2017
Published (O): 01 Oct 2017
Published (P): 01 Oct 2017

INTRODUCTION

The Brachial plexus is an intricate network of nerve fibres organized by plating of ventral rami of C_{5,6,7,8} and T₁. It is divided into Supra-clavicular part and infraclavicular parts. Infra-

clavicular part lies in the axilla and consists of Divisions, Cords and Branches. Posterior cord lies behind the second part of axillary artery thus; having the name, is united by posterior divisions of upper, middle and lower trunks and branches

into upper subscapular nerve, thoracodorsal nerve, lower subscapular nerve, axillary nerve and continues as large terminal branch radial nerve [1]. The individual branches show variant origin and branching pattern which is discussed in detail below.

The anatomy of posterior cord shows many variations, in a case report it was observed that the posterior cord divided into two roots, enclosing the subscapular artery and the two roots fused to continue as radial nerve. The lower subscapular nerve arose from the axillary nerve which was the continuation of the posterior cord in case of divided posterior cord. Axillary nerve may be the continuation of upper posterior cord in case of divided posterior cord [2].

The posterior cord is invariably involved in the dislocation of the shoulder [3]. Variations of posterior cord of brachial plexus are useful to surgeons for surgical treatment of tumor of nerve sheath such as schwannomas and neurofibromas [4]. The posterior cord can be used as a donor fascicle to the suprascapular nerve after its infraclavicular relocation [5]. Stimulation of the posterior cord before local anesthetic administration is linked with enhancement of infraclavicular block success compared with stimulation of either the lateral or medial cord [6].

Subscapular nerves are most varied structure and vastly inconsistent in their origin, number, course and supply to the muscles [7]; so their variations become vital as they are used in neurotisation procedure and also help in predicting the area of lesions. The position of the subscapular nerves and the pattern of innervation of the subscapularis is necessary to avoid injury during anterior shoulder surgery [8].

The thoracodorsal nerve innervates latissimus dorsi and is preserved during breast reconstruction with a pedicled myocutaneous latissimus dorsi flap to have improved functional and aesthetic outcome compared to denervated flap [9]. The thoracodorsal nerve is utilized for nerve transfer in case of elbow flexion reconstruction in infraclavicular brachial plexus injuries [10]. Lower subscapular nerve may have variant origin from axillary nerve which may lead to inadvertent damage and subsequent disability [11].

Axillary nerve usually branches from posterior cord, supplies deltoid and teres minor; sometimes it may also supply long head of triceps [12]. Hence during examination of cases with axillary nerve injuries, it is pertinent to examine for paralysis of long head of triceps. In a rare variation axillary nerve may take origin from the upper trunk as a direct branch [13]. The anatomical relationship of axillary nerve is required in case of reverse shoulder arthroplasty as it is frequently involved in neurological lesions after these surgery [14]. Axillary nerve injuries are also common in athletes involving in base ball, javelin throw, and racquet sports [15].

Sometimes there may exist a communication between axillary and radial nerve, this information is vital during tendon transfers involving latissimus dorsi to avoid symptoms of entrapment, [16] the radial nerve may arise from two rootlets surrounding the subscapular artery. This understanding may be of help to vascular surgeons. The radial nerve is habitually damaged in case of clavicular and humeral fractures resulting in parasthesia in the area of distribution [17].

Thus comprehension of variations in the branching pattern of the posterior cord of the brachial plexus is key to anatomists, radiologists, surgeons and anaesthesiologists and has gained weight due to the extensive use and dependence on computer imaging in diagnostic medicine.

Data on the variations and the measurements of the branches of the posterior cord among Karnataka is scanty and altogether lacking in central Karnataka. The present study tries to explain the variations in the measurements and branching pattern of the posterior cord observed in central Karnataka population.

Objectives: To study the origin of the branches of the posterior cord of the brachial plexus. To measure the distance of origin of the branches of the posterior cord of the brachial plexus from the mid-clavicular point on right and left sides. To study the variations in the branching pattern of the posterior cord of the brachial plexus.

MATERIALS AND METHODS

Source of data: The specimens for the study were obtained from the Department of Anatomy, S.S.I.M.S & R.C, Davangere.

Sample size: The study was carried out on forty upper limbs of adult human cadavers of both sex and age group between 30-60 years.

Materials: Dissection instruments, Measuring scale, Geometric radius, Sony cyber shot camera.

Dissection procedure: The upper limb was abducted to 90 degrees and contents of axilla were dissected. The axillary artery, vein and the large nerves around them were cleared. The large radial nerve was identified behind the the third part of axillary artery. It was traced upwards and at the lower border of subscapularis, the axillary nerve was seen circumflexing around the scapula backwards with the posterior humeral circumflex artery.

The pectoralis minor was dissected across and the axillary vessels were followed to the outer border of the first rib. The anterior surface of subscapularis was cleared and the upper subscapular nerves supplying it were noted. The upper and lower subscapular and thoracodorsal nerves were traced to their origin from the posterior cord of the brachial plexus.

The distance of origin of each branch from mid-clavicular point was noted and the branching pattern of the posterior cord was studied.

Representative photographs were taken using a Sony Cybershot R (DSC W50, 7.2 MP) digital camera.

RESULTS

ORIGIN of the Branches:

Upper subscapular nerve: Upper subscapular nerves originated from posterior cord in all the specimens (100%). Table- 1, 9% of specimens showed two upper subscapular nerves on right side and 13% on left side. Table-1.

Thoracodorsal nerve: 75% of thoracodorsal nerve on left and 70% on the right side took origin from posterior cord, 20% on the right and 10% on the left side arose from axillary nerve and 15% on the left side had origin from the common trunk. Table-1.

Lower subscapular nerve: 60% lower subscapular nerves on the left side and 55% on the right side had origin from axillary nerve, 40% on the right side and 35% on the left side from

posterior cord whereas 5% from the common trunk on both sides. Table-1.

Fig. 1: Showing two upper subscapular nerves and normal (utlar) branching pattern.

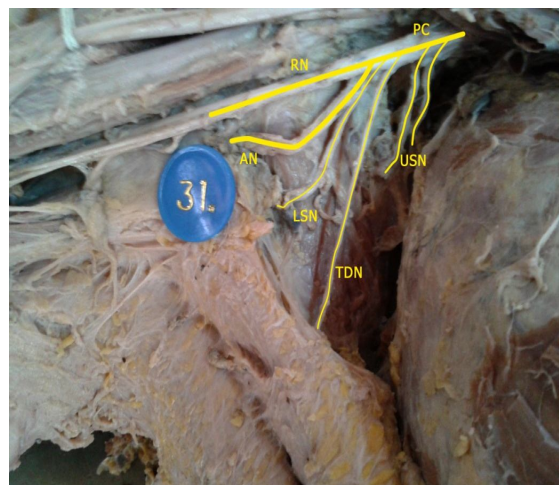
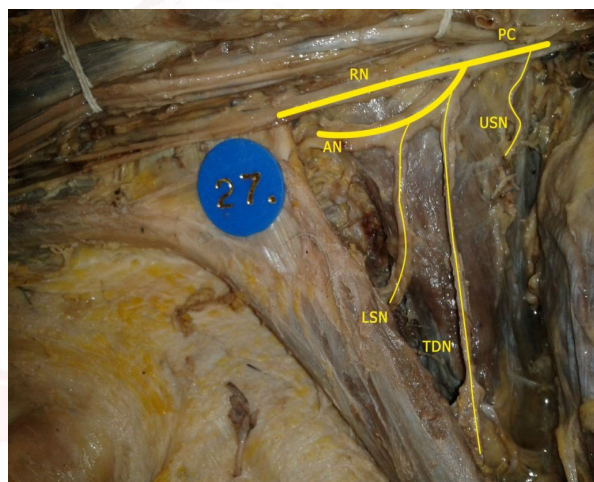


Fig. 2: Showing lower subscapular as a branch of axillary nerve and utal(r) branching pattern.



Axillary nerve: Axillary nerve had origin from posterior cord in 90% of cases on right side and 85% on left side and from the common trunk in 15% cases on the left side. Table-1.

Radial nerve: Radial nerves arose from posterior cord in all the specimens on both the sides. Table-1.

B. DISTANCE FROM MID-CLAVICULAR POINT:

Upper subscapular nerve: 84% of upper subscapular nerve on left side had origin at a distance of 3.6 – 4.0 cm and 40.9% of upper subscapular nerve on right side had origin at a distance of 3.6 – 4.0 cm. Table-2.

Thoracodorsal nerve: 40% of thoracodorsal nerve on left side had origin at a distance of 4.1 – 4.5 cm and 35% of thoracodorsal nerve on right side had origin at a distance of 4.6 – 5.0 cm. Table 2.

Lower subscapular nerve: 45% of lower subscapular nerves on right side and 30% on left side had origin at a distance of 5.1 – 5.5 cm. Table-2.

Axillary and Radial nerve: 45% of axillary nerve and radial nerve had origin at a distance of 4.6 – 5.0 cm on right side, 35% on left side showed origin at a distance of 5.1-5.5cm. Table.2.

Table 1: Showing frequency distribution of origin of branches of posterior cord of brachial plexus on right and left sides.

Sl.No	Nerve	Origin	Right	%	Left	%
1	USN	PC	22	100	25	100
2	TDN	PC	14	70	15	75
		CT	2	10	3	15
		AN	4	20	2	10
		AN	4	20	2	10
3	LSN	PC	8	40	7	35
		CT	1	5	1	5
		AN	11	55	12	60
		AN	11	55	12	60
4	AN	PC	18	90	17	85
		CT	2	10	3	15
5	RN	PC	20	100	20	100

PC- Posterior cord, CT- Common trunk, AN- Axillary nerve, USN- Upper subscapular nerve, TDN- Thoracodorsal nerve, LSN- Lower subscapular nerve, AN- Axillary nerve, RN- Radial nerve.

Table 2: Showing frequency distribution of distance of origin of branches of posterior cord of brachial plexus from mid- clavicular point on right and left sides.

Sl.No	Nerve	Distance range (cm)	Right	%	Left	%
1	USN	3.1-3.5	9	40.9	0	0
		3.6-4.0	9	40.9	21	84
		4.1-4.5	4	18.2	4	16
2	TDN	3.6-4.0	4	20	1	5
		4.1-4.5	5	25	8	40
		4.6-5.0	7	35	6	30
		5.1-5.5	2	10	5	25
		>5.5	2	10	0	0
		>5.5	2	10	0	0
3	LSN	4.1-4.5	2	10	2	10
		4.6-5.0	6	30	5	25
		5.1-5.5	9	45	6	30
		5.6-6.0	1	5	5	25
		>6.0	2	10	2	10
4	AN	4.1-4.5	3	15	5	25
		4.6-5.0	9	45	4	20
		5.1-5.5	6	30	7	35
		5.6-6.0	1	5	1	5
		>6.0	1	5	3	15
5	RN	4.1-4.5	3	15	5	25
		4.6-5.0	9	45	4	20
		5.1-5.5	6	30	7	35
		5.6-6.0	1	5	1	5
		>6.0	1	5	3	15

USN- Upper subscapular nerve, TDN- Thoracodorsal nerve, LSN- Lower subscapular nerve, AN- Axillary nerve, RN- Radial nerve.

DISCUSSION

The upper limb of human is primarily designed for prehension. The hand has a grasping and gripping mechanism, with four fingers flexing against an opposed thumb. The hand is also the main tactile organ with a rich nerve supply from the branches of brachial plexus making it as the third eye of the human body. Keeping in mind the medical and surgical aspects, the nerve supply of upper limb is very important. The brachial plexus habitat in the axilla and relations with the bones and vascular structures makes it vulnerable to injury [18].

Embryological variations can be ascribed to the Position and width of a limb bud which determine its innervations; limb bud develops as a cone and supplied by nerves of region where it is formed. Amalgamation of the developing structure within the limb direct growing nerve fibers determines their grouping into bundles leading to formation of roots and trunks [19]. As the expression of chemophilics and chemophobic regulates the growing nerve fibers in a highly coordinated site-specific fashion, any changes in signaling between the mesenchymal cells and neuronal growth cones can lead to important variations [20].

Priti Chaudhary et al observed that the normal branching pattern of the posterior cord (UTLAR) was encountered in 52 (86.67%) limbs [21]. In the present study of the posterior cord in 40 specimens UTA (L) R is the most frequent branching pattern observed in 60% of cases on the left side and 55% of cases on right side.

Muthoka et al noted that UTA (L) R was the most frequent order of branching pattern seen in 32 (42.7%) cases [22]. This is in correlation with the present study.

Bhat KMR and Girijavallabhan V reported that the posterior cord was splitting into thick posterior and thin anterior roots, enclosing the subscapular artery near its origin [23].

In the present study 13% of specimens on left side showed two upper subscapular nerves. Fazan VPS et al mentioned the variant origin of upper subscapular nerve in 59% of cases, out of 54 posterior cords [24].

Muthoka et al in the study of 75 posterior cords

encountered that upper subscapular nerve was given off by the posterior cord in 54 (72%) and originated as a single nerve in 56 (74.6%) specimens and as 2 separate branches in 5 (6.7%) specimens [22].

In a study of 62 specimens by R. Shane Tubs et al the upper subscapular nerve arose as a single nerve in 90.3% (56) of the cases, as two independent nerve trunks in 8% (5) of the cases and as three independent nerve trunks in 1.6% (1) of the cases [25].

Baliyan R. et al studied that the posterior cord branched into three upper subscapular nerves and a common trunk for the thoracodorsal nerve and lower subscapular nerve [26].

Chung CH and Yim JH et al reported that the thoracodorsal nerve branched from the axillary nerve in 27.6% [27].

Ballesteros and Ramirez had reported the origin of the lower subscapular nerve from the axillary nerve in 54.4% of their study of 57 specimens [7]. This also correlates with the current study.

Mario Loukas et al studied the axillary nerve in 50 human cadavers and observed that 100% took origin from the posterior cord [28]. In our study 15% of axillary nerve took origin from common trunk. Bergman et al reported that cases have been reported in which radial nerve was absent [29]. Such absence of radial nerve was not found in our study.

Kuwar RB and Bilodi AKS informed that the radial nerve was arising as two roots from the posterior cord of brachial plexus. One root was passing posterior to the subscapular artery and other root anterior and the artery was situated between the two roots of the radial nerve [17]. In our study radial nerve was seen as a continuation of the posterior cord in all the cases.

The Distances of origin of Branches of the Posterior Cord from the Mid-clavicular point:

The distance of different branches of the posterior cord from the origin of the parent trunk on both the right and left sides. The distance of the origin of upper subscapular nerve was more on the left side as compared to the right side, the average distance of origin of thoracodorsal nerve, axillary nerve and radial nerve were more on left side compared to the right side except

lower subscapular nerve which showed more distance of origin on the right side, which implies that the posterior cord has given its branches more distally on the left side compared to the right side. The same observation was documented by Khan GA et al in their study where mean distance of origin of branches was calculated from origin of posterior cord [30].

CONCLUSION

Comprehending the frequency of the surgeries in the complex region of axilla, Acquaintance of variations in the branching pattern of posterior cord of brachial plexus is imperative to anatomists, radiologists, surgeons and anaesthesiologists and has attracted significance attributed to the extensive dependence on sophisticated digital diagnostics which require sound anatomical knowledge. Furthermore the variations in the posterior cord of brachial plexus can be utilized to elucidate the mysterious signs and symptoms in the upper limb.

Conflicts of Interests: None

REFERENCES

- [1]. Standring S. Gray's anatomy. The Anatomical basis of clinical practice. 40th Ed., London: Elsevier Churchill Livingstone; 2008:821-822.
- [2]. Jamuna M. A rare variation in the mode of termination of posterior cord of brachial plexus. International Journal of Anatomical Variations 2010; 3: 95-96.
- [3]. Shears E, Sunderamoorthy D, Ali SA. Brachial plexus injury after anterior dislocation shoulder- a case report. Acta Orthop. Belg 2005; 71:489-490.
- [4]. Rastogi R, Budhiraja V, Bansal K. Posterior Cord of Brachial Plexus and Its Branches: Anatomical Variations and Clinical Implication. ISRN Anatomy, Volume 2013 (2013), Article ID 501813.
- [5]. Martins, Siqueira, Gilberto M, Heise, Otto C, Teixeira, Jacobsen M. Transfer of A Fascicle From the Posterior Cord To the Suprascapular Nerve After Injury of the Upper Roots of the Brachial Plexus: Technical Case Report. Neurosurgery. 2009 Oct; 65(4): E823-5.
- [6]. Lecamwasam H, Mayfield J, Chang Y, Carter C, Rosow c; Stimulation of the Posterior Cord Predicts Successful Infraclavicular Block. Anesth . Analg. May 2010; 110:1480-1485.
- [7]. Ballesteros LE, Ramirez LM. Variations of the origin of the collateral branches which emerge from the posterior aspect of the brachial plexus. Journal of Brachial Plexus and Peripheral Nerve Injury 2007; 2:14.

- [8]. Leschinger T, Hackl M. Nerve supply of the subscapularis during anterior shoulder surgery: definition of a potential risk area. *Archives of Orthopaedic and Trauma Surgery*. January 2017, Volume 137, Issue 1, pp 135–140.
- [9]. Kääriäinen M, Giordano S, Kauhanen S, Helminen M, Kuokkanen H. No need to cut the nerve in LD reconstruction to avoid jumping of the breast: a prospective randomized study. *J Plast Reconstr Aesthet Surg*. 2014 Aug; 67(8):1106-10. doi: 10.1016/j.bjps.2014.04.029. Epub 2014 May 13.
- [10]. Soldado F, Marcos F. Thoracodorsal Nerve Transfer for elbow flexion reconstruction in infraclavicular brachial plexus injuries. *J Hand Surg Am*. 2014.
- [11]. Kasper JC, Itamura JM, Tibone JE, Levin SL, Stevanovic MV. Human cadaveric study of subscapularis muscle innervation and guidelines to prevent denervation. *J Shoulder Elbow Surg* 2008 Jul-Aug; 17(4):659-62.
- [12]. Nanjundaiah K, Jayadevaiah SM, Chowdapurkar S. Long head of triceps supplied by axillary nerve. *International Journal of Anatomical Variations* 2012;5:35–37.
- [13]. SubaSinghe SK, Goonewardene S. A Rare Variation of the Axillary Nerve Formed as Direct Branch of the Upper Trunk. *Journal of Clinical and Diagnostic Research*. 2016 Aug, 10(8):ND01-ND02.
- [14]. Lädemann A, Stimec B.V, Denard P.J, Cunningham G, Injury to the axillary nerve after reverse shoulder arthroplasty: An anatomic study *Orthop. Traumatol. Surg. Res*. 2014; 100:105–8.
- [15]. Peter C. Vitanzo Jr, Barry E. Kenneally. Diagnosis of isolated axillary neuropathy in athletes: Case studies. *Arthritis|Imaging in Rheumatology|Lupus|Osteoarthritis|Osteoporosis|Psoriatic Arthritis |Geriatrics| Gout*. August 05, 2009.
- [16]. Rai R, Rai AR. Prevalence of Communication Between Axillary Nerve and Radial Nerve in Human Adult Cadavers. *Proceedings of Academics World 2nd International Conference, Kuala Lumpur, Malaysia, 5th Sept. 2015*, ISBN: 978-93-85465-88-8.
- [17]. Kuwar RB, Bilodi AKS. Claspings of subscapular artery by radial nerve; *Kathmandu University Medical Journal* 2007;5(18):253-255.
- [18]. Kerr AT. The brachial plexus of nerves in man, the variations in its formation and branches. *Am J Anat* 1918; 23:285–395.
- [19]. Keibel NZ, Mall FP. Nerves of the arm and leg in *Manual of Human Embryology*, pp. 122–128, J. B. Lippincott, Philadelphia, Pa, USA, 1st edition, 1912.
- [20]. Sannes HD, Reh TA. Harris WA. Axon growth and guidance in *Development of Nervous System*, pp. 189–197, Academic Press, New York, NY, USA, 2000.
- [21]. Chaudhary P, Singla R, Kalsey G, Arora K. Branching Pattern of the Posterior Cord of the Brachial Plexus: A Cadaveric Study. *Journal of Clinical and Diagnostic Research*, August 2011; 5(4): 787-790.
- [22]. Muthoka JM, Sinkeet SR, Shahbal SH, Matakwa LC, Ogeng'o JA. Variations in branching of the posterior cord of brachial plexus in a Kenyan population. *Journal of Brachial Plexus and Peripheral Nerve Injury* 2011; 6:1.
- [23]. Bhat K M R, Girijavallabhan V. Variation in the branching pattern of posterior cord of brachial plexus- A case report. *Neuroanatomy* 2008; 7: 10–11.
- [24]. Fazan VPS, Amadeu ADS, Caleffi AL, Filho OAR. Brachial plexus variations in its formation and main branches. *Acta Cir Bras* 2003; 18 (5): 1-8.
- [25]. Tubbs RS, Loukas M, Shahid K, Judge T, Pinyard J, Shoja MM, Slapkey JB, Mcevoy WC, Oakes WJ. Anatomy and Quantitation of the Subscapular nerves, *clinical anatomy*. 2007; 20:656–659.
- [26]. Baliyan R, Mehta V, Arora J, Nayyar AK, Suri RK, Rath G. Unilateral intercortical neural communication coexistent with variant branching pattern of posterior cord of brachial plexus. *ACTA MEDICA (Hradec Králové)* 2011; 54(3):131–134.
- [27]. Chung IH, Yim JH. Branching pattern and morphometry of the axillary nerve. *Korean J Anat*. Jun 2000; 33(3):373-379.
- [28]. Loukas M, Grabska J, Tubbs S, Apaydin N, Jordan R. Mapping the axillary nerve within the deltoid muscle. *Surgical and Radiologic Anatomy*. 2009; 31(3):43–47.
- [29]. Bergman RA, Thompson SA, Afifi AK, Saadeh FA. *Compendium of Human Anatomic variation*. Germany: Urban and schwarzenberg; 1988: 140,142.
- [29]. Khan GA, Yadav SK. Anatomical Variation in Branching Pattern of Brachial Plexus and Its Clinical Significance. *Int J Anat Res* 2017;5(1):3324-28.

How to cite this article:

Santosh Bhosale, Raghavendra A.Y. STUDY OF VARIATIONS IN THE BRANCHING PATTERN AND DISTANCE OF ORIGIN OF BRANCHES OF POSTERIOR CORD OF BRACHIAL PLEXUS. *Int J Anat Res* 2017;5(4.1):4445-4450. DOI: 10.16965/ijar.2017.364