

## UNRAVELLING THE MYSTERY BEHIND SUCCESSFUL CAUDAL-EPIDURAL BLOCK

Subhra Mandal <sup>\*1</sup>, Moumita Saha <sup>2</sup>, Shirshendu Ganguly <sup>3</sup>, Manjari Chatterjee <sup>4</sup>,  
Prabir Mandal <sup>5</sup>, Ramprasad Saha <sup>6</sup>.

<sup>\*1</sup> Associate Professor, Department of Anatomy, Medical College, Kolkata, West Bengal, India.

<sup>2</sup> Senior Resident, Anatomy, R.G. Kar Medical College, Kolkata, West Bengal, India.

<sup>3</sup> Demonstrator, Anatomy, Medical College, Kolkata, West Bengal, India.

<sup>4</sup> Retired Professor & Head, Department of Anatomy, Medical College, Kolkata, West Bengal, India.

<sup>5</sup> Medical Officer, Bangur Hospital, Kolkata, West Bengal, India.

<sup>6</sup> Final Year M.D. P.G.T. (Paediatrics), R.G. Kar Medical College, Kolkata, West Bengal, India.

### ABSTRACT

**Introduction:** The caudal epidural anaesthesia or block (CEB) is a process where special medications are injected into epidural space to provide analgesia and anaesthesia in various clinical procedures. CEB has been widely used for the treatment of lumbar spinal disorders, conservative management of chronic back pain as well as for providing anaesthesia in obstetrics. Successful CEB depends on precise localisation of sacral hiatus (SH), through which we gain access to sacral epidural space for effective block of sacral nerves. Anatomically sacral hiatus indicates termination of sacral canal resulting from failure of fusion of lamina of 5<sup>th</sup> sacral vertebra. It is utmost essential to have clear concept about anatomical variations associated with sacral hiatus so that success of CEB is guaranteed.

**Aim:** To study the morphometry of sacral hiatus as well as anatomical variations related to it that is useful for successful caudal epidural block.

**Materials and methods:** Present study was carried out on 191 dry human sacra (West Bengal, Indian population) to record various anatomical landmarks of sacral hiatus.

**Result:** Various shapes of sacral hiatus were recorded which included-Inverted U (46.84%), Inverted V (38.42%), Irregular (11.58%), Dumb-bell (3.16%) and Agenesis of SH (1 case). The Apex of sacral hiatus was most commonly found at the level of 4<sup>th</sup> sacral vertebra in 60% specimens and base of SH was present opposite the body of 5<sup>th</sup> sacral vertebra in 76.32% cases. Also, 82.63% specimen had mean length of sacral hiatus in between 1 to 2 cm. The anteroposterior diameter of sacral canal measured at the apex of SH was 0.4 to 0.6 cm in 68.95% cases. The width at the base of sacral hiatus most commonly (80.52%) ranged between more than 1 to 2 cm in our study.

**Conclusion:** Acknowledging the broad spectrum of clinical implications of caudal epidural block, it's very important to identify the precise location of sacral hiatus and caudal epidural space. Discrepancies in size and shape of SH, neighbouring bony irregularities and occasional defects in the dorsal wall of sacral canal should be thoroughly considered before performing CEB, so that inadvertent dural sac puncture is avoided and surrounding essential structures are not injured. Instead of using conventional blind technique, newer fluoroscopy or ultrasound guided needle placement has markedly improved the success rate of CEB.

**KEY WORDS:** Sacral hiatus (SH), Caudal epidural block (CEB), Sacral canal, Dural sac, Fluoroscopy.

**Address for Correspondence:** Dr. (Mrs) Subhra Mandal, Associate Professor, Department of Anatomy, Medical College & Hospital, Kolkata, West Bengal, India. Cont No.- 9477458100/9830814744  
**E-Mail:** drsuvramandal@gmail.com

### Access this Article online

#### Quick Response code



DOI: 10.16965/ijar.2017.382

**Web site:** International Journal of Anatomy and Research  
ISSN 2321-4287  
[www.ijmhr.org/ijar.htm](http://www.ijmhr.org/ijar.htm)

Received: 31 Jul 2017  
Peer Review: 31 Jul 2017  
Revised: None

Accepted: 05 Sep 2017  
Published (O): 01 Oct 2017  
Published (P): 01 Oct 2017

## INTRODUCTION

The knowledge about anatomical variations and structural modifications of sacral hiatus is essential for the reliability and success of caudal epidural block (CEB). Sacrum is a wedge shaped bone, formed by the fusion of five sacral vertebrae, present at the caudal end of vertebral column. Sacral hiatus (SH) is an arched opening, present at the terminal end of posterior wall of sacral canal, formed due to failure of fusion of laminae of 4<sup>th</sup> or 5<sup>th</sup> sacral vertebra (more commonly 5<sup>th</sup> sacral vertebra) in the median plane. It is located inferior to 4<sup>th</sup> (or 3<sup>rd</sup>) fused sacral spines or at the lower end of median sacral crest. The remnants of the inferior articular processes of the 5<sup>th</sup> lumbar vertebra elongates downwards on both sides of sacral hiatus to form the sacral cornua [1]. Surface marking of sacral hiatus is about 2 inches above the tip of coccyx under the skin covering the natal cleft (Williams, 2000) [2]. The 5<sup>th</sup> sacral spinal nerve emerges through sacral hiatus along with coccygeal nerve to provide partial innervations to pelvic organs like uterus, fallopian tubes, urinary bladder and prostate in addition to sensory and motor innervations to the respective dermatomes and myotomes [1,3]. The sacral canal also contains filum terminale externa, terminal parts of dura mater and arachnoid mater, fibro fatty tissue and epidural venous plexus that generally ends at the level of S4, but may continue inferiorly. Just opposite the middle of sacrum (between S1 and S3), the subarachnoid and subdural spaces terminate and the lower sacral spinal roots with filum terminale pierce the arachnoid and dura mater at this level [1,3]. The sacral hiatus is covered by superficial posterior sacrococcygeal ligament, attached to the margins of the hiatus and the deep posterior sacrococcygeal ligament, attached to the floor of sacral hiatus [1].

The sacral hiatus has been widely utilised for approaching the epidural space and giving anaesthesia or analgesia for various obstetric operations, treatment of lumbar spinal disorders, and management of chronic back pain [4]. Nevertheless, there are considerable anatomical variations in this region, resulting in disintegrity in the size and shape of SH which may make its

identification, a challenging task for clinicians. Proper identification of anatomical landmarks surrounding the SH forms the basis for successful CEB.

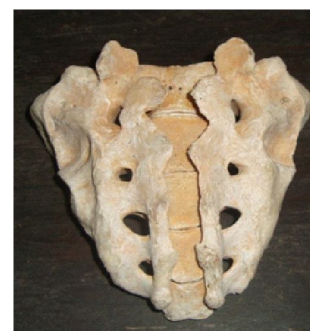**Aims and objectives:** The principal aim of our study was to identify maximum anatomical landmarks surrounding the SH, so that in the absence of one feature, alternatively, other one can be used. In our study, we have analysed the anatomical variations of SH in the Indian population living in West Bengal. Recorded observations will be helpful in providing a guideline for successful CEB.

## MATERIALS AND METHODS

Our study was conducted in the department of anatomy, Medical college, Kolkata, West Bengal (India). 191 dry adult human sacra of unknown sex were procured from different Medical Colleges of Kolkata. Only undamaged sacrum with intact sacral hiatus was included in the study. Sex and age of the bones were not determined and neonatal sacra, sacra with lumbarisation were excluded. Several morphometric measurements were recorded using Vernier Calliper and flexible steel tape. Each linear recording was taken in centimetres and statistical analyses done. Following parameters were taken into consideration:

- 1) Agensis of SH or defect in the dorsal wall of sacral canal
- 2) Different Shapes of sacral hiatus
- 3) Location of apex of sacral hiatus
- 4) Location of base of sacral hiatus
- 5) Length of sacral hiatus
- 6) Anteroposterior dimension of sacral hiatus at apex
- 7) Transverse diameter between the two cornua of sacral hiatus

## OBSERVATIONS AND RESULTS

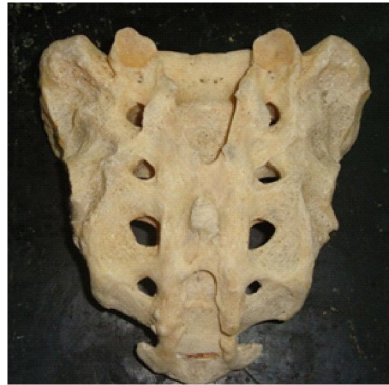

**Fig. 1:** Agensis of SH or defect in the dorsal wall of sacrum.

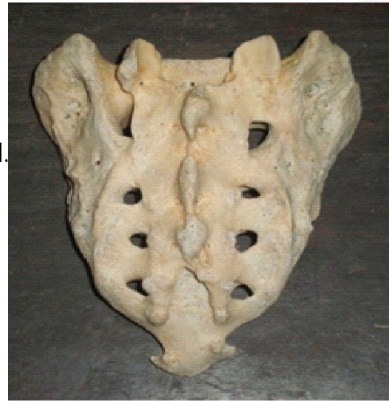In our study, we analysed 191 sacrum for various morphometric measurements. A single specimen presented with complete Agenesis of sacral hiatus, so we excluded that particular piece and calculated our results based on the measurements of 190 sacra.

## 2a) Different Shapes Of Sacral Hiatus-

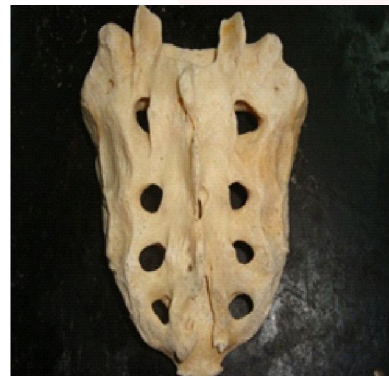**Fig. 2:** Inverted U shaped.



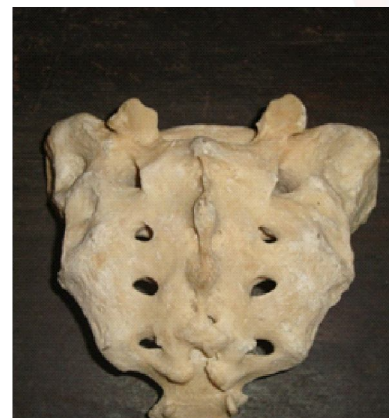Inverted V shaped.



Irregular



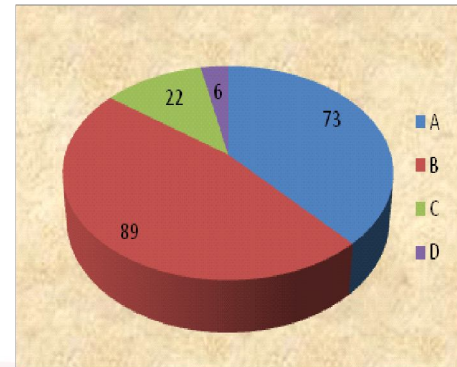
Dumbbell



## Different Shapes of Sacral Hiatus.

Sl. No.	Shape of sacral hiatus	No. of total	Percentage
A	Inverted V	73	38.42%
B	Inverted U	89	46.84%
C	Irregular	22	11.58%
D	Dumbbell	6	3.16%
Total		190	100%

**Graph 1a:**



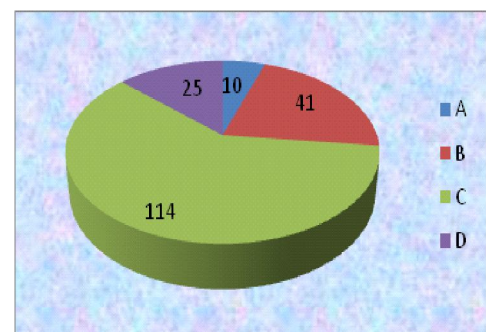
The Graph 1 depicts the distribution of different shapes of sacral hiatus. In 6 sacra there is dumbbell shaped hiatus, 22 sacra have irregular hiatus, 89 present inverted 'U' shaped hiatus and 73 sacra have inverted 'V' shaped hiatus

## Location of Apex of Sacral Hiatus-

**Table 2:**

Sl. No.	Location of apex of sacral hiatus	No. of total	Percentage
A	Opposite S3 body	10	5.26%
B	Opposite of junction of S3 & S4	41	21.58%
C	Opposite S4 body	114	60.00%
D	Opposite the junction of S4 & S5	25	13.16%
Total		190	100%

**Graph 2**



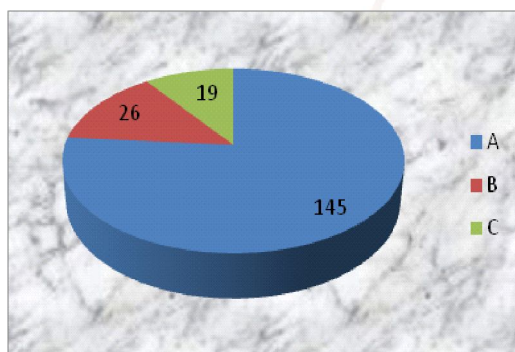
Graph 2 represents the location of apex of sacral hiatus which is quite variable. 25 sacra have their apex opposite the junction of S4 and S5, 114 sacra have it opposite body of S4, 41 sacra presented with the apex opposite the junction of S3 and S4 and 10 sacra have their apex opposite body of S3.



### Location of Base of Sacral Hiatus

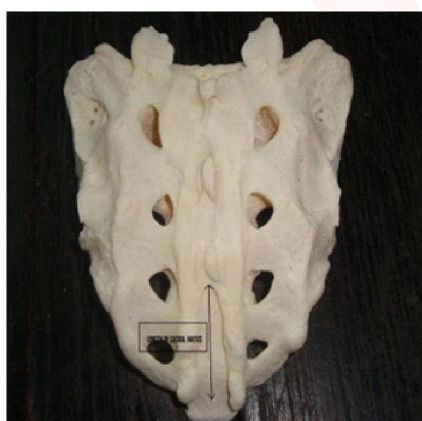Sl. No.	Location of base of sacral hiatus	No. of Total	Percentage
A	Opposite S5 body	145	76.32%
B	Opposite junction of S4 & S5	26	13.68%
C	Opposite lower border of S5	19	10.00%
Total		190	100%

Graph 3:

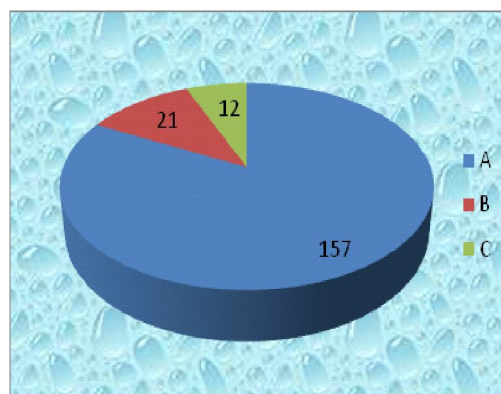


The location base of sacral hiatus is varies opposite the junction of S4 and S5 upto the lower border of S5. From the above chart 3 we can see that in 19 sacra the base is opposite the lower border of S5, in 26 sacra opposite the junction of S4 and S5 and in 145 sacra the base is opposite the body of S5 vertebra.

### Length of Sacral Hiatus-Photograph-III



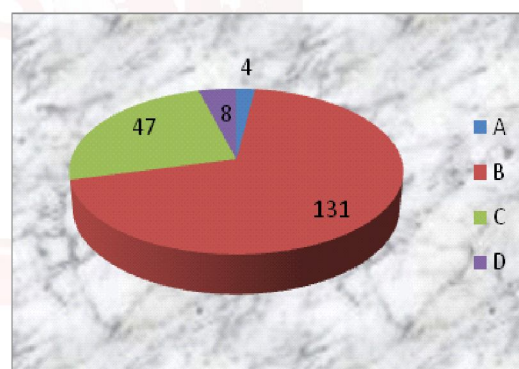
Sl. No.	Length of sacral hiatus (cm)	No. of total	Percentage
A	1 – 2	157	82.63%
B	>2 – 3	21	11.05%
C	>3	12	6.32%
Total		190	100%



From Graph 4, we find that 12 sacra present with >3cm long sacral hiatus, in 21 sacra the length varies from 2.1cm-3cm. Rest of the sacra present with 1cm-2cm long sacral hiatus.

### Antero- Posterior Dimension of Sacral Canal at Apex of Sacral hiatus

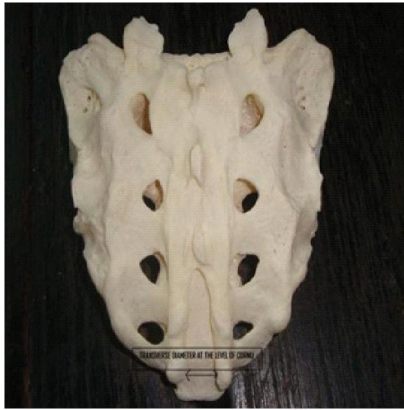Graph 5



Sl. No.	Antero- posterior dimension of sacral hiatus at apex (cm)	No. of total	Percentage
A	0.1 – 0.3	4	2.10%
B	>0.3 – 0.6	131	68.95%
C	>0.6 – 0.9	47	24.74%
D	>0.9	8	4.21%
Total		190	100%

The antero-posterior dimension of sacral hiatus (at the level of apex) is tabulated in chart no .5 which depicts 8 sacra presents with >0.9 cm diameter, 47 sacra with diameter in between 0.6 - 0.9cm, in 131 sacra the diameter is ranging between >0.3 - 0.6cm and only 4 sacra presents with diameter between 0.1 - 0.3cm.

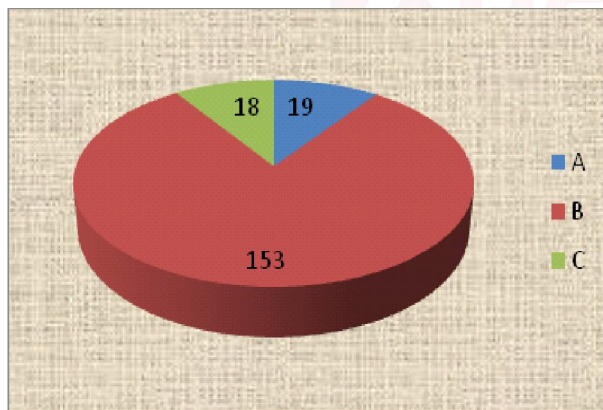
#### PHOTOGRAPH-IV TRANSVERSE DIAMETER AT THE LEVEL OF CORNU OF SACRAL HIATUS



Transverse Diameter at Cornu of Sacral Hiatus- Photograph-IV

Sl. No.	Transverse diameter at cornu of sacral hiatus(cm)	No. of total	Percentage
A	0 – 1	19	10.00%
B	>1 – 2	153	80.53%
C	>2	18	9.47%
	Total	190	100%

Graph 6



Graph 6 depicts the transverse diameter at cornu of sacral hiatus in cm. 18 sacra have diameter of >2cm, 153 sacra have diameter between >1 – 2 cm and 19 sacra have 0 - 1cm diameter.

#### DISCUSSION

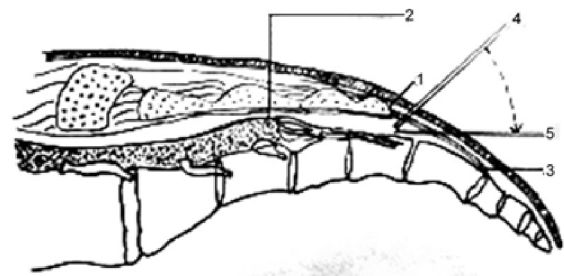
Knowledge of variations in anatomical features of sacral hiatus and dorsal wall of sacral canal helps us to perform caudal epidural anaesthesia, confidently and successfully. CEB is a procedure involving injection of special drugs (corticosteroids / local anaesthetics/analgesic agents) into the epidural space through the sacral hiatus, for effective blocking of sacral nerves [5]. As early as in 1901, the first epidural

anaesthesia, via caudal approach (single shot caudal blocks) was independently described by two French physicians. Jean Anthanese Sicard, a pathologist was the first to describe injection of dilute solutions of cocaine through the SH, into the epidural space, to treat patients suffering from severe, intractable sciatic pain or lumbago [6]. One week later, in 1901 only, Fernand Cathelin, urologist, described caudal administration of local anaesthetic for surgical procedures and also injection of cocaine for relief of pain due to inoperable carcinoma of rectum [7]. In 1949, the first successful continuous lumbar epidural anaesthesia was reported by a Cuban anaesthesiologist, Manuel Martinez Curbelo, who used "Urethral Catheters" (Tuohy Needle) that was actually developed for continuous spinal catheterisation [8].

#### Technique of CEB

Schematic diagram depicting the angulation of needle insertion during caudal epidural block. 1) Sacral hiatus 2) Termination of Dural sac 3) Sacrococcygeal ligament 4) Initial insertion angle 5) Angle of needle to advance.

#### DIAGRAM-I



Patient is placed in prone/semiprone/lateral decubitus position, table flexed or with pillow beneath the pelvis.

The sacral hiatus can be located by first palpating the coccyx of sacral cornu and then sliding the palpating finger in a cephalad direction, until a depression in the skin is felt. Alternatively by palpating the two sacral cornua as two bony prominences, the sacral hiatus could be identified as a dimple in between [3,4]. Skin overlying the SH is aseptically cleaned and a 22 gauge short bevelled cannula or needle is then directed at an angle of 45 degrees to skin (sacrum) and inserted till a subjective feeling of loss of resistance suggests piercing through sacrococcygeal

ligament (SCL) [4]. (Diagram-I) \*After entering into the caudal epidural space, the needle should only be minimally advanced, not more than 1-3 mm directed towards head at an angle approaching long axis of the spinal canal. If the needle is inserted for more than 1-3 mm, the distance between puncture site and dural sac being too short, results in either bloody tap or intrathecal injection (with complete spinal anaesthesia) [3,4]. The volume of sacral hiatus is 34 ml (on an average in dried bone specimen) but much smaller volume of local anaesthetic (5 to 10 ml) is used in day care pain management [3]. Potential difficulties faced while entering the caudal epidural space [9]:

1. Acute angle of sacral dorsal convexity.
2. Morbid obesity blocking fluoroscopic visualisation.
3. Developmental fusion of sacral canal/Agenesis of sacral canal (very rare)
4. Deformity of area surrounding SH, secondary to previous trauma or birth defect.
5. Short stature (Height less than 5 feet) or short sagittal dimension of sacrum.

The caudal epidural block was first introduced as a landmark based blind technique. In children, the success rate with blind technique is above 96%, but in adults it is only 68 to 75% even in experienced hands [10]. Modern Imaging Technology like Fluoroscopy and Ultra-sonography are now increasingly used for guided caudal epidural block [10].

Analysis of 191 dry adult human sacra were considered under following headings in our study:

Agenesis of SH or defect in the dorsal wall of sacral canal (rarely reported). Sekiguchi et al. [4] and Nagar [11] found complete agenesis of SH in 1 and 1.5% cases. Complete failure of CEB was observed in such cases. Present study of 191 sacra revealed a single sacrum presenting with complete agenesis of sacral hiatus. Shape of sacral hiatus-SH has a somewhat triangular outline when seen from dorsal aspect (Trotter and Letterman, 1944) [12]. Kumar V et al., 1992 [13] and Nagar, 2004 [11] noted various shapes of sacral hiatus, most common being Inverted 'V' and Inverted 'U' in 76.23% and 68.5% sacra respectively. 7.63% (Kumar, V. et al, 1992) [13] and

13.3% (Nagar, 2004) [11] sacra were dumb bell shaped. In addition to it Nagar, 2004 [11] reported 1.5% cases of bifid sacra. In the present study, Inverted 'U' (46.84%) and Inverted 'V' (38.42%) were the most common types. Rest were either dumb bell shaped (3.16%) or of irregular shape (11.58%). Inverted U and V shapes of SH provide enough room for introducing needle into sacral canal without any hindrance and thus are more preferred shapes for CEB. Bony projections present in the lateral wall of SH, M shaped sacrum, irregular shape of sacral hiatus are some rare reported cases of SH which obstruct proper needle insertion, resulting in failure of CEB [12].

Apex of sacral hiatus-To avoid inadvertent dural puncture, knowledge of level of apex of SH is very important. Low level of apex requires longer needle, while in high location of apex, clinician should be more cautious during calculating the length of needle to be introduced into the sacral canal. In short, high apex means higher chances of dural puncture. In the present study, the apex of SH was most commonly (60%) seen at the level of 4<sup>th</sup> sacral vertebra. Williams (2000) [2] states that apex of SH is located at the level of 4<sup>th</sup> sacral vertebra. Various studies recorded the apex of SH to be at 4<sup>th</sup> sacral segment, namely Nagar, 2004 [11] in 55.9%, Kumar V et al., 1992 [13] in 76.23% and Sekiguchi et al. [4], 2004 in 64% cases. But more precisely Trotter et al., 1944 [12] reported in their series the mean level of apex of SH to be at the lower 3<sup>rd</sup> of 4<sup>th</sup> sacral vertebra.

Base of sacral hiatus-Authentic past researches declared location of base of sacral hiatus varies from lower border of S4 to lower border of S5, and, may extend upto coccyx. In the present study, we observed in 76.32% specimens the base was present opposite the body of S5 vertebra, similar to findings of Patel DK et al. [14], who found the base of SH against the body of S5 vertebra in 79.33% cases. Base of SH was seen at the level of S5 vertebra in 71.67% cases by Seema et al (2013) [15]; 72.6% sacra by Nagar S K (2004) [11]; 83.17% specimen by Kumar V et al. (1992) [13]. Lowest location of base of SH was at the level of coccyx, in 16% sacra, as told in Nagars study [11] in 2004. (These cases were diagnosed as cases of



coccygeal ankylosis). And in the same study, 11.1% of sacra showed base of SH located as high as at S4 segment.

**Length of sacral hiatus** –In the present study 82.63% of specimen had length of SH ranging in between 1 to 2 cm. Nagar SK(2004) [11] observed this length ranging in between 1.1 to 2cm in most(35%) cases, while Jadhav Mayuri et al.(2014) [16] observed hiatal length in between 1 to 2 cm in 45.75% specimen. Kumar V et al.(1992) [13] observed mean length of SH as 2cm in males and 1.89cm in females. Trotter and Lanier (1945) [17] had reported length of SH as 24.8 mm in American males and 19.8mm in females.

**Anteroposterior Dimension (APD)** of sacral canal at the apex of sacral hiatus-is clinically very much relevant as it should be optimally wide to admit the needle into the sacral canal. Smaller diameters lead to subcutaneous deposition of anaesthetic drugs. In the present study, the APD ranged from 0.4 to 0.6 cm in 68.95% cases which is almost similar to studies done by Jadhav Mayuri et al.(2014) [16] in 71.18% cases, Seema et al(2013) [15] in 71.81% cases and Nagar SK (2004) [11] in 64.2% cases. Mean diameter reported by various workers were similar, like Kumar V et al. (1992) [13] got 4.8mm (0 to 12mm range), Trotter M (1947) [18] observed 5.3 mm(range of 0 to 11mm) in their study.

**Transverse diameter** between the two cornu of SH-most commonly (in 80.52% sacra) ranged between more than 1 to 2 cm in our study. Patel DK. et al (2011) [14] observed in 66.67% specimens-the transverse length at the level of cornu ranged between 1.1 to 2 cm. Nagar SK.(2000) [11] and Seema et al. (2013) [15] observed abovementioned transverse diameter as 1.1 to 2cm in 62% cases and 60.39% specimen respectively. Trotter and Letterman(1944) [12] noted the width at the base to vary from 7 to 26 mm with mean of 17 mm.

## CONCLUSION

There are considerable anatomical variations of sacral hiatus, relevant to caudal epidural block which may result in failed block by landmark based blind technique. The advent of fluoroscopy and ultrasound has markedly improved the success rates of CEB but when they are not

available, its the anatomical landmarks only which increase the probability of perfect needle placement in the sacral canal. Our study also gave us some of the probable anatomical causes of CEB failure. While inserting the needle into SH for CEB, its suggested to be done more nearer to base to avoid anatomic variations at apex. Once the needle is introduced into the sacral canal through apex of hiatus, it should not be advanced more than 5mm after penetrating the sacrococcygeal ligament to prevent dural puncture. Antero posterior diameter of SH less than 3mm and absent SH should be acknowledged before performing CEB. Lumbo-sacral spine radiographs may be helpful in identification of SH, its absence, various shapes and level of apex and base. Besides the anatomical landmarks, fluoroscopy remains the gold standard in guiding caudal epidural injection; though it's not always available and radioactive exposure is a matter of concern. So we can consider USG as the best modality in guiding caudal epidural injection which is easy to learn, less expensive, radiation free and can be virtually used in any clinical settings [5,10].

**Conflicts of Interests: None**

## REFERENCES

- [1]. Standring S, "The Back" in Gray's Anatomy: The Anatomical Basis of Clinical Practice. 40<sup>th</sup> edition, Elsevier Churchill Livingstone, London, 2013; 724-5.
- [2]. Williams, PL. Gray's Anatomy. 38<sup>th</sup> edition. Churchill Livingstone, 2000; 530(1): 673-674.
- [3]. Waldman SD. Caudal epidural nerve block: prone position. Atlas of Interventional Pain Management, 2<sup>nd</sup> edition. Philadelphia: Saunders, 2004; 380-92.
- [4]. Sekiguchi M, Yabuki S, Satoh K, Kikuchi S. An anatomic study of sacral hiatus: a basis for successful caudal epidural block. Clin J Pain 2004; 20: 51-4.
- [5]. Aggarwal A, Aggarwal A, Harjeet, Sahni D. Morphometry of sacral hiatus and its clinical relevance in caudal epidural block. Surgical and Radiological Anatomy 2009; 31(10): 739-800.
- [6]. Sicard JA. Les injections medicamenteuse extradurales per voie sacrococcygienne. Comptes Rendus des Seances de la Societe de Biologie et de ses Filiales, 1901; 53: 396-398.
- [7]. Cathelin F. Mode d'action de la cocaine injectee dans l'espace epidural par le procede du canal sacre. Comptes Rendus des Seances de la Societe de Biologie et de ses Filiales, 1901; 53: 452-453.
- [8]. Martinez Curbelo M. Continuous Peridural segmental Anesthesia by means of a urethral catheter. Curr Res Anesth Analg. 1949; 28: 13-23 (PUBMED)
- [9]. Bentley A., Ogoke MD. Caudal Epidural Steroid Injections. Pain Physician. 2000; 3(3): 305-312.

- [10]. Chen PC, Tang SFT, Hsu TC et al. Ultrasound guidance in caudal epidural needle placement. *Anaesthesiology* 2004;101:181-4.
- [11]. Nagar SK. A study of sacral hiatus in dry human sacra. *J Anat Soc India*. 2004;53(2):18-21.
- [12]. Trotter M and Letterman GS. Variations of the female sacrum: Their significance in continuous caudal analgesia. *Surgery, Gynaecology and Obstetrics*. 1944;78(4):419-424.
- [13]. Kumar V, Pandey SN, Bajpai RN, Jain PN, and Longia GS. Morphometric study of sacral hiatus. *Journal of Anatomical Society of India*, 1992;47(1):7-13.
- [14]. Patel DK et al. Multicentric Morphometric study of Dry Human Sacrum of Indian Population in Gujrat Region. *NJIRM* 2011;2(2):31-35.
- [15]. Seema Singh M and Mahajan A. An Anatomical Study of Variations of Sacral Hiatus in Sacra of North Indian Origin and its Clinical Significance. *Int. J Morphol*. 2013;31(1):110-114.
- [16]. Jadhav Mayuri, Nikam Vasudha, Ghorpade Vijay, Gune Anita, Patil Asha. Anatomical Study of Sacral Hiatus in Dry Isolated Sacra. *Journal of Research in Medical and Dental Science*. 2014;2(2):43-6.
- [17]. Trotter M. and Lanier PF. Hiatus Canalis Sacralis in American Whites and Negros. *Human Biology*, 1945;17:368-381.
- [18]. Trotter M. Variations of the sacral canal: Their significance in the administration of caudal analgesia. *Anaesthesia and Analgesia*. 1947;26(5):192-202.

**How to cite this article:** Subhra Mandal, Moumita Saha, Shirshendu Ganguly, Manjari Chatterjee, Prabir Mandal, Ramprasad Saha. UNRAVELLING THE MYSTERY BEHIND SUCCESSFUL CAUDAL-EPIDURAL BLOCK. *Int J Anat Res* 2017;5(4.1):4492-4499. **DOI:** 10.16965/ijar.2017.382