

VARIATIONS IN DRAINAGE PATTERN OF INFERIOR MESENTERIC VEIN

Ramandeep Kaur ¹, Anshu Sharma ^{*2}, Mahesh Kumar Sharma ³, Rupinder Singh ⁴, Arun Sharma ⁵.

^{1,4,5} Demonstrator, Department of Anatomy, Government medical college and hospital, Chandigarh, India.

² Associate professor, Department of Anatomy, Government medical college and hospital, Chandigarh, India.

³ Professor & Head, Department of Anatomy, Government medical college and hospital, Chandigarh, India.

ABSTRACT

Introduction: The inferior mesenteric vein drains blood from part of the large intestine and usually terminates in the splenic vein. It may drain into superior mesenteric vein or junction of superior mesenteric vein and splenic vein. Knowledge of such variations is very useful and important for anatomists, radiologists and surgeons performing surgeries related to this region.

Materials and Methods: The study was carried on 15 enblock specimens of duodenum, pancreas and spleen to understand the anatomy of drainage pattern of inferior mesenteric vein.

Results: It was found that in 11 specimens (73% cases) IMV drained into splenic vein at different sites. In 3 cases (20%) it drained at the junction of SMV & SV at level of formation of portal vein. In one case it was found that IMV drained nearly into SMV.

Conclusion: From the present study it was concluded that the inferior mesenteric vein does indeed drain into three sites: the splenic vein, the superior mesenteric vein, or the junction between the superior mesenteric vein and the splenic vein. This study would be useful for the anatomists, surgeons and radiologists dealing with this region.

KEY WORDS: Inferior mesenteric vein, superior mesenteric vein, portal vein, splenic vein.

Address for Correspondence: Dr. Anshu Sharma, Associate Professor, Department of Anatomy, Government medical college and hospital, sector 32, Chandigarh, Punjab, India.

E-Mail: anshusharma_01@yahoo.co.in

Access this Article online

Quick Response code



DOI: 10.16965/ijar.2017.401

Web site: International Journal of Anatomy and Research
ISSN 2321-4287
www.ijmhr.org/ijar.htm

Received: 08 Aug 2017

Peer Review: 08 Aug 2017

Revised: None

Accepted: 03 Oct 2017

Published (O): 01 Nov 2017

Published (P): 01 Nov 2017

INTRODUCTION

The inferior mesenteric vein (IMV) is a blood vessel that drains blood from the left part of the large intestine. It usually terminates in the splenic vein. Splenic vein joins with superior mesenteric vein (SMV) to form the Portal vein (PV). Inferior mesenteric vein begins halfway

down the anal canal as superior rectal vein. Then it passes up along the posterior abdominal wall on left side of the Inferior mesenteric artery lying anterior to the left psoas major muscle. It may cross the left testicular artery or ascend medial to it, to end in the splenic vein behind pancreas. Tributaries of the IMV drain the large

intestine, sigmoid colon and rectum [1].

The venous drainage of the inferior mesenteric vein is variable [2]. Most of the Anatomy textbooks state that the inferior mesenteric vein joins and drains into the splenic vein [3-6]. Anatomical variations also include different drainage patterns into the SMV and the junction between the superior mesenteric vein and the splenic vein etc. It is imperative that all these common drainage sites of the inferior mesenteric vein are stated in anatomy resources, so that students are taught realistic human anatomy including its common variations.

Knowledge of such variations regarding the formation, termination and tributaries of portal vein, IMV, SMV and splenic vein are very useful and important for surgeons performing surgeries on pancreas and duodenum and also for liver surgeries and interventional procedures. It is also helpful for radiologists while performing radiological procedures [7-9].

Objective: The study was done with the objective to study the drainage patterns of inferior mesenteric vein and report variations if any.

MATERIALS AND METHODS

The study was conducted in Department of Anatomy, Government Medical College, Chandigarh. The embalmed cadavers were dissected during routine dissection for teaching the M.B.B.S students. The study was conducted on 15 specimens. All the cadavers belonged to the adult age group. Out of 15 cadavers there were 11 male cadavers and 4 female cadavers. The duodenum, pancreas and spleen were taken en block to see the drainage patterns of IMV into splenic vein and its contribution for the formation of portal vein. The veins of the specimens were cleaned off, photographed and studied thereafter. The incidence obtained in the present study was compared with the previous data available.

RESULTS

Among 15 specimens of pancreas with spleen the relation of IMV drainage into splenic vein, SMV and its contribution to drain into portal vein was studied. It was found that in about 11 specimens (73% cases) it drained into splenic vein at different sites (shown in figure 1).

In 3 cases (20%) it drained at the junction of SMV& SV at level of formation of portal vein (shown in fig. 2). In one case it was found that IMV drained nearly into SMV. (shown in Tab.1)

Table 1: Drainage Sites of IMV.

IMV drainage site	Frequency of occurrence
Splenic vein	11(73%)
At confluence of veins	3(20%)
Superior mesenteric vein	1(6%)
Other site	None

Fig. 1: Picture Depicting IMV draining Into Splenic Vein at other Site.

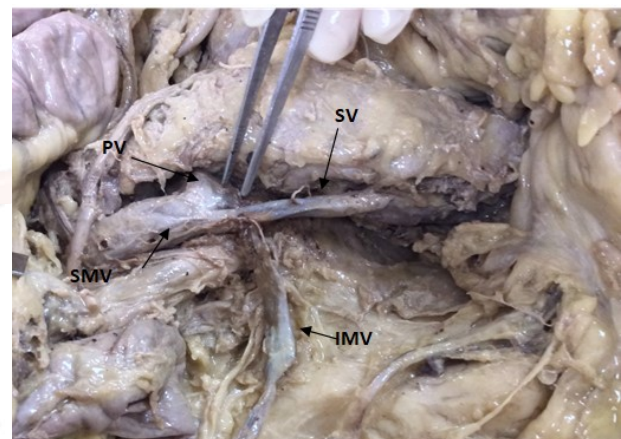
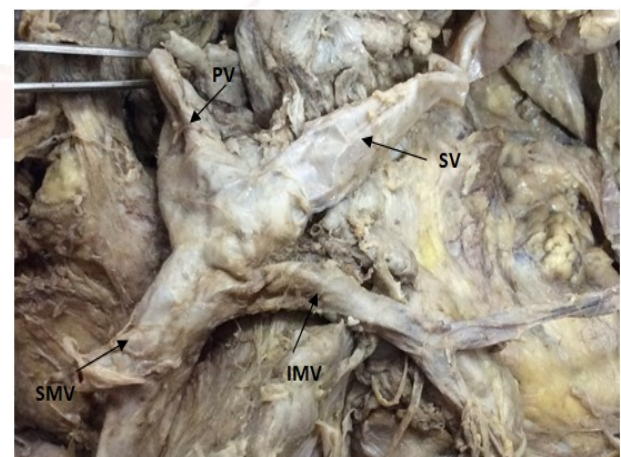


Fig. 2: picture depicting drainage of IMV at confluence of SMV & SV



Understanding anatomical variations like the drainage pattern of the inferior mesenteric vein is also applicable and important for aspiring gastrointestinal surgeons, who need to have comprehensive knowledge of the mesenteric region for successful surgeries. Therefore, it is imperative for anatomy resources to provide the various major drainage sites of the inferior mesenteric vein (the splenic vein, superior mesenteric vein, or the junction between the splenic vein and superior mesenteric vein) and also include the frequencies of this variability.

This will provide a more accurate representation of this venous drainage pattern of the inferior mesenteric vein and an overall better understanding of anatomical variation in the mesenteric venous drainage system.

DISCUSSION

Based on data collected as shown in Table no. 2 for drainage pattern of IMV Weinhaus worked on 113 cadavers at university of Minnesota, reported that in 36% cases IMV drained into SV, 41% of IMV drained into SMV and 21% drained into confluence of SMV & SV. Papavasiliou et al studied 300 consecutive computed topography scans and found that 54% cases IMV drained into SV, 27% into SMV while 17% cases drained at confluence. In nearly 1% cases it was found that IMV drained into jejunal and ileal branches. Graf O, worked on 54 patients undergoing helical CT venography of pancreas and it was found that 56% cases IMV drained into SV, 26% into SMV and 18% into junction of SMV & SV. Sakaguchi studied 102 patients undergoing multidetector row computed tomography and found maximum 68% cases IMV drained into SV, 18% into SMV & 7% into junction of SMV & SV.

The present study was done on 15 cadaveric specimens and it was seen that 73% cases IMV drained into SV, 6% cases IMV into SMV and 20% entered into confluence of SMV & SV. Some of anatomy textbooks diagrammatically illustrate the inferior mesenteric vein joining and draining into the splenic vein [10-12]. According to recent literature, however, the inferior mesenteric vein has also been reported to join and drain into the superior mesenteric vein, the junction between the splenic vein and the superior mesenteric vein, or into other mesenteric venous drainage sites [2,13-15]. However, many textbooks do not address the variability of IMV drainage pattern into various venous drainage sites [16,17] Some textbooks may acknowledge this mesenteric vasculature variation and note the IMV join and drain into SMV and into junction between SV & SMV [18,19].

In reference to literature concerned with venous drainage pattern of IMV it has been seen that majority of cases IMV drains into splenic vein at different sites. The inferior mesenteric vein did not drain with equal frequency into the

splenic vein, superior mesenteric vein, or the junction between the superior mesenteric vein and the splenic vein. In our present study though the IMV drained into splenic vein at different sites in 73% cases, into splenic vein in 6% cases and junction of SV & SMV in 20% cases. The present study resembles to the study conducted by Sakaguchi et al.

Table 2: Comparison of IMV drainage pattern.

Authors	IMV draining to SV	IMV draining to SMV	IMV draining to junction of SV & SMV	IMV draining to other sites
Weinhaus, A. J. J. [2]	36.30%	41.60%	21.20%	-
Papavasiliou, P., et al [14]	54%	27%	17%	1%
Graf, O., [13]	56%	26%	18%	-
Sakaguchi, T., S et al [15]	68.50%	18.50%	7.60%	-
Present Study	73%	6%	20%	-

CONCLUSION

The conclusion of this study is that the inferior mesenteric vein does indeed drain into three mesenteric sites: the splenic vein, the superior mesenteric vein, or the junction between the superior mesenteric vein and the splenic vein.

It is imperative for anatomy textbooks to recognize this variable drainage pattern of the inferior mesenteric vein and its associated frequencies, so that students are informed and they are aware of mesenteric anatomical variations that are commonly present.

ABBREVIATIONS

IMV- Inferior mesenteric vein
SMV- Superior mesenteric vein
SV- Splenic vein
PV- Portal vein

Conflicts of Interests: None

REFERENCES

- [1]. Healy J C. Abdomen and Pelvis. In: Standring S, editor. Gray's Anatomy: The anatomical basis of clinical practice: 39th edition. Philadelphia. Churchill living stone. Elsevier:1949.p.1182.
- [2]. Weinhaus A. J. and Henderson A. J. Variation of the drainage pattern of the Inferior Mesenteric Vein. In Clinical Anatomy.2011;24(8):1016-42.
- [3]. Colborn G. L. and Skandalakis J. E. The gastrointestinal tract. In Clinical Gross Anatomy: A guide for dissection study and review. New York: Parthenon Publishing Group Inc.1993.p.418.
- [4]. Drake R. L, Vogl W, & Mitchell A. W. M. Abdomen. In Gray's Anatomy for Students:39th edition. Philadelphia Churchill living stone. Elsevier .2005.p. 305.

- [5]. Ellis H. The abdomen and pelvis. In: Clinical Anatomy: Applied Anatomy for Students and Junior Doctors: 11th edition. India: Blackwell Publishing Ltd: 2006. p. 87.
- [6]. Faiz O and Moffat D. The veins and lymphatics of the abdomen. In: Anatomy at a Glance : 2nd edition. India: Blackwell Publishing Ltd:2006.p.47.
- [7]. Nayak SB, Aithal AP, Melanie RD, Guru A, Kumar N. Unusual jejunal tributaries of the splenic vein and their surgical importance: a case report. OA Case Reports. 2013;2(4):36-7.
- [8]. Manjunatha YC, Beeregowda YC, Bhaskaran A. An unusual variant of the portal vein . J Clin Dia Res. 2012;6(4):731-3.
- [9]. Gorantla VR, Potu BK, Pulakunta T, Vollala VR, Addala PK, Nayak SR. Anomalous formation of the portal vein: a case report. J Vas Bra. 2007;6(4):399-401.
- [10]. Crouch J. E. The Circulatory System. In: Functional Human Anatomy: 2nd edition. Philadelphia: Lea & Febiger:1972.p. 329-30.
- [11]. Netter F. Veins of Stomach, Duodenum and Pancreas. In: Atlas of Human Anatomy. West Caldwell: CIBA-GEIGY Corporation.1989.
- [12]. Rogers A. W. The Blood Supply of the Trunk. In Textbook of Anatomy. New York: Churchill Livingstone. 1992.p.614.
- [13]. Graf O, Boland G. W, Kaufman J. A, Warshaw A. L, Fernandez del Castillo et al. Anatomic variants of mesenteric veins: Depiction with helical CT venography. Amer J Roent. 1997;168(5):1209-13.
- [14]. Papavasiliou P, Arrangoiz R, Zhu F, Chun Y, Edwards K, & Hoffman J. The Anatomic Course of the First Jejunal Branch of the Superior Mesenteric Vein in Relation to the Superior Mesenteric Artery. International Jou Surg Onco.2012;1-4.
- [15]. Sakaguchi T, Suzuki S, Morita Y, Oishi K, Suzuki A, Fukumoto K et al. Analysis of anatomic variants of mesenteric veins by 3-dimensional portography using multidetector-row computed tomography. The American Journal of Surgery.2010;200(1):15-22.
- [16]. Snell, R. The Abdomen: Part II The Abdominal Cavity. In Clinical Anatomy for Medical Students :5th edition. Little, Brown and Company:1995.p.212.
- [17]. Snell, R. S. The Abdomen. In Gross Anatomy Dissector: A Companion for Atlas of Clinical Anatomy . Boston: Little, Brown and Company:1978.p.73.
- [18]. Rogers A. W. The Blood Supply of the Trunk. In Textbook of Anatomy. New York: Churchill Livingstone:1992.p.614.
- [19]. Sauerland, E. K. Grant's Dissector . Baltimore: Williams & Wilkins.:11th edition:1994.p.63-4.

How to cite this article:

Ramandeep Kaur, Anshu Sharma, Mahesh Kumar Sharma, Rupinder Singh, Arun Sharma. VARIATIONS IN DRAINAGE PATTERN OF INFERIOR MESENTRIC VEIN. Int J Anat Res 2017;5(4.2):4581-4584. DOI: 10.16965/ijar.2017.401