

A MORPHOLOGICAL STUDY OF A RARE VARIANT OF GANTZER'S MUSCLE

Shalom Elsy Philip ^{*1}, Dakshayani K.R ^{*2}.

^{*1} Postgraduate, Department of Anatomy, Mysore medical college, Mysore, Karnataka, India.

^{*2} Professor and Head, Department of Anatomy, Mysore medical college, Mysore, Karnataka, India.

ABSTRACT

Background: Flexor digitorum profundus (FDP) is a deep flexor of forearm. The accessory heads of flexor pollicis longus (FPLah) and flexor digitorum profundus (FDPah) are named after Gantzer who described the same in 1831. The less frequent of the two is FDPah, which simulates soft tissue tumor mass or may cause compression neuropathy of anterior interosseous nerve leading to anterior interosseous nerve syndrome or Kiloh-Nevin syndrome.

Aim: To determine the prevalence and morphology of accessory head of flexor digitorum profundus.

Materials and Methods: 50 upper limbs of equal right and left distribution of unknown sex were dissected and examined in the department of anatomy. Morphological parameters such as shape, origin, insertion and relation to nerve of accessory head of FDP were studied.

Results: The prevalence of accessory head of FDP showed 22%. FDPah was most commonly seen on the left side. Most frequently observed shape for FDPah was fusiform and all the accessory heads originated from undersurface of flexor digitorum superficialis and majority of the cases were inserted to middle third of tendon of FDP for index finger. One of the cases had double muscle belly with their tendons inserting to tendon for index finger and middle finger of FDP.

Conclusion: Knowledge of existence of Gantzer's muscle may provide surgeon with information for the differential diagnosis of the causes and sites of anterior interosseous nerve syndrome, also surgical interference for nerve decompression or to differentiate from soft tissue tumors.

KEY WORDS: Gantzer's muscle, Flexor digitorum profundus, Anterior interosseous nerve.

Address for Correspondence: Dr. Shalom Elsy Philip, Postgraduate, Department of anatomy, Mysore medical college and research institute, Irwin road, Yadavagiri, Mysuru, Karnataka- 570001, India.

E-Mail: tfcshalom@gmail.com

Access this Article online	Journal Information
Quick Response code  DOI: 10.16965/ijar.2017.472	International Journal of Anatomy and Research ICV for 2016 90.30 ISSN (E) 2321-4287 ISSN (P) 2321-8967 https://www.ijmhr.org/ijar.htm DOI-Prefix: https://dx.doi.org/10.16965/ijar 
	Article Information
	Received: 11 Oct 2017 Peer Review: 12 Oct 2017 Revised: None
	Accepted: 18 Nov 2017 Published (O): 05 Jan 2018 Published (P): 05 Jan 2018

INTRODUCTION

Flexor digitorum profundus is a deep muscle of the flexor compartment of forearm. It arises about upper three quarters of the anterior and medial surfaces of the ulna and ends in four tendons [1]. Each tendon enters within fibrous flexor sheath and gets inserted to palmar surface of the base of terminal phalanx of medial four fingers [2].

It is supplied by the anterior interosseous nerve (AIN) which descends on the interosseous membrane between the Flexor pollicis longus (FPL) and Flexor Digitorum Profundus (FDP). In 1831, Gantzer described two accessory muscles of FPL and FDP in the human forearm which bear his name and less frequent of accessory head is that of flexor digitorum profundus [3].

The accessory head of FDPah arises from radius,

flexor digitorum superficialis, medial epicondyle or the coronoid process [1]. FDPah can cause anterior interosseous nerve entrapment leading to anterior interosseous syndrome [4] causing pain in the forearm and a characteristic weakness of the pincer movement of the thumb and index finger [5]. This study was done to confirm the prevalence of this accessory muscle to make it easier to determine the exact cause of entrapment and allow greater confidence in the diagnosis.

MATERIALS AND METHODS

The study was carried out in 50 upper limbs of equal right and left distribution (25 right and 25 left) of unknown sex in the department of anatomy, Mysore medical college. The dissection was done by using a volar incision extending from the distal arm to the insertion of muscles. The accessory head was brought into view upon reflection of skin, superficial fascia, palmaris longus, flexor carpi radialis and flexor digitorum superficialis muscle. The distribution

of this accessory muscle in the right and left upper limbs and morphological parameters such as origin, insertion and shape and relation to AIN was noted.

RESULTS AND DISCUSSION

The prevalence of accessory head of flexor digitorum profundus was found to be 22%. FDPah were seen 16% on the right side specimens and 28% on the left side. Co-existence of accessory heads of both FDP and FPL muscles were not observed in any of the limbs. All the accessory heads of FDP were originating from the undersurface of flexor digitorum superficialis, and none from coronoid process or medial epicondyle. 9%, 72.7%, 18.1% of the tendons of FDPah, were getting inserted to upper third, middle third, and lower third of FDP going to index finger respectively (TABLE-1). In one of the limbs, there were two accessory muscles of FDP getting inserted to tendon for index finger and tendon for middle finger of FDP (FIG-1).

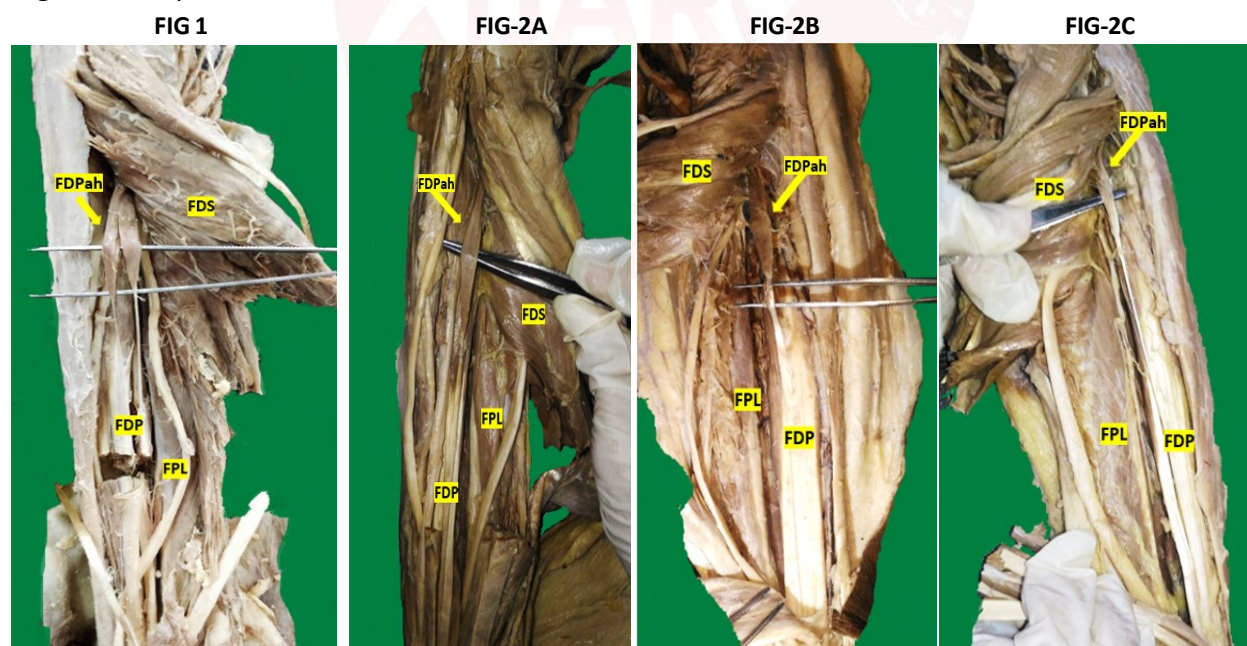


Table 1: Origin, insertion and nerve supply of accessory head of FDP.

Accessory head	Origin	Insertion to FDP (%)	Nerve supply
Flexor digitorum profundus	Undersurface of flexor digitorum superficialis (100%)	Upper third(9%)	Anterior interosseous nerve (100%)
		Middle third(72.7%)	
		Lower third(18.1%)	

Table 2: Incidence of various shapes of accessory head of FDP.

Accessory Head	Shape (%)
Flexor digitorum profundus	Slender (18.1%)
	Fusiform (72.7%)
	Triangular (9%)

Table 3: Comparison of prevalence with other studies.

Sl.No	Authors	Prevalance	Right	Left
1	El Domiaty et al [8]	14.24	0	25
2	Jones et al [9]	27.5	25	12.5
3	Mangini [10]	29	-	-
4	Woods et al [3]	18.6	-	-
5	Bharathi R et al [11]	2	-	-
6	Kida [12]	35.2	-	-
7	Amrita K et al [13]	41.6	29.16	12.5
8	Present study	22	16	28

The shapes of the belly of accessory head of FDP were 18.1% slender, 72.7% fusiform, 9% triangular (TABLE-2). It was observed that the anterior interosseous nerve was posterior and median nerve was anterior to all the accessory heads of both flexor digitorum profundus.

The flexor muscles of the forearm develop from the common flexor mass. During intrauterine life, they gradually divide into superficial and deep layers [6]. Therefore the embryological basis for the existence of additional muscles in the flexor compartment of the forearm may be attributed to the incomplete separation of the flexor mass [7] also as a result of retention of traits in humans reflecting its anatomy of his ancestors.

Among the Gantzer's muscles, accessory head of flexor digitorum profundus is less commonly seen. It has been described with varying prevalence. The studies of El domiaty et al., [8] Jones et al., [9] Mangini, [10], Woods et al., [3] Bharathi et al., [11], Kida [12] showed prevalence of 14.2%, 27.5%, 29%, 18.6%, 2%, 35.2% respectively. The highest prevalence reported was by Amrita K et al [13] (41.6%). In the present study, the prevalence was 22% which is closer to the study of Woods et al [3]. (TABLE-3)

Very few studies have taken side into consideration. FDPah was frequently seen on the left side (28%) than right (16%) though statistically not significant ($p=0.49$). It was similar to study of El domiaty et al [8] who observed 25% on left side and none on right side whereas Jones et al⁹ observed more on right 25% than left side (12.5%) and Bhavya S et al [14] showed equal distribution on both sides.

The origin of this accessory muscle of FDP varies and has been described mainly from the coronoid process or medial epicondyle, or under surface of the flexor digitorum superficialis [1,3,15]. El domiaty et al [8] observed that FDPah took its origin from the under surface of flexor digitorum superficialis in 4 (66.7%) specimens and from the medial epicondyle in 2 (33.3%) specimens. Bhavya S et al [14] observed the origin of accessory head from pronator teres as well as coronoid process of ulna. Jones et al [9] observed, 60% from undersurface of FDS, 13.3% from coronoid process and medial epicondyle, 10% from pronator teres. In the present study, all the accessory head of FDP (22%) originated

from undersurface of FDS which was similar to study of El domiaty et al [8] and Jones et al [9] were, the most common origin is from FDS.

Macalister et al [15] described the insertion into the main muscle in 9 different possible ways: (1) into the index tendon; (2) into the middle tendon; (3) into the ring tendon; (4) into the 5th finger tendon; (5) into the ring and 5th finger tendons; (6) into the index and ring tendons; (7) into the index and 5th finger tendons; (8) into the middle, ring and 5th finger tendons; (9) into the index, middle and ring tendons. In the study of El domiaty et al [8], 66.66% of cases its tendon inserted into the tendon of the index finger and in 33.33% of cases it joined the tendons of middle and ring fingers. Jones et al [9] observed 75% to the upper third, 22.2% to middle third and 2.8% to lower third of FDP. In the present study, 80% of accessory tendon got inserted to middle third of FDP, 20% ended near the wrist i.e lower third, and 10% to upper third. All were inserted to tendon for index finger of FDP similar to study of El domiaty et al [8] (66.6%). However Jones et al [9] observed 40% of tendons inserting to middle finger. In one of the limbs, there were two accessory muscles inserting to tendon for index finger and other to tendon for middle finger of FDP.

FDPah showed characteristic shapes as previously described by Jones et al [9] as being slender (54.5%), triangular (36.4%) or voluminous (9.1%). The study of El domiaty et al [8] found to be slender (66.6%) and triangular (33.3%) shapes. In the present study most commonly seen shape was fusiform (72.7%) (FIG-2A) followed by slender (18.1%), (FIG-2B) and triangular (9%) (FIG-2C).

Usually Gantzer's muscle is asymptomatic but sometimes due to mechanical compression of nerve, partial or incomplete anterior interosseous nerve syndrome also reported since they are closely related to this belly [16]. An incomplete AIN syndrome occurs where only the medial branch of the AIN to the FDP (which passes underneath the belly) is compressed, or the lateral branch to the FPL (which runs alongside the belly) is compressed. This results in the loss of function of only the FDP or the FPL [17]. However, in present study, FDPah, showed no direct contact with the median or anterior

interosseous nerves. Jones et al. [9] mentioned that during its course the FDPah crossed over the ulnar side of the anterior interosseous nerve without any direct contact thus making compression of nerve less likely to occur. Kida et al. [12] described nerve supply of FDPah originated from median nerve while in study of Jones et al. [9], 44.4% of muscles were supplied by median nerve, 55.6% from anterior interosseous nerve. However in present study, nerve supply of all accessory muscle was through AIN. FDPah may also cause restricted movement of the FDP resulting in burning pain in the lower third of the forearm via a muscle-tendon shearing action [18].

CONCLUSION

Gantzer's muscles per say are asymptomatic but are thought to be a causative factor in compression neuropathies in forearm. Accessory head of FDP should be borne in mind while approaching for tendon transfers and surgical intervention, also for making a differential diagnosis of the causes and sites of nerve compression in the forearm.

ABBREVIATIONS

FDP - Flexor digitorum profundus

FPL - Flexor pollicis longus

FDPah - Accessory head of flexor digitorum profundus

AIN - Anterior interosseous nerve

FDS - Flexor digitorum superficialis

Conflicts of Interests: None

REFERENCES

- [1]. Standring S. The anatomical basis of clinical practice. In: Gray's Anatomy. 40th ed. London: Elsevier Churchill Livingstone; 2008:847-848.
- [2]. Datta AK. Essentials of Human Anatomy. 4th ed. Vol. 3. Kolkata: Current Books International; 2009:p71.
- [3]. Wood J. Variations in human myology. Proceedings of the Royal Society of London 1868; 16: 483-525.
- [4]. Parsonage M.J and Turner J.W. Neuralgic amyotrophy; the shoulder-girdle syndrome. The Lancet. 1948 Jun; 26(1): 973-8.
- [5]. Kiloh L.G, and S Nevin. Isolated neuritis of the anterior interosseous nerve. British Medical Journal. 1952 Apr; 4763(1): 850-1.
- [6]. Lewis, W.H. (1910) The development of the muscular system. In: Keibel, F. and Mall, F.P., Eds., Manual of Human Embryology, J. B. Lippincott, Philadelphia, 492- 493.
- [7]. Jones, M., Abrahams, P.H. and Sanudo, J.R. Case report: Accessory head of the deep forearm flexors. J Anat. 1997; 191:313-314.
- [8]. El Domiaty MA, Zoair MM, Sheta AA. The prevalence of accessory heads of the flexor pollicis longus and the flexor digitorum profundus muscles in Egyptians and their relations to median and anterior interosseous nerves. Folia Morphol 2008; 67(1):63-71.
- [9]. Jones M, Abrahams PH, Sanudo JR, Campillo M. Incidence and morphology of accessory heads of flexor pollicis longus and flexor digitorum profundus (Gantzer's muscles). J Anat 1997; 191:451- 455.
- [10]. Mangini U. Flexor pollicis longus muscle its morphology and clinical significance. J Bone Joint Surg. 1960; 42A: 467-470.
- [11]. Bharathi S, Sunitha N.S, Karpagajothi J. Study of Accessory Head of Flexor Pollicis Longus in South Indian Population. IOSR-JDMS. 2017 May; 16(5):36-40.
- [12]. Kida M. The morphology of Gantzer's muscle with special reference to the morphogenesis of the flexor digitorum superficialis. Kaibogaku-Zasshi. 1988; 63: 539-546.
- [13]. Amrita K, Sanjay K, Jawed A, Ruchi R, Vinod K. Morphological Study of Accessory Heads of Deep Flexor Muscle of Forearm. JMSCR. 2017 Jul; 5(7): 25172-76.
- [14]. Bhavya B.S, Maheshwari M, Smitha M. Accessory head of Flexor Digitorum Profundus: A case study. Int J Anat Res 2016; 4(4):2931-35.
- [15]. Macalister A. Additional observations on muscular anomalies in human anatomy (3rd series), with a catalogue of the principal muscular variations hitherto published. Transactions of the Royal Irish Academy. 1875; 25:1-134.
- [16]. Gunnal, S.A., Siddiqui, A.U., Daimi, S.R. and Farooqui, M.S. A study on the accessory head of the flexor pollicis longus muscle (Gantzer's muscle). Journal of Clinical and Diagnostic Research. 2013; 7(3):418-421.
- [17]. Hafez S.A. A report on the accessory head of Flexor Pollicis Longus and Variations of Forearm Musculature. J. Morphol. Sci. 2017; 34(2):98-106.
- [18]. Ryu J, Watson HK. SMB Syndrome (symptomatic supernumerary muscle belly syndrome). Clin Orthop Relat Res. 1987; 216: 195-202.

How to cite this article:

Shalom Elsy Philip, Dakshayani K.R. A MORPHOLOGICAL STUDY OF A RARE VARIANT OF GANTZER'S MUSCLE. Int J Anat Res 2018; 6(1.1):4811-4814. DOI: 10.16965/ijar.2017.472