

A STUDY ON COURSE AND VARIATIONS OF FACIAL ARTERY ON THE FACE

Vasudha T.K ¹, Divya Shanthi D'Sa ^{*2}, Sadashivana Gowda ³.

¹ Associate Professor, Department of Anatomy, Subbaiah Institute of Medical Sciences, Shimoga, Karnataka, India.

^{*2} Assistant Professor, Department of Anatomy, Subbaiah Institute of Medical Sciences, Shimoga, Karnataka, India.

³ Professor, Department of Anatomy, Subbaiah Institute of Medical Sciences, Shimoga, Karnataka, India.

ABSTRACT

Introduction: Face is mainly supplied by the Facial artery supplemented by transverse facial artery. Variations in the course and branching pattern of facial artery are commonly seen. The understanding of these variations of facial artery plays a very important role in facio-maxillary surgeries. It is also of immense importance to radiologists in interpreting facial artery angiography.

Materials and Methods: The present study was conducted in the Department of Anatomy, Subbaiah Institute of Medical Sciences on 50 formalin fixed adult hemi-faces irrespective of sex. The branching pattern, terminations and variations of facial artery on the face were studied.



The facial artery predominantly terminated as angular artery in 28 (56%) hemi-faces, as superior labial artery in 15 (30%) hemi-faces and as lateral nasal artery in 6 (12%) hemi-faces.

Results: An inconstant posterior (pre-masseteric) branch of facial artery was observed in 3 (6%) hemi-faces. In one of the hemi-face we found a deviation in the usual course of facial artery, where the artery deviated towards the infra-orbital foramen then continued and terminated as the lateral nasal artery. An unusual termination of facial artery was observed in one of the hemi-faces where the artery terminated by giving 4 branches in the lower buccal region.

Conclusion: Knowledge of these variations and anomalous branching pattern is of great academic and clinical significance in general practice, Otorhinology, Traumatology, Plastic and Maxillofacial surgeries and Radiology.

KEY WORDS: Facial Artery, Course, Branching Pattern, Variations, Pre-Masseteric Branch.

Address for Correspondence: Dr. Divya Shanthi D'Sa, Assistant Professor, Department of Anatomy, Subbaiah Institute of Medical Sciences, Shimoga -577201, Karnataka, India.
Mobile no: 9448579590 E-Mail: drdivyadsa17@gmail.com

Access this Article online	Journal Information
Quick Response code  DOI: 10.16965/ijar.2017.510	International Journal of Anatomy and Research ICV for 2016 90.30 ISSN (E) 2321-4287 ISSN (P) 2321-8967 https://www.ijmhr.org/ijar.htm DOI-Prefix: https://dx.doi.org/10.16965/ijar 
Article Information	
Received: 20 Nov 2017 Accepted: 02 Jan 2018	
Peer Review: 20 Nov 2017 Published (O): 05 Feb 2018	
Revised: None Published (P): 05 Feb 2018	

INTRODUCTION

Facial artery is the principal artery of the face. It arises from the external carotid artery in the carotid triangle of the neck just above the tip of greater cornu of hyoid bone. It runs upwards and

forwards in the submandibular region, the artery enters the face by winding round the lower border of the mandible at the antero-inferior angle of the masseter, by piercing the investing layer of deep cervical fascia. The course of the

facial artery is divided into two parts, the cervical and the facial. The facial artery is tortuous throughout its extent. The cervical part is tortuous to adapt to the movements of pharynx during deglutition. The facial part is tortuous to adapt to the movements of mandible, lips and cheek. The artery passes through the oblique fibrous cleft of modiolus, an arrangement that may limit the extent to which it is compressed by the contraction of buccolabial musculature [1]. The facial artery gives named and unnamed branches on the face. The named branches are inferior labial, superior labial and lateral nasal. It terminates as angular artery at medial angle of the eye by anastomosing with the dorsal nasal branch of ophthalmic artery.

Premasseteric artery is a small inconstant artery [1]. When present, it passes upwards along the anterior border of masseter and supplies the surrounding tissues.

The inferior labial artery arises just below the angle of the mouth, passes upwards and forwards sinuously near the margin of the lower lip, between the muscle and the mucous membrane.

Superior labial artery is larger and more tortuous than the inferior labial artery, and has a course along the superior labial margin. Lateral nasal artery is given off by the side of the nose. It may be replaced by a branch from the superior labial artery [1-5]. Usually these branches of facial artery anastomose with the corresponding arteries of the opposite side across the midline.

However facial artery is known to show variations in its origin, course and branching pattern and is of significance in Otorhinology, facial trauma, Plastic and Maxillofacial surgeries and Radiology.

MATERIALS AND METHODS

The study was conducted in the Department of Anatomy, Subbaiah Institute of Medical Sciences, Shimoga, on 50 formalin fixed adult hemi-faces. Dissection of the specimens was done following the Cunningham's manual of practical anatomy, volume 3. Course, branching pattern and termination of facial artery on the face was noted and photographed.

RESULTS

The variations of the facial artery in the face were grouped mainly according to three studies, Koh et.al, 2003, Loukas et.al, 2006 and Bayram et.al, 2010. The results were also compared with other studies.

In the present study, we observed that the facial artery predominantly terminated as angular artery in 28 (56%) hemi-faces, as superior labial artery in 15 (30%) hemi-faces and as lateral nasal artery in 6 (12%) hemi-faces. The facial artery had an abortive course in one of the hemi-face (2%). Among these specimens, we found an inconstant posterior (pre-masseteric) branch of facial artery in 3 (6%) hemi-faces.

In one of the hemi-face we found a deviation in the usual course of facial artery, where the artery after giving superior labial branch deviated towards the infra-orbital foramen where it gave an anastomosing branch to infra-orbital artery and then terminated as the lateral nasal artery. Near the infra-orbital foramen it was surrounded by infra-orbital plexus of nerves. An unusual termination of facial artery was observed in one of the hemi-faces where the artery terminated by giving 4 branches in the lower buccal region.

The results of the present study are tabulated in table 1 in comparison with other studies, in table 2 according to Bayram et.al (2010) [4] and in table 3 according to Loukas et.al, (2006) [2].

Table 1: Comparative data of terminal branching pattern from previous studies of the facial artery

Studies	Type I (%)	Type II (%)	Type III (%)	Type IV (%)	Type V (%)	Type VI (%)
Koh et al (n=201)*	20	48	17	10	3	2
Lohn et al (n=200)*	20	49	16	10	3	2
Mitz et al (n=50)*	4	78	0	10	8	0
Niranjan (n=50)*	68	26	2	4	0	0
Midy et al (n=40)*	27.5	30	0	40	0	2.5
Present study (n=50)*	56	12	0	30	0	2

*'n' is sample size.

Table 2: Comparative data of terminal branching pattern of the facial artery with Bayram et al.

Studies	Type I (%)	Type II (%)	Type III (%)
Bayram et al (n = 25)*	76	12	12
Present study (n=50)*	56	30	0

*'n' is sample size.

Note: In 12% facial artery terminated as lateral nasal and in 2% terminated in buccal region without further course.

Table 3: Comparative data of terminal branching pattern of the facial artery with Loukas et al.

Studies	Type A (%)	Type B (%)	Type C (%)	Type D (%)	Type E (%)
Loukas et al (n = 284)*	47.5	38.7	8.4	3.8	1.4
Present study (n=50)*	0	12	30	56	2

*'n' is sample size.

Fig. 1: Normal course of Facial artery (LNA-Lateral Nasal artery, SLA: Superior Labial Artery, ILA: Inferior Labial Artery).

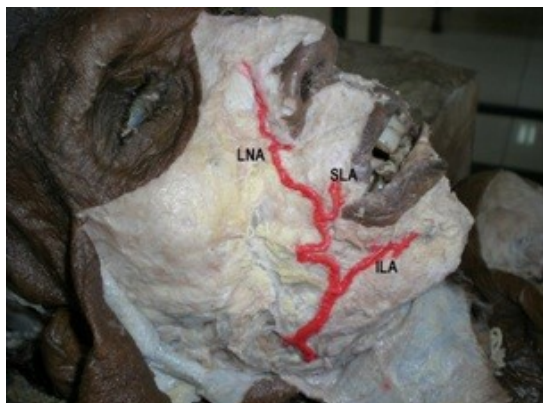


Fig. 2: Termination of facial artery as Superior Labial Artery. Pre-masseteric branch of facial artery is also seen.

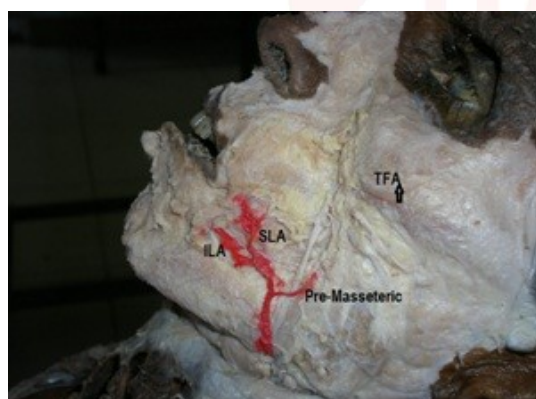


Fig. 3: Facial artery giving an anastomosing branch to infra orbital artery and then terminating as lateral nasal artery.

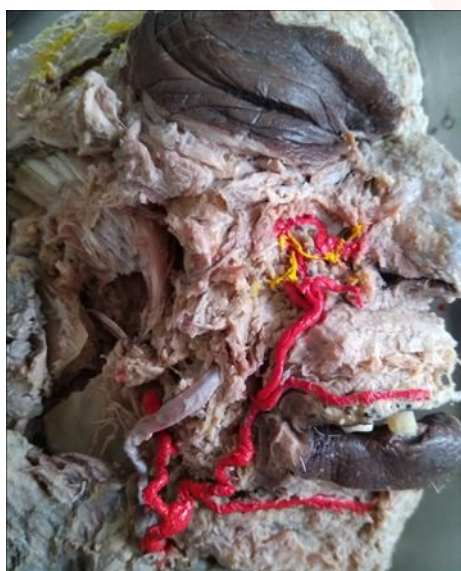

Fig. 4: Facial artery terminating as superior labial artery.

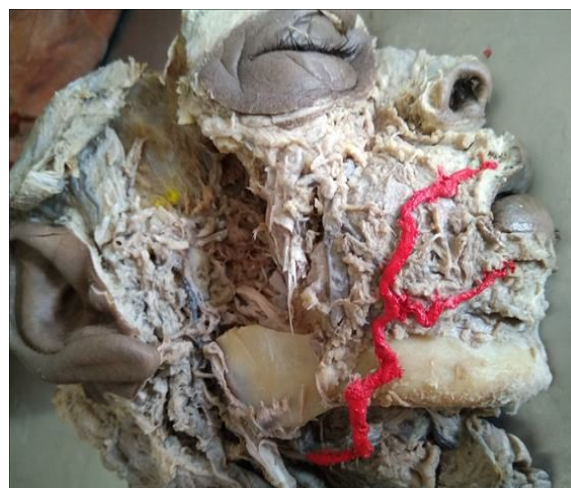
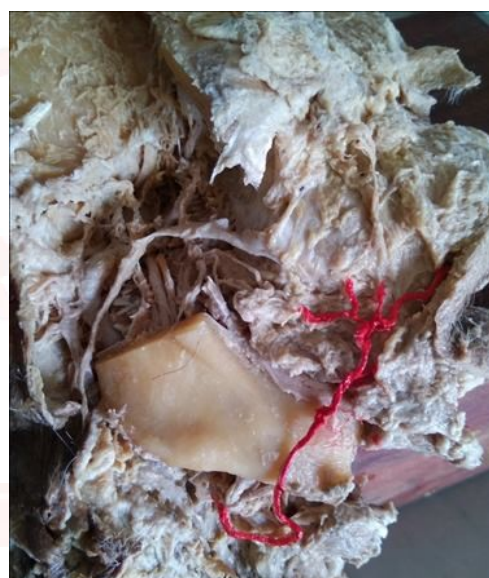
Fig. 5: Facial artery terminating into three unnamed branch and superior labial branch.



DISCUSSION

The knowledge of anatomical characteristics and the variations in origin, course, termination and branching pattern of the facial artery play a significant role in maxillofacial and head-neck surgeries and also in imaging of the head and neck region.

Mitz et.al (1973) [5] study in 50 specimens reported 78% terminating as lateral nasal, 10% as superior labial, 4% as angular and 8% as inferior labial artery.

Midy D et al. (1986)⁶ studied 40 facial arteries and found that the artery terminated as angular artery in 27.5% cases, superior labial in 40%, nasal in 30% cases and abortive artery in only one case.

Koh et al (2003) [2] studied 201 specimens and classified the branching pattern of facial artery

into 6 categories, Type I as angular (20%), Type II as lateral nasal (48%), Type III as alar (17%), Type IV as superior labial (10%), Type V as inferior labial (3%) and Type VI as not detected (abortive course 2%).

Loukas et.al (2006) [3] categorizes the termination of facial artery into five types as Type A where the facial artery bifurcated into superior labial and lateral nasal arteries (47.5%); Type B where facial artery terminated as superior labial and lateral nasal with the lateral nasal continuing as superior alar artery (38.7%); Type C where the termination is as superior labial artery (8.4%); Type D, where angular artery arises directly from the trunk of facial artery with the facial artery ending as superior alar artery (3.8%); and Type E where the facial artery terminated as a rudimentary twig without any significant branches (1.4%).

The variations of facial artery in the fetuses were divided into three categories by Bayram et.al (2010) [4]. Type I category – facial artery terminated as angular artery, in Type II category as superior labial artery and Type III category as inferior labial artery [3].

The study conducted by Lohn et.al (2011) [7] on 201 hemi-faces suggested that the facial artery predominantly terminated as lateral nasal artery in 49% and it was undetectable with transverse facial artery predominance in 5% cases.

Premasseteric artery, an inconstant branch of facial artery which is likely to be injured during maxillofacial surgeries was first described by Adachi [8] in 1928.

According to Niranjana NS (1988) [9], facial artery terminated as angular artery in 68 % of hemi-faces, lateral nasal artery in 26% of hemi-faces, Superior labial artery in 4% of hemi-faces and 2% terminated at the alar base.

Magden et.al (2009) [10] conducted a study on the premasseteric branch, suggested that in 3% cases the diameter of premasseteric branch was larger than the facial artery.

In our study, the facial artery predominantly terminated as angular artery in 28 (56%) hemi-faces, as superior labial artery in 15 (30%) hemi-faces and lateral nasal in 6 (12%) hemi-faces. An unusual posterior (pre-masseteric) branch of

facial artery was found in 3 hemi-faces. In one of the hemi-face, a deviation in the usual course of facial artery was seen and an unusual termination of facial artery was observed in one of the hemi-faces where the artery terminated by giving 4 branches in the lower buccal region. Though it had an abortive course, it gave a significant branch to upper lip.

The construction of numerous facial flaps is based on the rich vascularity of the face. The superior labial artery is mainly manipulated in the reconstruction of lip defects using the Abbe flap and other lip flap procedures [3].

Knowledge of anatomy of facial artery is important in musculo-mucosal flap used in the reconstruction of oronasal fistulas and closure of soft tissue defects in mandibular vestibule [11-13]. Facial artery is selected as a target for superselective intraarterial chemotherapy during the treatment of some cancers of the face [14].

Though the facial artery musculo-mucosal (FAMM) flap has many advantages, its use is limited by variations in the course of the facial artery, especially when it terminates as the inferior labial artery [15,16].

CONCLUSION

The facial artery is the largest and dominant artery of the face. The knowledge of normal course and variations of facial artery is important during maxillofacial, rhinoplastic and orofacial surgeries. The masseter muscle is often used by craniofacial surgeons to correct facial palsy, benign masseteric hypertrophy, or neurectomy-induced atrophy of the muscle. Therefore a clear understanding of the course of the premasseteric branch of the facial artery and its relations with adjacent structures is essential in maneuvering the masseter muscle safely.

Conflicts of Interests: None

REFERENCES

- [1]. Standring S, ed. Gray's Anatomy. The Anatomical Basis of Clinical Practice. 40th Ed., Edinburgh, Churchill Livingstone. 2009;490-491.
- [2]. Koh KS, Kim HJ, Oh CS. et al. Branching patterns and symmetry of the course of the facial artery in Koreans. Int J Oral Maxillofac Surg. 2003;32:414-418.

- [3]. Loukas M, Hullet J, Louis RG Jr, Kapos T, Knight J, Nagy R, et al. A detailed observation of variations of the facial artery, with emphasis on the superior labial artery. *Surg Radiol Anat.* 2006;28(3):316-24.
- [4]. Bayram SB, Kalaycioglu A. Branching patterns of facial artery in fetuses. *The New Journal of Medicine.* 2010;27:227-30.
- [5]. Mitz V, Ricbourg B, Lissan JP. Facial branches of the facial artery in adults: typology, variations and respective cutaneous areas. *Ann Chir Plast.* 1973;18:339-350.
- [6]. Midy D., Mauruc B., Vergnes P., Caliot P., A contribution to the study of the facial artery, its branches and anastomoses; application to the anatomic vascular bases of facial flaps. *Surg Radiol Anat.* 1986;8(2):99-107.
- [7]. Lohn JW, Penn JW, Norton J, Butler PE. The course and variation of the facial artery and vein: implications for facial transplantation and facial surgery. *Ann Plast Surg.* 2011;67(2):184-8.
- [8]. Adachi B. *Arteriensystem der Japaner.* Band I, Kyoto, Verlag der Kaiserlich-Japanischen Universitat zu Kyoto. 1928;73-77 (Japanese).
- [9]. Niranjana NS. An anatomical study of the facial artery. *Ann Plast Surg.* 1988;21(1):14-22.
- [10]. Magden O, Gocmen-mas N, Senan S, Edizer M, Karacayli U, Karabekir HS. The pre-masseteric branch of facial artery: Its importance for craniofacial surgery. *Turkish Neurosurgery.* 2009;19(1):45-50.
- [11]. Pribaz J, Stephens W, Crespo L, Gifford G. A new intra oral flap: facial artery musculomucosal (FAMM) flap. *Plast Reconstr Surg.* 1992;90(3):421-9.
- [12]. Dupoirieux L, Plane L, Gard C, Penneau M. Anatomical basis and results of the facial artery musculomucosal flap for oral reconstruction. *Br J Oral Maxillofac Surg.* 1999;37(1):25-8.
- [13]. Hatoko M, Kuwahara M, Tanaka A, Yurugi S. Use of facial artery musculomucosal flap for closure of soft tissue defects of the mandibular vestibule. *Int J Oral Maxillofac Surg.* 2002;31(2):210-11.
- [14]. Shimizu T, Sakakura Y, Hattori T, Yamaguchi N, Kubo M, Sakakura K. Superselective intraarterial chemotherapy in combination with irradiation: preliminary report. *Am J Otolaryngol.* 1990;11(2):131-6.
- [15]. Furukawa M, Mathes DW and Anzai Y. Evaluation of the facial artery on computed tomographic angiography using 64-slice multidetector computed tomography: implications for facial reconstruction in plastic surgery. *Plastic and Reconstructive Surgery.* 2013;131(3):526-535.
- [16]. Marx, C., Kumar, P., Reddy, S. and Vollala, VR. Bilateral variation of facial artery: a case report. *Romanian Journal of Morphology and Embryology.* 2008;49(3):399-401.

How to cite this article:

Vasudha T.K, Divya Shanthi D'Sa, Sadashivana Gowda. A STUDY ON COURSE AND VARIATIONS OF FACIAL ARTERY ON THE FACE. *Int J Anat Res* 2018;6(1.2):4928-4932. DOI: 10.16965/ijar.2017.510