

## Case Report

# AN ABNORMALLY LONG STYLOID PROCESS WITH OSSIFICATION OF THE STYLOHYOID LIGAMENT

Guarna M <sup>\*1</sup>, Aglianò M <sup>1</sup>.


<sup>\*1</sup>Department of Medical, Surgical Sciences and Neuroscience, University of Siena, Italy.

## ABSTRACT

The styloid process of the temporal bone is an elongated bony projection presenting a variable length as demonstrated in osteometric and radiological studies conducted with different techniques: three-dimensional computed tomography (3dct) or dental panoramic three-dimensional scanning. An elongated styloid process can cause neck pain, dysphagia, headache, sore throat, ear pain, mandibular dysfunction which characterize Eagle's syndrome. Here we present a rare image of an abnormally long styloid process with ossification of left stylohyoid ligament belonging to a bone collection of the local anatomical museum, part of our department, and discovered during routine osteology classes. Also if a direct relation between the length of the styloid process and syndrome of Eagle is not always obvious, radiologists, neurologists, neurosurgeons, dentists, anesthetists and otolaryngologists could be aware of this bone anomaly to diagnose this syndrome.

**KEY WORDS:** Elongated styloid process, Stylohyoid ligament, Ossification, Eagle syndrome.

**Address for Correspondence:** Massimo Guarna, MD Assistant Professor, Department of Medical-Surgical Sciences and Neuroscience, University of Siena, Italy. **E-Mail:** [guarna@unisi.it](mailto:guarna@unisi.it)

Access this Article online	Journal Information
<b>Quick Response code</b>  DOI: 10.16965/ijar.2018.126	<b>International Journal of Anatomy and Research</b> ICV for 2016 90.30 ISSN (E) 2321-4287   ISSN (P) 2321-8967 <a href="https://www.ijmhr.org/ijar.htm">https://www.ijmhr.org/ijar.htm</a> DOI-Prefix: <a href="https://dx.doi.org/10.16965/ijar">https://dx.doi.org/10.16965/ijar</a> 
	Article Information
	Received: 30 Jan 2018 Peer Review: 30 Jan 2018 Revised: None
	Accepted: 07 Mar 2018 Published (O): 05 Apr 2018 Published (P): 05 Apr 2018

## INTRODUCTION

The styloid process (SP) of the temporal bone has a pointed shape and at the origin of the cranial base is covered by a tympanic bony sheath. In the fetus this process originates from Reichert's cartilage of the second brachial arch. This region of Reichert's cartilage has four separate centers of development: the tympanohyal, the stylohyal, the ceratohyal, and the hypohyal which give origin to different parts of styloid chain. The tympanohyal forms the basis of the (SP). The stylohyal becomes the stem of the SP. The ceratohyal part gives rise to the stylohyoid ligament (SL) and the hypohyal part forms the lesser cornu of the hyoid bone. In rare instances Reichert's cartilage developed into a bar of bone extending from the temporal bone to the hyoid bone [1].

The bone process gives insertion to muscles and ligaments: the stylohyoid and stylomandibular ligaments, as well as the muscles styloglossus, stylospharyngeus, stylohyoid [2]. The SL, derived from the ceratohyal part of Reichert's cartilage, extends from the apex of the SP to the tip of the lesser cornu of the hyoid bone. For unknown reason the ligament occasionally ossifies and forms a solid structure. However, the complete ossification is rare. Several studies conducted with different technique reported a variable length for the styloid process. Jung et al [3] with the study of panoramic radiography found an average value of 28 mm in length and claimed that the SP should be considered to be elongated, when its length was greater than 45 mm. As reported by Patil et al [4], in a recent osteometric study, the mean of length of SP was

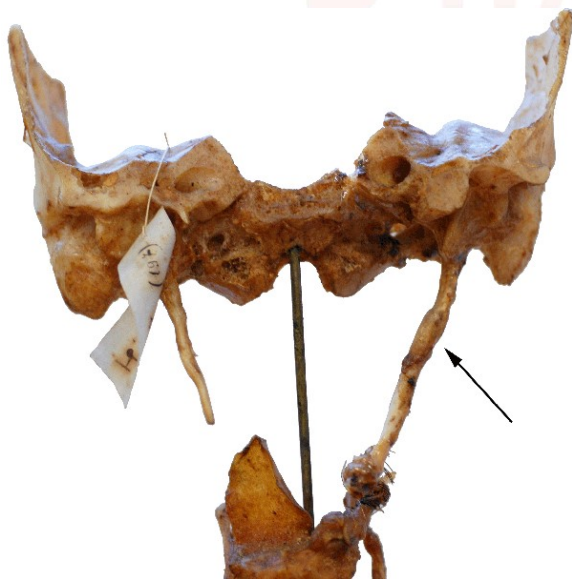2.58 cm, and a SP longer than 3 cm was identified as an elongated SP.

Although partial ossification of the SL is not uncommon, complete ossification is rare. We present the image of a rare anomaly characterized by a temporal bone SP abnormally long with a left ossified SL. The anatomical preparation belonged to a bone collection of the local anatomical museum of Siena "Leonetto Comparini." part of our department.

### CASE REPORT

The SP length was measured using a digital caliper and photographed. The SP was long 50 mm on the right and 70 mm on the left (fig 1). The abnormally elongated SP was due to ossification of the SL (fig1). It was attached to the skull base superiorly, just in front of the mastoid process, and inferiorly attached to the hyoid bone.

**Fig. 1:** Arrow pointing the elongated styloid process and calcified stylohyoid ligament.



### DISCUSSION

Cases of such a long SP in the dried human skull reported in the literature are quite scant while there are several radiologic studies of this anatomic anomaly. Prabhu et al [5], reported a case of bilateral elongated SP with the length of 60 and 59 mm on the right and left side, respectively. Paraskevas et al [6] presented a case of the dried skull with an elongated right SP with a length of 58 mm. Ishwar et al [7] reported a bilaterally elongated SP in dried skull measuring 60 mm.

Beder et al.[8] diagnosed SP with the length of 42.5 mm on the right side and 41.5 mm on the left side by computed tomography. Using the same imaging technique, Savranlar et al [9] described a case of elongated SP with the length of 45.6. Vougiouklakis reported in an autoptic study [10] that 11/1215 of the cadavers had complete calcification of the SL. Nine out of the eleven cases were bilateral and 2/11 cases show unilateral ossification on the left side. These earlier large series suggest that a fully ossified and abnormally thickened SL is rare and atypical [11].

Langlais et al [12] recognizes three types of elongated and ossified styloid processes: the first two are interrupted and have pseudo-articulations, the third is an uninterrupted segment formed by the ossified SL. Our case belongs to the third type. Campos et al. [13] reported that the etiology of styloid bone elongation can be explained by a genetic alteration or according to several theories. The ossification of the SL could be caused by a pharyngeal trauma which causes metaplastic change. According to the anatomic variance theory, the elongated SP and the ossified SL are anatomical variations that occur without any trauma.

**Clinical significance:** The abnormal length of SP or the calcification /ossification of SL causing a pressure on neural and vascular structures is sometimes accompanied by a set of symptoms, as neck pain, dysphagia, headache, sore throat, ear pain, mandibular dysfunction which characterize Eagle's syndrome [14].

About 4% of the population has an elongated SP, but only 4 to 10.3% of this group has symptoms of this syndrome [15]. Also, if a direct relation between the length of the styloid process and syndrome of Eagle is not always obvious, we can assume that the person with this anomaly may have experienced this syndrome. In the present case, on the left side, we have observed ossification of SL. Diffuse ossification of SL is very rare, and it may remain asymptomatic throughout life. However, especially in older patients it may restrict the neck movements, and difficulty may arise during intubation. An immobile larynx, due to SL ossification would cause difficulties in direct laryngoscopy.

There might be serious traumatic consequences and possible risk of regurgitation and aspiration especially in emergency situations. Knowledge of the existence of an elongated styloid process and of its possible ossification must be well present to anatomists, radiologists, anesthesiologists, dentists, neurosurgeons and otolaryngologists.

#### ABBREVIATIONS

**SP** - Styloid Process

**SL** - Stylohyoid Ligament

**Conflicts of Interests: None**

#### REFERENCES

- [1]. Baugh RF, Stocks RM. Eagle's Syndrome: A reappraisal. *Ear Nose Throat J* 1993;72:341-344.
- [2]. Fini G, Gasparini G, Filippini F, Becelli R, Marcotullio D. The long styloid process syndrome or Eagle's syndrome. *Journal of Cranio-Maxillofacial Surgery* 2000;28:123-127.
- [3]. Jung T, Tschernitschek H, Hippen H, Schneider B, Borchers L: Elongated styloid process: when is it really elongated? *Dentomaxillofac Radiol* 2004;33(2):119-24.
- [4]. Patil S, Ghosh S, Vasudeva N: Morphometric Study of the Styloid Process of Temporal Bone. *Journal of Clinical and Diagnostic Research* 2014;8(9):4-6.
- [5]. Prabhu LV, Kumar A, Nayak SR, Pai MM, Vadgaonkar R, Krishnamurthy A, Madhan Kumar SJ: An unusually lengthy styloid process. *Singapore Med J* 2007;48(2):34-36.
- [6]. Paraskevas G K, Raikos A, Lazos LM, Kitsoulis P: Unilateral elongated styloid process: a case report. *Cases Journal* 2009;2:9135.
- [7]. Ishwar B, Gavishiddappa H, Balasaheb P, Balappa B, Ambadasu B: Bilateral elongated styloid process: its anatomical embryological and clinical implications *Int J Med Res Health Sci* 2013;2(2):273-276.
- [8]. Beder E, Ozgursoy OB, Karatayli Ozgursoy S, Anadolu: Three-dimensional tomography and surgical treatment for Eagle's syndrome. *Ear Nose Throat* 2006;85(7):443-5.
- [9]. Savranlar A, Uzun L, Uður MB, Ozer T. Three-dimensional CT of Eagle's syndrome. *Diagn Interv Radiol* 2005;11(4):206-9.
- [10]. Vougiouklakis T: Overview of the ossified stylohyoid ligament based in more than 1200 forensic autopsies. *J Clin Forensic Med* 2006;13:268-270.
- [11]. Prakash B B, Huban T, Punnose HT. Ossified stylohyoid ligament: A case report. *IAIM* 2016;3(5):184-187.
- [12]. Langlais RP, Miles DA, Van Dis ML. Elongated and mineralized stylohyoid ligament complex: A proposed classification and report of a case of Eagle's syndrome. *Oral Surg Oral Med Oral Pathol* 1986;61:527-32.
- [13]. Campos D, Silva TH, Kipper JF, Piazza J, Kraether N. Ossification of styloid ligament and its clinical implication: a report of human cases. *J. Morphol. Sci* 2011;28(2):137-139.
- [14]. Eagle WW. Elongated styloid processes: report of two cases. *Arch Otolaryngol* 1937;25:584-587.
- [15]. Murtagh RD, Caracciolo JT, Fernandez G. CT findings associated with Eagle syndrome. *Am J Neuroradiol* 2001;22:1401-1402.

#### How to cite this article:

Guarna M, Aglianò M. AN ABNORMALLY LONG STYLOID PROCESS WITH OSSIFICATION OF THE STYLOHYOID LIGAMENT. *Int J Anat Res* 2018;6(2.1):5101-5103. DOI: 10.16965/ijar.2018.126