International Journal of Anatomy and Research,
Int J Anat Res 2018, Vol 6(2.2):5191-96. ISSN 2321-4287
DOI: https://dx.doi.org/10.16965/ijar.2018.151

Original Research Article

MORPHOLOGICAL CLASSIFICATION OF SUPRASCAPULAR NOTCH IN DRY SCAPULAE FROM POPULATION OF GUJARAT: A DATABASE FOR SHOULDER ARTHROSCOPY

Ukti Desai [1], Ashish Rathwa[*2], Sanjay Chavda [3].

[1] Tutor, Department of Anatomy, Government Medical College, Vadodara, Gujarat, India.

*[2] Tutor, Department of Anatomy , PDU Government Medical College, Rajkot, Gujarat, India.

[3] Assistant Professor, Department of Anatomy , PDU Government Medical College, Rajkot, Gujarat, India.

ABSTRACT

Background: The Suprascapular Notch (SSN) is located at the superior edge of the scapula. The information of variations in shapes and classification can be obliging to surgeons to correlate the suprascapular nerve entrapment with a specific type of notch. The aim of this study is to document the occurrence of morphological variations in shape of suprascapular notch in dry scapulae which belongs to population of Gujarat & evaluate it with prevalence among various races of world to know its clinical significance.

Methods: Total two hundred dry and intact adult human scapulae were studied of mixed sex of Indian origin derived from various medical colleges of Gujarat. All Measurements were taken by classical osteometry with the help of electronic calipers with the accuracy of 0.01mm in millimetres.

Results and Interpretation: The most common type of SSN observed was Type 2, a notch that was longest in its transverse diameter. The least common type was Type 4. Type 5 SSN was absent. The most common shape was 'J' and least common was 'V'. Partial and complete ossification was also noted.

Conclusion: Knowledge of anatomical variations of suprascapular notch is better for understanding location and source of entrapment syndrome. Since, the present study is performed with a limited number of dry scapulae, so there is need of further clinical, radiological and cadaveric studies.

KEY WORDS: Suprascapular notch, Scapulae, arthroscopy

Address for Correspondence: Dr. Ashish Rathwa, Department of Anatomy, PDU Government Medical College, Rajkot – 360001, Gujarat, India. **E-Mail:** aashish.rathwa60@gmail.com

Access this Article online	Journal Information
Quick Response code	**International Journal of Anatomy and Research** ICV for 2016 90.30 ISSN (E) 2321-4287 | ISSN (P) 2321-8967 **https://www.ijmhr.org/ijar.htm** **DOI-Prefix:** https://dx.doi.org/10.16965/ijar
DOI: 10.16965/ijar.2018.151	**Article Information** Received: 16 Feb 2018 Accepted: 05 Apr 2018 Peer Review: 16 Feb 2018 Published (O): 05 May 2018 Revised: None Published (P): 05 May 2018

INTRODUCTION

The scapula also known as shoulder blade which is flat bone triangular in shape located on the posterolateral feature of thoracic cage and overlying 2nd to 7th ribs. It has two surfaces-costal and dorsal, three edges-superior, lateral (axillary) and medial(vertebral) with three angles- superior, inferior and lateral (glenoid). The triangular shape of the scapula is thin and translucent superior and inferior to the scapular sipne (Moore and Dalley, 1999) [1]. The superior edge pulls out from the superior angle to the lateral angle, of three borders it is the thinnest and shortest. The suprascapular notch is located in the lateral part of the superior bordrer near the bottom of the corocoid process. This notch is converted into a foramen (suprascapular foramen) by the superior tranverse

scapular ligament and it transmit suprascapular nerve (Williams, Bannister, Bery el, 2004) [2]. The suprascapular nerve is the largest branch of upper trunk of brachial plexuses. It supplies both supraspinatus and infraspinatus muscles and gives articular branches to the shoulder and acromioclavicular joints [3].

Approximately 1–2% of all shoulder ache is caused by the suprascapular nerve entrapment syndrome [4]. Kopell and Thompson was the first to explain the suprascapular nerve entrapment in 1959 [5]. Many researchers have recognized that the morphological variation of the suprascapular notch and the ossification of the STSL is the origin of suprascapular nerve entrapment syndrome [5-9]. The shape and size of the notch may be a reason in suprascapular nerve entrapment because narrow suprascapular notch have been found in patients with this syndrome [4, 10-14]. It is essential for clinical practice because a range of techniques are connected with the athroscopic decompression of the nerve [15].

MATERIALS AND METHODS

Total two hundred dry and intact adult human scapulae were studied of mixed sex of Indian origin derived from various medical colleges of Gujarat. (Pramukhswami medical college, Karamsad; Government medical college, Baroda; B. J. medical college, Ahmedabad and Government medical college, Surat) All Measurements were taken by classical osteometry with the help of electronic calipers with the accuracy of 0.01mm in millimeters.

The scapulae were studied for, two parameters. One was the morphometry of suprascapular notch and second was dimensions of scapula to delimit the safe zone during shoulder arthroscopy

For the morphometry of suprascapular notch, the intact scapulae were observed either for the presence or absence of suprascapular notch or for the presence of bony foramen .The suprascapular notch, where the superior transverse scapular ligament had been partially ossified was included in non-ossified type as it still presented with a notch rather than complete bony foramen. When the notch was present, the following measurements were taken in millimeters. For notch dimensions transparent rulers, compass and electronic calipers were used for precision.

Each scapula was put on the desk with the anterior surface up. The two tips of the compass were placed on the two superior corners of the notch. With the help of a transparent ruler it was supported and then measured with the electronic calipers. Another transparent ruler was put perpendicular to it up to the deepest point of the suprascapular notch and it was measured with electronic calipers. Now the first ruler was put perpendicular to it to take the middle transverse diameter with the electronic calipers.

RESULT AND DISCUSSION

Table 1 suggests distribution of the suprascapular notch in the present study sample of two hundred dry adult human scapulae of Indian origin. It shows 32 (16%) having suprascapular notch Type I, 83 (41.5%) categorized having Type II, 78 (39%) have been included in Type III, while 7 (3.5%) were showing complete ossification of Superior Transverse Scapular Ligament, were classified as Type IV. In this study, a scapula with presence of suprascapular notch with suprascapular foramen or double suprascapular foramen (Type V) was not found.

Table 2 suggests that 32 (16%) scapulae were showing absent notch, 83(41.5%) which belong to Type II were shallow U shaped notch, 35 (17.5%) were deep wide U and Type III suprascapular notch, 25 (12.5%) were Type III and deep narrow U shaped notch, 16 (8%) were V shaped Type III and 2 (1%) were vertically oval Type III suprascapular notch. Complete foramen was observed in 7 (3.5%) scapula which belong to Type IV suprascapular notch and this type shows complete ossification of the superior transverse scapular ligament.

Table 1: Distribution of various types of suprascapular notch in Gujarat population studied on 200 individuals.

Type of Notch	Frequency	Percentage
I	32	16%
II	83	41.50%
III	78	39%
IV	7	3.50%
Total	200	100%

Table 2 suggests that there are variations in the incidence of Type I (without a discrete notch) suprascapular notch in different populations ranging from 5% to 16%. In Indian population, attempts have been made to classify suprascapular notch by Soni et al. [12] and Mahato and Suman [16]. Total number of scapulae was less than present study in the above mentioned studies. Soni et al. (2012) reports were based on hundred scapulae, while Mahato and Suman (2013) reports were based on one hundred and twelve scapulae. They observed frequency 19.64% of Type I suprascapular notch, while in case of Soni et al. (2012) frequency of Type I was noted 5%. In present study, 16% scapulae were having Type I suprascapular notch. Soni et al. [12] performed the study in North Indian population, while Mahato and Suman [16] performed in South Indian population. Present study which was done in West Indian population, frequency of Type I correlates with the study results of Mahato and Suman [16]. This suggests that frequencies of absent notch closely correlate in West and South Indian population.

Table 2: Distribution of different types of suprascapular notch according to the shape.

Serial No.	Shape	No. of scapula	Percentage	Type of Notch
1	Absent notch	32	16%	I
2	Shallow U	83	41.50%	II
3	Deep wide U	35	17.50%	III
4	Deep narrow U	25	12.50%	III
5	V shaped	16	8%	III
6	Vertical Oval	2	1%	III
7	Complete foramen	7	3.50%	IV
Total		200	100%	

Table 3: Different types of suprascapular notch in different population and the comparison with the previous studies and the present study.

Workers (N, Population)	Type I	Type II	Type III	Type IV	Type V
Natsis et al. 2007 (423, Greek)	8.30%	41.50%	41.50%	7.30%	0.70%
Wang et al. 2011 (295, Chinese)	9.52%	58.16%	28.23%	4.08%	None
Mahdy and Shebab. 2013 (132,Egypt)	6.06%	45.45%	43.93%	3.03%	1.50%
Soni et al. 2012 (100, India)	5%	72%	20%	3%	None
Present Study (200, India)	16%	41.50%	39%	3.50%	None

Table 3 suggests the highest incidence of absent notch (16%) as compared to the results of other studies in the table. As per present findings, the frequency of Type I notch was double in Indian population, as compared to the frequency of Type I notch Greek and Chinese populations and it was about three times more than the frequency of Type I notch in Egyptian population.

Table 3 suggests that Type II (shallow notch) has highest incidence out of all the other types in all the populations compared in the table. According to Natsis et al. [17] both the types II and III are showing similar incidence (41.5%). According to these findings inference can be derived that most frequently found type of notch is Type II in all these populations.

Type III (deep notch) is the second most common incidence in these populations (Table 19). The frequency of Type III notch is higher in Egypt and Greek as compared to Asian population.

The incidence of Type IV (complete ossification of superior transverse scapular ligament) is lowest in all populations mentioned in Table 19, which is ranging from 3% to 7.3% in the given populations. Ticker et al. [6], Alon et al. [18] and Cohen et al. [19] studied the variations in morphology of superior transverse scapular ligament which included its complete ossification. It can be one of the predisposing factors for suprascapular nerve entrapment. The incidence of complete ossification of suprascapular ligament varies widely in different populations. In Brazilian population its incidence is reported highest to be 30.76% [20] as compared to other populations. In Italian Population it is to be 6.1% as described by Vallois [21].In Greek population, [17] the incidence was 7.3%. Turkish population, Urguden et al. [22] noted incidence was 6% and Bayramoglu et al. [9] found it was 12.5%. In American population, it was 3.7% as noted by Edelson [23] and 4% by Rengachary et al. [24] and in Chinese population Wang et al. [25] noted 4.08%. In the present study (India), complete ossification of the ligament was noted to be 3.5%.Greek, Italian and Turkey are Mediterranean countries that may be the reason the findings are close to each other. On the other hand, In American, Indian and

Chinese studies, findings correlate to each other. This indicates there are differences in different populations at the level of ossification of ligament.

In present study suprascapular notch Type II and Type III were further classified in various shaped as given in Table 4.

Table 4: Distribution of different types of suprascapular notch according to the shape.

Serial No.	Shape	No. of scapula	Percentage	
1	Absent notch	32	16%	Type I
2	Shallow U	83	41.50%	Type II
3	Deep wide U	35	17.50%	Type III
4	Deep narrow U	25	12.50%	Type III
5	V shaped	16	8%	Type III
6	Vertical Oval	2	1%	Type III
7	Complete foramen	7	3.50%	Type IV
Total		200	100%	

In present study, an attempt was made for further classification of Type II and Type III notch into various shapes based on STD, MD and MTD values. (Table 4)

To classify suprascapular notch according to shape the ratio of Maximum Depth and Middle Transverse Diameter has been considered along with value of Superior Transverse Diameter.

When the MD: MTD ratio was 0.70-0.99 it suggested shallow U shaped notch.

When the MD:MTD ratio was 1.00-1.30 it suggested deep wide U shaped notch.

When the MD:MTD ratio was 1.40-1.69 it suggested deep narrow U shaped notch.

When the MD:MTD ratio was 1.70-1.99 with STD value higher than value of MTD it suggested V shaped notch.

When the MD:MTD ratio was 2.00-2.60 and STD value was less than MTD, suggested Vertical Oval shaped notch.

An attempt was made to classify the notch further so that more varieties of suprascapular notch can be classified.

Sinkeet et al. [26] reported that suprascapular nerve entrapment neuropathy is associated with the morphology of the suprascapular notch. Their study revealed three morphological variations (U, V and J) of suprascapular notches in one hundred eighteen scapulae derived from Kenyan population. The most common was U shape (76.27%) that 18.64% had nearly parallel lateral margins. Ticker et al. [6] found U shaped suprascapular notch in 77% scapulae in American population.

Fig. 1: Classification of suprascapular notch based on measurements of Superior Transverse Diameter (STD), Maximum Depth (MD) and Middle Transverse Diameter (MTD). A: Deep narrow U shape, B: Deep wide U shape, C: Shallow U shape D: V shape and E: Vertical oval shape.

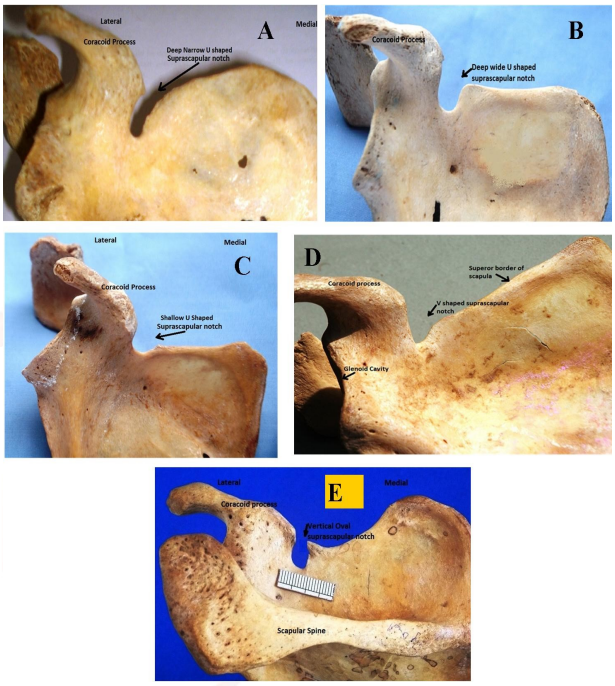

Bayramoglu et al. [9] found U shaped notch in 62.5% in Turkish population. Duparc et al. [27] observed U shaped notch in 63.3% scapulae in France. Meanwhile, Soni et al. [12] in India found U shaped notch in 58%. In present study, U shaped notch (71.5%) has been most commonly observed.

In the present study, as mentioned above U shaped notches have been further classified according to its vertical and transverse dimensions and classified with the type of the notch (Table 20). In present study, 83 (41.5%) scapulae had shallow U shaped notch which belong to Type II suprascapular notch , 35 (17.5%) were showing deep wide U shaped notch and deep narrow U was found in 25 (12.5%) scapulae and both deep wide and deep narrow U shaped notch belong to Type III suprascapular notch. The size and shape of suprascapular notch is thought to play a part in predisposition of suprascapular nerve entrapment assuming that narrow notch provides more chance to entrap the nerve than the larger and shallower notch. Therefore deep

narrow U shaped notch has more chance for suprascapular nerve entrapment than shallow U shaped notch.

Second most common morphological variation in shape of the suprascapular notch that had been observed in present study was V shaped notch which was present in 8% scapulae. Ticker et al. [6] found in 23% (America), Bayramoglu et al. [9] found in 25% (Turkey), Duparc et al. [27] in 36.5% (France), Soni et al. [6] in 7% (India) and Mahdy et al. [28] in 13.56% (Egypt). The observation in present study is similar to Soni et al. [12] (India). Dunkelgrun et al. [29] stated that U shaped notches had a larger area than V shaped notches, leading to an assumption that a V shaped notch is more vulnerable to suprascapular nerve entrapment. This suggests that in Indian population V shaped notch is relatively less frequent than other populations. It can be speculated that suprascapular nerve entrapment because of V shaped notch are minimal in Indian population.

Although it has been hypothesized that suprascapular nerve entrapment is more likely to be associated with a narrow V shaped notch, no direct correlation between such observed shapes (U,V, J) and suprascapular nerve entrapment has been shown clinically [30]. Therefore, not only the shape and diameter of the notch, but also the morphology of suprascapular ligament should be considered for suprascapular nerve entrapment.

CONCLUSION

In present study, classification of suprascapular notch has been done as per the shape and size in various types. First, Superior Transverse Diameter (STD), Maximum Depth (MD) and Middle Transverse Diameter (MTD) of each notch have been measured. First, Suprascapular notch has been classified in to four different types. Type I was an absent notch (16%), Type II was a shallow notch where MTD was higher than MD (41.5%), Type III was a deep notch where MD was higher than MTD (39%) and Type IV where the notch was converted into foramen by ossified superior transverse scapular ligament (3.5%). Further classification of Type II and Type III suprascapular notch has been done in to various shapes according to the above mentioned measurements. When the MD: MTD ratio was 0.70-0.99 it suggested shallow U shaped notch (41.5%), all belong to Type II suprascapular notch. Deep wide U, deep narrow U, V shaped and Vertical oval belonged to Type III (deep) notch. When the MD:MTD ratio was 1.00-1.30 it suggested deep wide U shaped notch (17.5%). When the MD:MTD ratio was 1.40-1.69 it suggested deep narrow U shaped notch(12.5%). When the MD:MTD ratio was 1.70-1.99 with STD value higher than value of MTD it suggested V shaped notch (8%). When the MD:MTD ratio was 2.00-2.60 and STD value was less than MTD, suggested Vertical Oval shaped notch(1%). STD has been also used to classify the suprascapular notch in the present study along with MD and MTD unlike other studies where they have used only MD and MTD. An attempt has been made for further classification of the notch in the present study.

Therefore, the qualitative and quantitative research on the morphological variability of suprascapular notch of human scapulae provides precise and well sorted data about suprascapular notch variations and localization in Indian Population which supplements the existing reports of its kind by providing more varieties of suprascapular notch and it contributes to the further understanding of human suprascapular notch.

Conflicts of Interests: None

REFERENCES

[1]. Moore KL, Dalley AF. Clinically oriented anatomy. 4th edition Philadelphia, USA: Lippincoth Williams and Wilkins. 1999;668-69.

[2]. Willimams PL, Bannister LH, Bery MM, Collins P, Dyson M, Dussek JE. MWJ Gray's anatomy.38th edition London: Churchill-LIVINGSTONE, 2004.

[3]. Standring S, "Pectoral girdle and upper limb" in Gray's Anatomy: The Anatomical Basis of Clinical Practices, Johnson D & Collins P. , Eds. Churchill Livingtone, New York, USA, 40th edition, 2008. pp.793-821.

[4]. Polguj M, Jêdrzejewski K, Majos A, Topol M. Variations of bifid superior transverse scapular ligament as a possible factor of suprascapular entrapment: A anatomical study International orthopaedics 2012;36:2095–2100.

[5]. Kopell HP, Thompson Wal. Pain and the frozen shoulder. Surg gynecol obstet, 1959;109: 92–96.

[6]. Ticker JB, Djurasovic M, Strauch RJ, April EW, Pollock RG, Flatow EL, et al. The incidence of ganglion cysts and other vari-ations in anatomy along the course of the suprascapular nerve. J shoulder elbow surg.1998;7(5):472-8.

[7]. Osuagwu FC, Imosemi IO, Shokunbi MT complete ossification of the superior transverse scapular ligament in a nigerian male adult. Int j morphol. 2005;23(2):121-2.

[8]. Callahan JD, Scully TB, Shapiro SA, Worth RM. Suprascapular nerve entrapment: a series of 27 cases. J neurosurg. 1991;74:893- 6.

[9]. Bayramoglu A, Demiryürek D, Tüccar E. Variations in anatomy at the suprascapular notch possibly causing suprascapular nerve entrapment: an anatomical study. Knee surg sports traumatol ar-throsc. 2003;11: 393-8.

[10]. Jadhav SD, Patil RJ, Roy PP, Ambali MP, Doshi MA, Desai RR. Supra scapular foramen in indian dry scapulae.njca. 2012;1(3):133-135.

[11]. Shane tubbs, Carl Nechtman, Anthony V. D'antoni, Mohamma-dali M.Shoja Martin M. Mortazavi, Marios Loukas, Curtis J. Rozzelle, and Robert J. Spinner ossification of the suprascapular ligament: a risk factor for suprascapular nerve compression? Int J shoulder surg. 2013 jan-mar;7(1):19–22.

[12]. Soni G, V.S. Malik, L.Shukla, S. Chabbra, N. Gaur: Mor-phometric analysis of the suprascapular notch. The internet journal of biological anthropology. 2012;5. doi:10.5580/2b19

[13]. Khan, M.A. complete ossification of the suprascapular trans-verse ligament in an male adult. Int. J. Morphol., 2006;24(2):195-196.

[14]. Vyas KK, Rajput HB, Zanzrukiya KM, Suttarwala I, Sarvaiya BJ, Shroff BD. An osseous study of suprascapular notch and various dimentions of safe zone to prevent suprascapular nerve injury. Indian Journal of Applied Basic Medical Sciences. 2013;15(20):27-39.

[15]. Lafosse L, Tomasi A, Corbett S, Baier G, Willems K, Gobezie R. Rthroscopic release of suprascapular nerve entrapment at the suprascapular notch: technique and preliminary results. Arthroscopy, 2007;23:34–42.

[16]. Mahato R. K., Suman P. Complete absence of suprascapular notch: A risk factor for suprascapular nerve neuropathy, J evolution of Medical and Dental Sci. 2013;2(25):4542.

[17]. Natsis K, Totlis T, Tsikaras P, Appell HJ, Skandalakis P, Koebke J. Proposal for classification of the suprascapular notch: a study on 423 dried scapulas. Clin Anat. 2007;20(2):135-9.

[18]. Alon M, Weiss S, Fishel B, Dekel S. Bilateral suprascapular nerve entrapment syndrome due to an anomalous transverse scapular ligament. Clin Orthop Relat Res. 1988;234:31-3.

[19]. Cohen SB, Dines DM, Moorman CT. Familial calcification of the superior transverse scapular ligament causing neuropathy. Clin Orthop Relat Res. 1997;334:131-5.

[20]. Silva JG, Abidu M, Fernandes R, Aureliano R, Sgrott E, Silva S, Babinski M. High incidence of complete ossification of the superior transverse scapular ligament in Brazilians and its clinical implications, Int J Morphol. 2007;25(4):855-859.

[21]. Vallois H.V. L'os acromial dans les races humaine. L'anthropologie. 1925;35:977-1022.

[22]. Urgüden M, Ozdemir H, Dönmez B, Bilbaþar H, Oðuz N. Is there any effect of suprascapular notch type in iatrogenic suprascapular nerve lesions? An anatomical study. Knee Surg Sports Traumatol Arthrosc. 2004;12(3):241-5.

[23]. Edelson JG. Bony bridges and other variations of the suprascapular notch. J Bone Joint Surg Br. 1995;77(3):505-6.

[24]. Rengachary SS, Burr D, Lucas S, Hassanein KM, Mohn MP, Matzke H. Suprascapular entrapment neuropathy: a clinical, anatomical, and comparative study. Part 2: anatomical study. Neurosurgery. 1979;5(4):447-51.

[25]. Wang HJ, Chen C, Wu LP, Pan CQ, Zhang WJ, Li YK. Variable morphology of the suprascapular notch: an investigation and quantitative measurements in Chinese population. Clin Anat. 2011;24(1):47-55.

[26]. Sinkeet SR, Awori KO, Odula PO, Ogeng'o JA, Mwachaka PM. The suprascapular notch: its morphology and distance from the glenoid cavity in a Kenyan population. Folia Morphol (Warsz). 2010;69(4):241-5.

[27]. Duparc F, Coquerel D, Ozeel J, Noyon M, Gerometta A, Michot C. Anatomical basis of the suprascapular nerve entrapment, and clinical relevance of the supraspinatus fascia. Surg Radiol Anat. 2010;32(3):277-84.

[28]. Mahdy A, Shehab A. Morphometric Variations of the suprascapular Notch as a potential cause of neuropathy: Anatomical Study, J American Sci. 2013;9(3):189-197.

[29]. Dunkelgrun M, Iesaka K, Park SS, Kummer FJ, Zuckerman JD. Interobserver reliability and intraobserver reproducibility in suprascapular notch typing. Bull Hosp Jt Dis. 2003;61(3-4):118-22.

[30]. Cummins CA, Bowen M, Anderson K, Messer T. Suprascapular nerve entrapment at the spinoglenoid notch in a professional baseball pitcher. Am J Sports Med. 1999;27(6):810-2.

How to cite this article: Ukti Desai, Ashish Rathwa, Sanjay Chavda. MORPHOLOGICAL CLASSIFICATION OF SUPRASCAPULAR NOTCH IN DRY SCAPULAE FROM POPULATION OF GUJARAT: A DATABASE FOR SHOULDER ARTHROSCOPY. Int J Anat Res 2018;6(2.2):5191-5196. **DOI:** 10.16965/ijar.2018.151