

## POSITION OF MENTAL FORAMEN IN DRY HUMAN MANDIBLES AND ITS SIGNIFICANCE

Yogi Anupkumar Balakrishnan <sup>1</sup>, S. Vikram <sup>\*2</sup>, Chitra Prakash Rao <sup>3</sup>, SanjayKumar B revankar <sup>4</sup>.

<sup>1</sup> Assistant professor of Anatomy, Malankara Orthodox Syrian Church Medical College (MOSCMC), Kolenchery, Kerala, India.

<sup>\*2</sup> Associate Professor, Department of Anatomy, AJ Institute of Medical Sciences and Research Centre (AJIMS&RC), Mangalore, Karnataka, India.

<sup>3</sup> Professor and HOD, Department of Anatomy, AJ Institute of Medical Sciences and Research Centre (AJIMS&RC), Mangalore, Karnataka, India.

<sup>4</sup> Assistant Professor, Department of Anatomy, AJ Institute of Medical Sciences and Research Centre (AJIMS&RC), Mangalore, Karnataka, India.

### ABSTRACT

**Background:** The position of mental foramen is very important because it will be helpful to localize the important neurovascular bundle passing through. It is a landmark to facilitate surgical, local anaesthetic and other invasive procedures for dental surgeons performing peri-apical surgery in the mental region of mandible.

**Aims & Objective:** To study morphometric analysis of mental foramen in dry human mandibles.

**Materials and Methods:** 50 dried adult human mandibles with dentition and intact alveolar margin of unknown sex were used for this study. The morphometric measurements were recorded using Vernier callipers.

**Results:** The most commonly present position of the MF as related to the lower set of teeth was in line with the second premolar, Type 3 - 48 % cases on the right side and type 4 - 52% cases on the left side

**Conclusion:** The knowledge of the distances from surgically encountered anatomical landmarks in the present study provide valuable information to dental surgeons that will facilitate effective localization of the neurovascular bundle passing through mental foramen, thus avoiding complications from local anaesthetic, surgical and other invasive procedures. The study is also of forensic significance as the position of mental foramen also helps in determination of sex of an individual.

**KEY WORDS:** Mental Foramen, Human Mandible, Morphometric, Measurements.

**Address for Correspondence:** Dr. S. Vikram, Associate Professor, Department of Anatomy, AJ Institute of Medical Sciences and research centre (AJIMS&RC), Mangalore, Karnataka, India.

**E-Mail:** v1karade@gmail.com

Access this Article online	Journal Information
<b>Quick Response code</b>  DOI: 10.16965/ijar.2018.162	<b>International Journal of Anatomy and Research</b> ICV for 2016 90.30 ISSN (E) 2321-4287   ISSN (P) 2321-8967 <a href="https://www.ijmhr.org/ijar.htm">https://www.ijmhr.org/ijar.htm</a> DOI-Prefix: <a href="https://dx.doi.org/10.16965/ijar">https://dx.doi.org/10.16965/ijar</a> 
	Article Information
	Received: 23 Feb 2018 Peer Review: 23 Feb 2018 Revised: None
	Accepted: 05 Apr 2018 Published (O): 05 May 2018 Published (P): 05 May 2018

### INTRODUCTION

The mental foramen is located in the anterior aspect of the body of the mandible in relation to the molar and premolar teeth. Through the mental foramen the terminal branches of inferior alveolar nerve and artery namely mental

nerve and vessels pass. The mental foramen (MF), from which the mental nerve and vessels emerge, lies below either the interval between the premolar teeth, or below the second premolar tooth [1]. The mental foramen marks the termination of the mandibular canal in the

mandible.

At this point, the mandibular canal bifurcates and forms the mental and incisive canals [2]. The mental bundle passes through the mental foramen and supplies sensory innervation and blood supply to the soft tissues of the chin, lower lip and gingiva on the ipsilateral side of the mandible [3]. To anesthetise the anterior teeth, including the premolars and canines, it is possible to avoid giving inferior alveolar nerve block, by injecting anaesthetic agent adjacent to the mental foramen [4]. Although this is termed mental injection or mental nerve block, the aim of the injection is to affect the inferior alveolar and incisive nerves in that region [5]. Studying the position of mental foramen is very important because it will be helpful to localize the important maxillofacial neurovascular bundle passing through the mental foramen.

The study is also of forensic significance as the position of mental foramen also helps in determination of sex of an individual [6].

## MATERIALS AND METHODS

50 dried adult human mandibles with complete dentition and intact alveolar margin of unknown sex were used for this study. The morphometric measurements were recorded using Vernier callipers. The present study was conducted in a private medical college, in south india.

For measuring the parameters, a standard horizontal plane as defined by Marrant [6,7] was utilized which states that the mandible when placed on a horizontal surface, the lower border of the mandible comes into greatest contact when vertical pressure is applied to the second molar teeth. The findings were charted, analysed and compared with the findings of other studies in different geographical locations

**Method 1:** The position of the MF was recorded as lying in line with the long axis of a tooth or interdental space in one of the six relations [22].

Type 1:-Anterior to the first premolar

Type 2:-below the first premolar

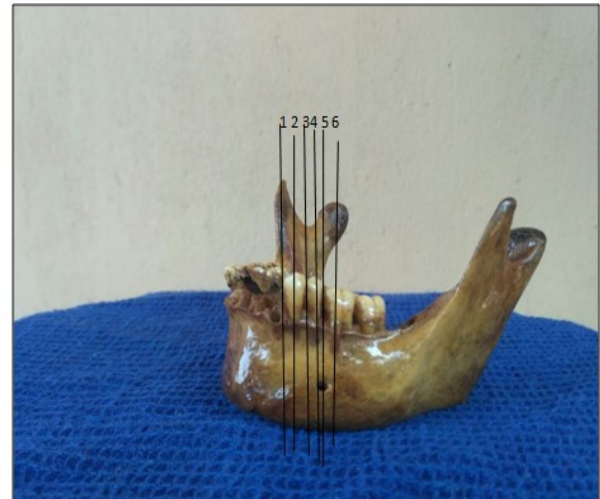
Type 3:-between the premolars

Type 4:-below the second premolar

Type 5:-posterior to the second premolar

Type 6:-below the first molar

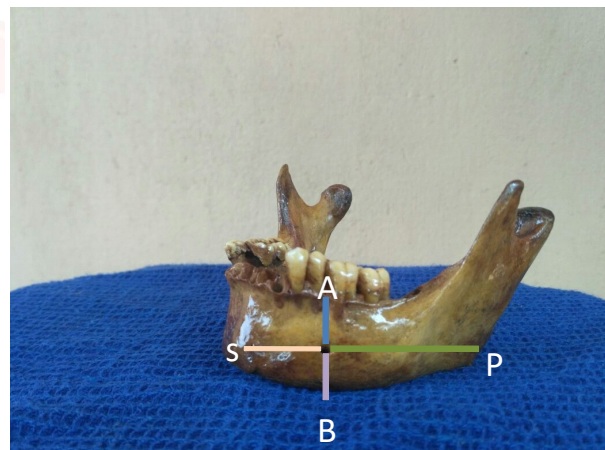
**Fig. 1:** Showing the relation of MF with the lower teeth.



**Method 2:** The Location of mental foramen is determined by using following parameters:

- i. Distance between symphysis menti (S) and anterior margin of mental foramen (MF)
- ii. Distance between posterior margin of MF and posterior border of ramus (PB)
- iii. Distance between alveolar crest (X) and superior margin of mental foramen (MF)
- iv. Distance between inferior margin of MF and lower border of the body of mandible

**Fig. 2:** Location of mental foramen, identified by using parameters

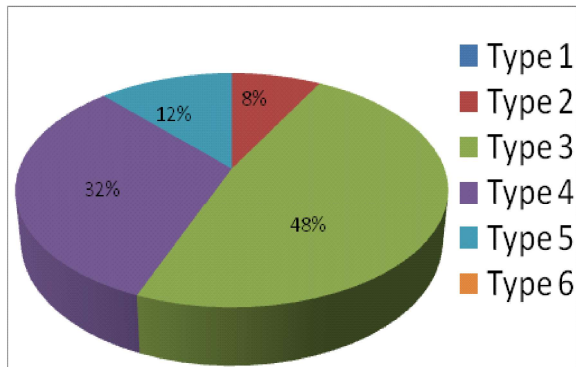


## RESULTS

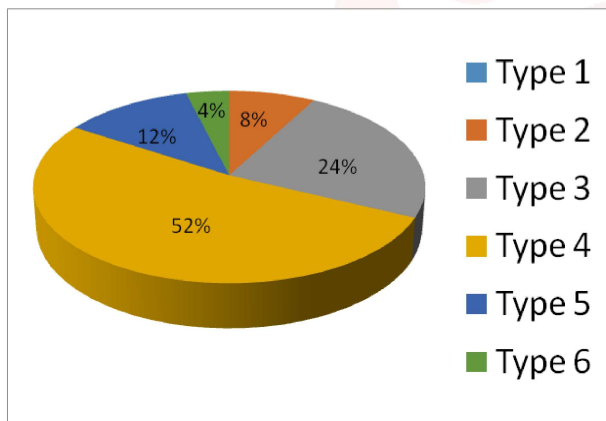
Our study indicated the situational variability of the Mental Foramen (MF). The mental foramen was present bilaterally in all the mandibles.

The most commonly present position of the MF as related to the lower set of teeth was in line with the second premolar, i.e. Type 3: 48 % cases on the right side and type 4: 52% cases on the left side

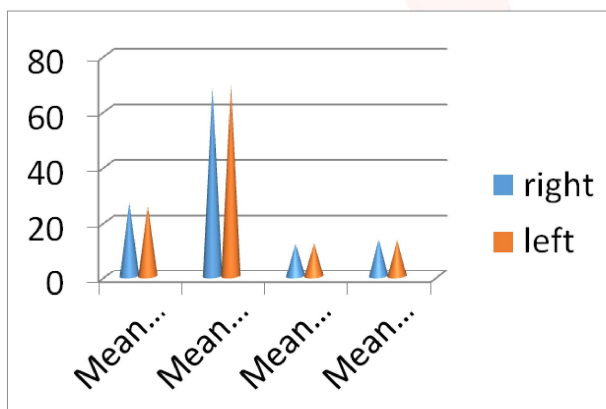
**Graph 1:** The various position of the MF recorded and it's been classified into six types based on whether the foramen is lying in line with the long axis of a tooth or interdental space on the right side.



**Graph 2:** The various position of the MF recorded and it's been classified into six types based on whether the foramen is lying in line with the long axis of a tooth or interdental space on the left side.



**Graph 3:** shows mean distance between mental foramen and other landmarks.



Referring to graph 1 and 2, the mean distance between symphysis mentii and anterior margin of MF was 26.28mm and 25.45 mm, on the right & left sides respectively.

Mean distance between posterior margin of MF and posterior border of ramus was 68.47. mm on the right side and 69.2 mm on the left side.

Mean distance between alveolar crest and superior margin of MF was 11.93 mm on right

side and 12.26 mm on the left side.

Mean distance between inferior margin of MF and lower border of the body of mandible was 13.52 mm on the right side and was 13.3 mm on the left side.

## DISCUSSION

In the present study, The most commonly present position of the MF as related to the lower set of teeth was in line with the second premolar, Type 3 - 48 % cases on the right side and type 4 -52% cases on the left side .The most common position irrespective of side is type 4.

In east india population, the most commonly seen position of the MF in relation to the lower teeth/interdental space was below the 2nd premolar (Type 4) in 67% cases, referring to Table No 2, this commonest position has been described in 52.94% cases in Sri Lankan cases [9], 45% cases in western India[8], 45% in Tanzanian studies[10], 64.3% in Koreans[12] and 69.2% in Malay populations[13].

Yesilyurt et al (2008)[5] in their study have quoted that the most common positions for the mental foramen were:

(i) Between the premolars (Type 3) in Negroid, British, Central Anatolian and North American white populations.

(ii) Below the second premolar tooth (Type 4) in Chinese, Kenyan Africans, Nigerians and Mongoloid populations;

(iii) Posterior to the second premolar (Type5) in Caucasians and Zimbabweans,

Haghanifar and Rokouei (2009) [17] in their radiological study of the MF, reported that the most common position of the MF was between the two premolars being 47.2%.

Another study from Turkey has shown that the most common position of the MF was between the two premolars, Type 3, (71.5% cases) [14].As regards the situation of the MF with respect to mandibular parameters (Table No 2), differences are seen amongst Western India[8], Turkish[5], and North Indian samples.

The review of the available literature shows that the MF shows racial and ethnic variations. Moreover the variations in the values indicate towards the variational mandibular dynamics of

**Table 1:** Position of the MF in Relation to Lower Teeth/ Interdental Space (Comparison with Other Studies).

Study	Location	Year	Type 1	Type 2	Type 3	Type 4	Type 5	Type 6
Present study	Southern india	2015	R 0 L 0	4(8%) 4(8%)	24(48%) 12(24%)	16 (32%) 26(52%)	6(12%) 6(12%)	0 2(4%)
Ajay (n=50)	Eastern India	2012	R 0 L 0		11 (21.6%) 10 (19.6%)	33 (64.7%) 34 (66.7%)	4 (7.8%) 5 (9.8%)	2 (3.9%) 1 (2%)
Siddiqui (n=93)	Western India	2010	R 1 (1.07%) L 1 (1.07%)	6 (6.45%) 8 (8.60%)	39 (41.93%) 33 (35.48%)	41 (44.08%) 43 (46.23%)	6 (6.45%) 8 (8.60%)	0 0
Ilayperuma et al (n=51)	Sri Lanka	2009	-	-	26.47%	52.94%	-	-
Yesilurt[5] (n=70)	Turkey	2008	R L	-	34.30% 25.70%		-	
Fabian (n=100)	Tanzania	2007	-	-	-	45%	35%	-
Kim et al (n=72)	Korea	2006	-	-	26.80%	64.30%	-	-
Ngeow(n=169)	Malaysia	2003	-	-	19.60%	69.20%	-	-
Gingor(n=361)	Turkey	2006	-	-	71.50%	22.40%	-	-

**Table 2:** Situation of MF with respect to mandibular parameters (Comparison with Other Studies).

Location year	Ajeyparmar n=50 Eastern India 2012	Siddiqui n=93 Western India 2010	Yesilurt (n=70) Turkey 2008	Singh et al (n=96) North India 1992	Present Study (n=50) South India 2015
Variable studied	Mean values	Mean values	Mean values	Mean values	Mean values
Distance between S and MF	R=23.3 L=22.5	R=18.8 L=19.6	R=19.18 L=19.37	23.6	R=26.28 L=25.45
Distance between MF and PB	R=61.3 L=62.5	R=48.8 L=47.9	R= 48.58 L= 48.27	76.2	R=68.47 L=69.22
Distance between X and MF	R=10.6 L=10.3	R=10.2 L=10	R= 10.5 L=10.64	15.3	R=11.93 L=12.26
Distance between MF and Y	R=10.7 L=10.7	R=9.9 L=10.1	R=9.44 L=9.46	14.88	R=13.52 L=13.3

the population under consideration. Many of the differences can also be attributed to the variability in the chewing habits of different populations, leading to differential development of the mandible.

Similar findings have been reported in western Indian mandibles [5]. The variability in the readings may be attributed to the chewing habits, age, tooth size and the attrition of the proximal surface.

**CONCLUSION**

The knowledge of the location of mental foramen in relation to teeth and from various anatomical landmarks in the present study provide valuable information to dental surgeons to localise the neurovascular bundle passing through mental foramen thus avoiding complications from local anaesthetic, surgical and

other invasive procedures. It is suggested radiographs, should be taken to locate the MF prior to surgery.

**ABBREVIATIONS**

- MF** – Mental foramen,
- S** - Symphysis menti ,
- P** - Posterior border of ramus of mandible
- B** – Base of mandible,
- A**- Alveolar margin of mandible

**Conflicts of Interests: None**

**REFERENCES**

- [1]. Standring S. Gray’s Anatomy. 39th ed. London: Elsevier Churchill Livingstone; 2005.
- [2]. Shankland WE 2nd. The position of mental foramen in Asian Indians. J Oral Implantol. 1994;20(2):118-23.

- [3]. Phillips JL, Weller RN, Kulild JC. The mental foramen: 1. Size, orientation and positional relationship to the mandibular second premolar. *J Endod* 1990 May;16(5):221-3.
- [4]. Rowe AHR. In: *Clinical Dentistry*. 3rd edi. Oxford: Blackwell Scientific Publications 1986. p. 372-83.
- [5]. Yesilyurt H, Aydinlioglu A, Kavakli A, Ekinci N, Eroglu C, Hacialiogullari M, et al. Local differences in the position of the mental foramen. *Folia Morphol* 2008;67(1):32-35.
- [6]. Akhilesh chandra, Anil singh, Archana agnihotri. Determination of sex by radiographic analysis of mental foramen in north indian population. *J Forensic Dent Sci*. 2013 Jan-Jun; 5(1): 52-55.
- [7]. Wang TM, Shih C, Liu JC, Kuo KJ. A clinical and anatomical study of the location of the mental foramen in adult Chinese mandibles. *Acta Anat (Basel)*. 1986;126(1):29-33.
- [8]. Siddiqui AU, Daimi SR, Mishra PP, Doshi SS, Date JY, Khurana G. Morphological and morphometric analysis of mental foramen utilizing various assessment parameters in dry human mandibles. *Int J Stud Res* 2011;1(1):19-22.
- [9]. Ilayperma I, Nanayakkara G, Palahepitiya N. Morphometric analysis of mental foramen in adult Srilankan mandibles. *Int J Morphol* 2009; 27(4):1019-24.
- [10]. Fabian FM. Position, shape and direction of opening of mental foramen in dry mandibles of Tanzanian adult black males. *Ital J Anat Embryol* 2007;112(3):169-77.
- [11]. Prabodha LBL, Nanayakkara BG. The position, dimensions and morphological variations of mental foramen in mandibles. *Galle Med J* 2006;11(1):13-5.
- [12]. Kim IS, Kim SG, Kim YK, Kim JD. Position of the mental foramen in a Korean population: A clinical and radiographic study. *Implant Dentistry* 2006;15(4):404-11.
- [13]. Ngeow WC, Yuzawati. The location of the mental foramen in a selected Malay population. *J Oral Sci* 2003;45(3):171-5.
- [14]. Gingor K, Ozturk M, Semiz M, Brooks SL. A radiographic study of location of mental foramen in a selected Turkish population on panoramic radiograph. *Coll Antropol* 2006;30(4):801-5.
- [15]. Apinhasmit W, Methathrathip D, Chompoopong S, Sangvichien S. Mental foramen in Thais: an anatomical variation related to gender and side. *Surg Radiol Anat* 2006;28(5):529-33.
- [16]. Singh SK, Gopinath K, Dhall U, Chhabra S. Variation in the position and number of mental foramen in mandibles of North Indian population. *J Anat Soc India* 1992;41(1):47-51.
- [17]. Haghanifar S, Rokouei M. Radiographic evaluation of the mental foramen in a selected Iranian population. *Indian J Dent Res* 2009;20(2):150-2.
- [18]. Al-Khateeb T, Hamasha AAH, Ababneh KT. Position of mental foramen in a northern regional Jordanian population. *Surg Radiol Anat* 2007;29(3):231-7.
- [19]. Neo J. The position of the mental foramen in Singaporean Malays and Indians. *Anesth Prog* 1989;36:276-8.
- [20]. Greenstein G, Tarnow D. The mental foramen and nerve: clinical and anatomical factors related to dental implant placement-a literature review. *J Periodontol* 2006;77(12):1933-43.
- [21]. Loh HS, Mongoloids features of the permanent mandibular second molar in Singaporean Chinese. *Aust Dent J*. 1991;36:442-4.
- [22]. Parmar A, Shah K, Patel B, Jadav J, Trivedi B, Kothari G. Morphological and morphometric analysis of mental foramen in dry human mandibles. *Int J Med Sci Public Health* 2013;2:640-644.

#### How to cite this article:

Yogi Anupkumar Balakrishnan, S. Vikram, Chitra Prakash Rao, SanjayKumar B revankar. POSITION OF MENTAL FORAMEN IN DRY HUMAN MANDIBLES AND ITS SIGNIFICANCE. *Int J Anat Res* 2018;6(2.2):5228-5232. DOI: 10.16965/ijar.2018.162