

Case Report

THE ORIGIN AND FORMATION OF GASTROSPLENIC TRUNK AND THE COMMON HEPATIC ARTERY: SURGICAL AND EMBRYOLOGICAL BASIS: A CASE REPORT

Ariyanachi K¹, Vishwajit Ravindra Deshmukh^{*2}, Nagaraj S³.

¹Senior Resident, Department of Anatomy, JIPMER, Karaikal, India.

^{*2} Assistant Professor, Department of Anatomy, JIPMER, Karaikal, India.

³ Assistant Professor, Department of Anatomy, JIPMER, Karaikal, India.

ABSTRACT

Coeliac artery forms the major blood supply for the structures derived from the foregut up to the major duodenal papillae. During the routine dissection classes for the undergraduates, a very uncommon variation in the origin of the coeliac trunk was observed. Instead, of the coeliac artery, two trunks were arising directly from the abdominal aorta at the level of T12-L1. The gastrosplenic trunk and the common hepatic artery were apart from each other. An aberrant left hepatic artery arose from the left gastric artery, entering into the porta hepatis to supply the left lobe of the liver. Lesser curvature of the stomach is solely supplied by the left gastric artery. Knowledge regarding such multiple variations in the abdominal region is utmost important for the anatomists, clinicians, a radiologist for performing angiographic studies and hepatic surgeons to avoid any damage to the aberrant artery, as it may result into the ischaemia and necrosis of the related part.

KEYWORDS: Coeliac artery, aberrant, Liver, Hepatic artery, Surgery.

Address for Correspondence: Dr. Vishwajit Ravindra Deshmukh, Assistant Professor, Department of Anatomy, JIPMER, Karaikal, India. **E-Mail:** drvishwajitdeshmukh@gmail.com

Access this Article online	Journal Information
Quick Response code  DOI: 10.16965/ijar.2018.175	International Journal of Anatomy and Research ICV for 2016 90.30 ISSN (E) 2321-4287 ISSN (P) 2321-8967 https://www.ijmhr.org/ijar.htm DOI-Prefix: https://dx.doi.org/10.16965/ijar 
	Article Information
	Received: 03 Mar 2018 Peer Review: 06 Mar 2018 Revised: None
	Accepted: 05 Apr 2018 Published (O): 05 May 2018 Published (P): 05 May 2018

INTRODUCTION

Arterial anatomy of the coeliac trunk (CT) is of great value in pancreatic and hepatobiliary surgeries as a direct visualisation of the related field is limited during surgeries. The coeliac trunk, also known as the coeliac artery/coeliac axis and is the first ventral branch of the abdominal aorta. It arises at the level of the intervertebral disc between T12 and L1 vertebra. The coeliac trunk and its branches supply the spleen, lower end of oesophagus, stomach, liver and proximal part of the duodenum [1]. Normally the CT gives of three branches – splenic artery, left gastric artery and common

hepatic artery. The first description of this classical branching pattern was proposed by Haller in 1756 as Tripus Halleri [2]. Anatomical variations in the origin and branching pattern of CT have been frequently reported during routine cadaveric dissection, diagnostic angiography and abdominal surgeries.

A thorough knowledge of coeliac axis and its variations regarding its branching pattern is essential to accomplish successful and uncomplicated surgical and radiological procedures of the upper abdomen. With the advent of newer interventional and treatment options for hepatic malignancies, laparoscopic cholecystectomy

and partial hepatectomy for liver transplantation, a detailed knowledge of hepatic vasculature and its variations is utmost significant. In 1955, Michel described his classification scheme for hepatic artery branching pattern by dissecting 200 cadavers [3]. Song et al. published the largest series of work on coeliac axis hepatic artery variations in 5002 patients [4]. In this case report, we present the differential branching pattern of coeliac trunk accompanied by an aberrant left hepatic artery.

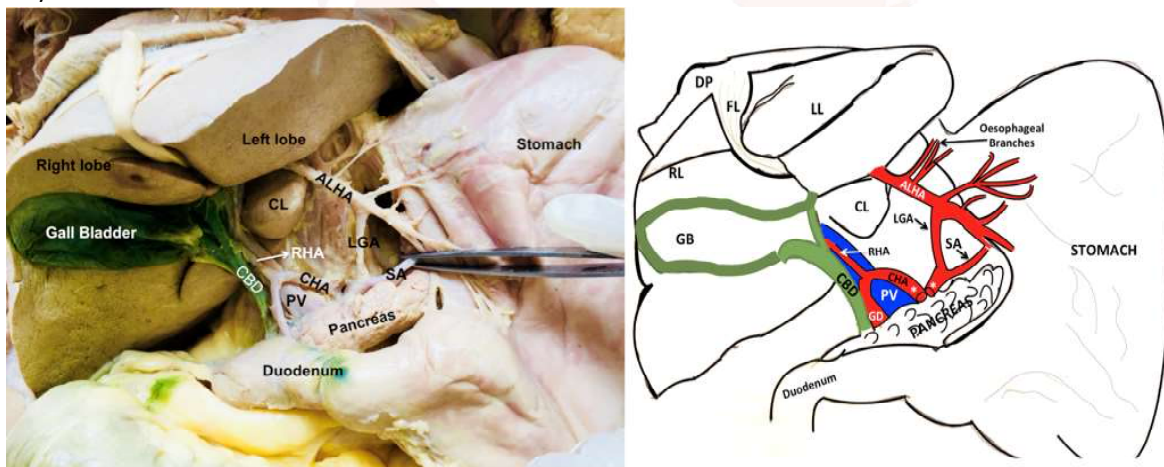
CASE REPORT

In the routine dissection classes for the first year undergraduate students in anatomy department, JIPMER, Karaikal, the rare uncommon variations was observed for the emergence and branching pattern of the coeliac trunk and the hepatic vasculature, in a 55 years old female cadaver. The cadaver was donated to the department and the cause of death was unknown. There were no signs of abdominal injury, surgical trauma or

scars in the anterior abdominal wall. Following variations were observed. (Figure. 1)

1. Origin of the common hepatic artery and gastrosplenic trunk directly from the abdominal aorta at the level of T12-L1, instead of coeliac trunk. These two trunks were separated from each other by 3mm distance.
2. The gastrosplenic trunk further divides into left gastric artery and splenic artery. No variations were observed in the course and supply of these vessels.
3. The common hepatic artery divides into larger gastroduodenal trunk, and smaller right hepatic artery which enters the right lobe of the liver through the porta hepatis. Cystic artery arose from the right hepatic artery.
4. Right gastric artery was absent.
5. The left gastric artery gives off the aberrant left hepatic artery which supplies the left lobe of the liver and also branches to the lower 1/3rd part of the oesophagus.

Fig. 1: Photograph and schematic diagram showing the origin of the gastrosplenic trunk and the common hepatic artery directly from the aorta. Aberrant left hepatic artery (ALHA) can be identified taking origin from the left gastric artery.



CL: Caudate lobe, SA: Splenic artery, CHA: Common hepatic artery, PV: Portal vein, RHA: Right hepatic artery, CBD: Common bile duct, RL: Right lobe, LL: Left lobe, GD: Gastroduodenal artery, GB: Gall bladder, FL: Falciform ligament, DP: Diaphragm.

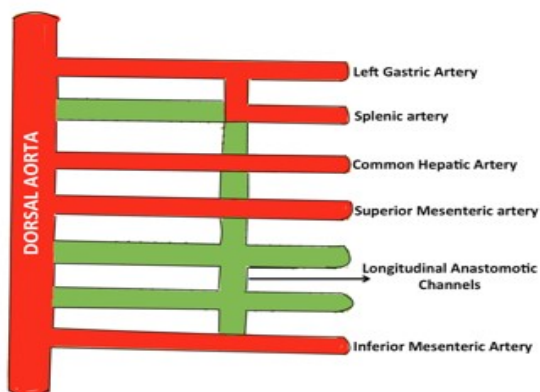


Fig. 2: The photograph representing the schematic diagram for the developmental basis of the gastrosplenic trunk and the common hepatic artery as well as superior and inferior mesenteric arteries. (RED: Represents the persistence of the vessels and GREEN: These vessels will disappear)

DISCUSSION

The variations in the branching pattern of the coeliac trunk have been widely reported in the literature. These vascular variations were usually asymptomatic but the knowledge is essential in patients undergoing abdominal angiography, prior to procedures like transcatheter therapy and chemoembolization of pancreatic and hepatic tumours [5].

Any abnormal embryological development of ventral splanchnic arteries could result in significant variation in the branching pattern of coeliac trunk. The data obtained from the past research showed that about 15% of the population display significant variation in the typical branching pattern of CT [6].

Since 20th century, many authors have studied these variations and proposed their own classification. The first classification was proposed by Lipschutz in 1917[7]. His classification was simple but he failed to mention the possibility of absent coeliac trunk and coelomesenteric trunk. Adachi, in 1928, gave an extensive description of the coeliac axis and made small schematic drawings of 6 types [8]. Michel's classification was meticulous as it included every possible branching pattern but the extensive number of types made it unsuitable for practical purpose [9]. Eaton proposed a logical and geometrical branching pattern of coeliac axis [10].

In the present case, the coeliac trunk bifurcates at the origin into the left gastric artery and splenic artery (gastrosplenic trunk). Common hepatic artery arises directly from the abdominal aorta. Lipschutz has mentioned this branching pattern as type IV in his classification and he reported its incidence to be 4% in the 83 cadavers dissected by him. Eaton has mentioned the same as type I and Michel has classified it as type V in their classification patterns [7,9]. They have reported the incidence of this branching pattern to be 4.9% and 5.5% respectively.

In a study done by Song et al., using Spiral Computed Tomography and Digital Subtraction Angiography, 15 types of coeliac trunk branching pattern has been proposed [4]. Arrazola et al. proposed a much simpler classification. They suggested a complete coeliac trunk where all

three branches (left gastric artery, common hepatic artery, splenic artery) participate in the trunk and an incomplete coeliac trunk where either one of these three branches does not participate in the trunk and arises directly from the abdominal aorta. They also suggested an absence coeliac trunk and coeliacomesenteric trunk [11].

With the regard to the incomplete CT, the most frequent pattern was found to be gastrosplenic trunk (incidence 5%), that is followed by hepatosplenic trunk(4.5%) [11]. The existence of hepatogastric trunk is usually rare. However, in the same study, angiographic results showed the hepatosplenic trunk to be common. Eaton and Michel also found the most common incomplete CT to be gastrosplenic trunk whereas Lipschutz and Song found it to be the hepatosplenic trunk [4,7,9,10].

In the present case, we have also observed an unusual variation of absent right gastric artery. Anatomical variations in the arterial supply of liver have been reported to occur in 25% – 50% of the population [12]. The relevance of hepatic vascular anatomy is essential not only for harvesting and re-anastomosis of orthotopic liver transplants but also to avoid vessel injury during laparoscopic cholecystectomy and vascular radiological procedures. The most commonly encountered variations are the aberrant hepatic arteries. Typical/normal hepatic artery arises from CT and divides into three main branches. – right hepatic, middle hepatic, left hepatic arteries supplying right lobe, quadrate lobe and left lobe of the liver respectively. The aberrant hepatic artery is defined as a artery to take origin from the different source . It could be accessory or replaced hepatic artery. The term accessory hepatic artery is used when the normal right / left hepatic artery is present and there is an additional artery from another source. The replaced hepatic artery is the case where the normal coeliac right / left hepatic artery is missing and the replacing vessel coming from another source supplying right / left lobe. This replacing vessel is termed as replaced right / left hepatic artery [3].

Studies have reported the incidence of the replaced right hepatic artery to be 3.5% - 21% and accessory right hepatic artery to be

1% - 8%. These aberrant right hepatic artery may arise from a superior mesenteric artery, left gastric artery, gastroduodenal trunk or may arise independently of the left hepatic from the coeliac trunk. The incidence of accessory left hepatic artery and replaced left hepatic artery has been reported to be 4.5% - 32% and 4.15% - 5% respectively [3,13,14,15].

In the present case, the left gastric artery gives off the aberrant left hepatic artery which supplies the left lobe of the liver. Left gastric artery emerging from the coeliac trunk and providing left hepatic artery is assigned type II category in Michel's and Hiatt classification.[16,17] In a study done by Farghadani et al., in 607 patients, CT images revealed that 6.6% presented with replaced left hepatic artery originating from the left gastric artery [18]. The prevalence of the same variation was 5.2% in a study done Ceccoet al., and Winston reported the incidence of this variation to be 8% [19,20]. It is crucial to have a sound knowledge of an aberrant left hepatic artery during liver transplantation, gastric surgery and bariatric surgery as it lies in hepatogastric ligament and is prone for laceration which could lead to fatal ischaemic necrosis of left lobe of the liver [3,21]. Presence of aberrant left hepatic artery also complicates the transarterial chemoembolization procedure for patients with hepatocellular carcinoma [22].

Developmental Correlation: (Figure. 2) With the folding of embryo, the yolk sac sinks and the right and left vitelline plexus coalesce to form number of major arteries that anastomose with the ventral surface of dorsal aorta. After the fusion at the end of 4th week, ventral branches fuses and form a series of several unpaired segmental arteries termed as ventral splanchnic arteries that are connected by ventral longitudinal anastomosing channels. With the formation of this longitudinal channels, numerous ventral splanchnic branches disappear and eventually only three trunks persist as coeliac trunk, superior mesenteric artery and inferior mesenteric artery. Tandler states that 11th & 12th segmental roots disappear; 10th & 13th root remain connected as ventral anastomosis.^[23] Common hepatic artery, splenic artery & left gastric artery originate from this ventral

anastomosis & they are usually separated from the 13th root (future superior mesenteric artery) below their last end. If the separation takes place at a higher level, the branches may be displaced to superior mesenteric artery. If 10th or 13th root disappear, coeliacomesenteric trunk is formed. Any variation in this longitudinal anastomosis could result in various branching pattern of coeliac trunk.

CONCLUSION

The variations of the coeliac trunk and hepatic artery have considerable importance in liver transplants, hepatobiliary manipulations, laparoscopic surgeries, abdominal surgeries, radiological abdominal interventions and penetrating injuries of the abdomen. Though these variations are asymptomatic, they could possibly interfere with the diagnosis and surgical outcome. Hence a thorough understanding of variant anatomy could minimise the pre-operative and post-operative surgical complications and they could facilitate a better radiological interpretation.

Conflicts of Interests: None

REFERENCES

- [1]. Pitman AG, Moss D, Stringer MD. Posterior abdominal wall and retroperitoneum. In: Standing S, editor. Gray's Anatomy: The Anatomical Basis of Clinical Practice. 40th Ed. Edinburgh: Elsevier Churchill Livingstone: 2011. P.1088
- [2]. Haller A. Icon Anatomical in quibus aliquae partes corporis humani delineatae proponuntur et arteriarum potissimum historia continetur. Gottingen: Vandenhoeck; 1756:VIII 270.
- [3]. Michel NA. Blood supply and anatomy of the upper abdominal organs, with a descriptive atlas. Philadelphia, Pa: Lippincott; Observation on the blood supply of liver and gall bladder: 1955. p.64-9
- [4]. Song SY, Chung JW, Yin YH, Jae HJ, Kim HC, Jeon UB, et al. Coeliac axis and common hepatic artery variations in 5002 patients: Systemic analysis with siral CT and DSA. Radiology. 2010; 255:278-88.
- [5]. D'Souza AS, Vijayalakshmi, Hemalatha, Pugazhandhi, Mamatha H. Anatomical variations in the branches of coeliac trunk. J Clin Diagn Res. 2012; 6(3): 333-5.
- [6]. Bergman RA, Afifi AK, Miyauchi R. Illustrated encyclopaedia of human anatomic variation [Internet]. Anatomy Atlases; c 1995-2015 [cited 2015 March 1]. Available from: <http://www.anatomyatlases.org/AnatomicVariants/AnatomyHP.shtml>
- [7]. Lipshutz B. A composite study of coeliac axis artery. Ann Surg. 1917; 65: 159-69

- [8]. Adachi B. Das Arteriensystem der Japaner. Verlag der Kaiserlich – Japanischen Universitat zu Kyoto. 1928; 2:18 – 71
- [9]. Michels NA. The hepatic, cystic and retro duodenal arteries and their relations to the biliary duct. Ann. Surg. 1951; 133:503 – 24
- [10]. Eaton PB. The coeliac axis. Anat Rec. 1917; 13: 369-74.
- [11]. Arrazola J, Sanudo J, Valderrama JM, Simon C, Ahumada N, Marco-clement I, et al. Anatomical variations of the coeliac trunk: cadaveric and radiological study. Surg Radiol Anat. 2016; 38(4): 501-10.
- [12]. Covey AM, Brody LA, Maluccio MA, Getrajdman GI, Brown Kt. Variant hepatic arterial anatomy revisited: Digital subtraction angiography performed in 600 patients. Radiology. 2002;224:542-7.
- [13]. Kavitha KB. A study of variant hepatic arterial anatomy and its relevance in current surgical practice. Int J Anat Res. 2015;3(1):947-53.
- [14]. Flint ER. Abnormalities of the right hepatic, cystic, and gastroduodenal arteries, and of the bile-ducts. Br J Surg. 1922-23; 10:509-19
- [15]. Suzuki T, Nakayasu A, Kawabe k, Takeda H, Honjo I. Surgical significance of anatomic variations of hepatic artery. Am J Surg. 1971;122:505-12.
- [16]. Michel NA. Newer anatomy of the liver and its variant blood supply and collateral circulation. Am J Surg. 1994; 220: 50-2.
- [17]. Hiatt JR, Gabbay J, Busuttil RW. Surgical anatomy of the hepatic arteries in 1000 cases. Ann Surg. 1994; 220: 50-2.
- [18]. Farghadani M, Momeni M, Hekmatnia A, Momeni F, Baradaran Mahdevi MM. Anatomical variation of coeliac axis, superior mesenteric artery and hepatic artery: Evaluation with multidetector computed tomography angiography. J Res Med Sci. 2016; 21: 129.
- [19]. De Cecco CN, Ferrari R, Rengo M, Paolantonio P, Vecchietti F, Laghi A. Anatomic variations of the hepatic arteries in 250 patient studied with 64 – row CT angiography. Eur Radiol. 2009; 19: 2765-70.
- [20]. Winston CB, Lee NA, Jarnagin WR, Teitcher J, De Matteo RP, Fong Y, et al. CT angiography for delineation of coeliac and superior mesenteric artery variants in patients undergoing hepatobiliary and pancreatic surgery. Am J Roentgenol. 2007;189: 113-9.
- [21]. Abid B, Douard R, Chevallier JM, Delmas V. Left hepatic artery: Anatomical variations and clinical implications. Morphologie. 2008; 92:154-61.
- [22]. Chaduhari ML, Maheria PB, Nerpagar S, Meneze VR. Origin of left hepatic artery from the left gastric artery. Natl J Integr Res Med. 2013; 4(2): 173-4.
- [23]. Tandler J. Uber die Varietaten der Arteia coeliaca and deren Ent wicklung. Anat Hefte. 1904; 25: 473-500.

How to cite this article:

Ariyanachi K, Vishwajit Ravindra Deshmukh, Nagaraj S. THE ORIGIN AND FORMATION OF GASTROSPLENIC TRUNK AND THE COMMON HEPATIC ARTERY: SURGICAL AND EMBRYOLOGICAL BASIS: A CASE REPORT. Int J Anat Res 2018;6(2.2):5256-5260. DOI: 10.16965/ijar.2018.175