International Journal of Anatomy and Research,
Int J Anat Res 2018, Vol 6(2.3):5351-53. ISSN 2321-4287
DOI: https://dx.doi.org/10.16965/ijar.2018.205

Case Report

AN INFERIOR MESENTERIC ARTERY ARISING FROM THE LEFT COMMON ILIAC ARTERY

Eleni Panagouli [1], Gregory Tsoucalas *[2], Aliki Fiska [2], Dionysios Venieratos [1], Panagiotis Skandalakis [2].

[1] Department of Anatomy, Medical School, National and Kapodistrian University of Athens, Greece.

[2] Department of Anatomy, Democritus University of Thrace, Alexandroupolis, Greece.

ABSTRACT

Although anatomical variations in abdominal vascular branching are a common phenomenon, alternations in IMA are rather rare. We report a variation found during a dissection of an embalmed male cadaver of Caucasian Hellenic origin, where we observed an IMA having as a point of origin the left common iliac artery, 0.4 cm after the AA bifurcation in the level between L3 and L4 vertebra. Ignorance of this variant may cause serious implications during vascular and abdominal surgery.

KEY WORDS: Inferior Mesenteric Artery, Common Iliac Artery, Aorta Bifurcation, Anatomic Variation.

Address for Correspondence: Gregory Tsoucalas, Ierolohiton 155, Agioi Anargyroi 38334, Volos, Greece. Cell phone 00306945298205, **E-Mail:** gregorytsoucalas@yahoo.gr

Access this Article online	Journal Information
Quick Response code	**International Journal of Anatomy and Research** ICV for 2016 90.30 ISSN (E) 2321-4287 | ISSN (P) 2321-8967 **https://www.ijmhr.org/ijar.htm** **DOI-Prefix:** https://dx.doi.org/10.16965/ijar
DOI: 10.16965/ijar.2018.205	**Article Information** Received: 27 Mar 2018 Accepted: 08 May 2018 Peer Review: 28 Mar 2018 Published (O): 05 Jun2018 Revised: None Published (P): 05 Jun 2018

INTRODUCTION

The inferior mesenteric artery (IMA) arises from the anterior or left anteriolateral aspect of the abdominal aorta (AA) behind the third- part of the duodenum, about 3-4 cm above the bifurcation of the AA. It is the third and smallest of the three anterior branches of the AA and arises at the level of the third lumbar vertebra (with an incidence of about 68%). Initially it descends anteriorly to the AA and then passes to the left as it continues inferiorly. Its branches include the left colic artery, several sigmoid arteries, and the superior rectal artery [1-2].

Although IMA's branching pattern shows important variability, the variations considering its point of origin seem to be rather rare [3].

Generally, IMA is very stable, arising directly from the AA, with a widely varied length from 10.1 to 82.2 mm [4]. Savchenko and Shendrik seem to be the first to distinguish 10 variations of the branching pattern of the IMA in 1976 and to give detailed information of its vascular relationships [5].

Defective fusion of the vitelline arteries during the embryonic stage may result in a series of anatomical variations. Their knowledge is essential during abdominal and vascular surgery [6]. We report a case of an infrequent point of origin of the IMA, an anatomical alternation rarely reported in the literature.

CASE REPORT

The reported anatomical variation was discovered in a male Caucasian cadaver of Hellenic origin during routine educational dissection at at the Anatomy Department of the Medical School of the University of Athens. The cadaver derived from body donation with informed

consent, written and signed (with signature authentication) by the donator himself. The "Ethics Committee" of the institution approved the publication of the case.

The AA and its branches were carefully dissected. The stomach and the pancreas were also dissected and mobilized to expose the celiac trunk, the superior mesenteric artery and their branches. Then the transverse colon and mesocolon were retracted in order to discover IMA and the rest of the aortic body until its bifurcation to the left and right common iliac arteries (CIA). The IMA was not observed as branch of the AA, but it originated from the left CIA, 0.4 cm after the aortic bifurcation, at the level of the middle third of the forth lumbar vertebra. Expect the unusual point of origin, the rest of branching pattern of the IMA was the expected one and no other vascular variations were detected.

Fig. 1: Inferior mesenteric artery (IMA) originating from the left common iliac artery (LCIA). RCIA: right common iliac artery.

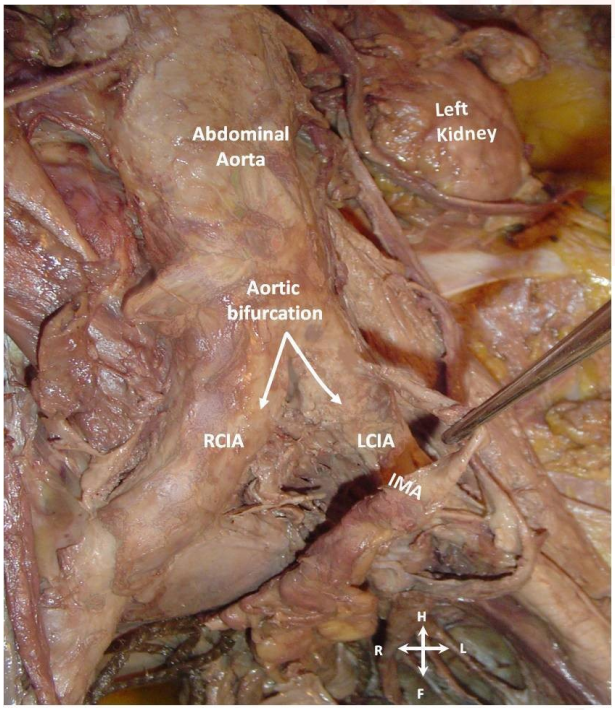

DISCUSSION

Although the arterial pattern of the gastrointestinal tract has many variations and a plethora of IMA anatomic variations in its branching pattern and length have been reported, there are only a few case reports considering variations of its point of origin. Normally, IMA's arising point is located 42.1 ± 7.7 mm above the level of AA bifurcation, about 64-70% at the area of the 3rd lumbar vertebra [7]. According to the available literature, IMA is spotted to arise from the superior mesenteric artery (SMA) with an incidence less than 0,1% [10-14] or as a branch of a celiac-bimesenteric trunk in one case [15,16], is noted to be totally absent, replaced by an artery arising from branches of the inferior pancreaticoduodenal and middle colic arteries in one case [8], is discovered having the same trunk with a right accessory renal artery [14], and detected [17].

In the present case we report an IMA with a point of origin above the aortic bifurcation and specifically from the LIA. To our knowledge, there are only other two such cases mention to the available literature, the one was firstly observed in 1736 by Petsche, (as cited by Gwin and Skilton 1966) [13, 18] and the second in 2012 by Nassar et al. [9].

For the diagnosis of intestinal angina and ischemic colitis is essential for the radiologist to understand all possible variant of the IMA. The same apply for a surgeon in the case of intestinal and abdominal operations (malignancies, compressions, occlusive disease, right hemicolectomy, resection of the transverse colon, left hemicolectomy, sigmoidectomy, en bloc resection of the head of the pancreas and the superior mesenteric vessels, colonic interposition in severe oesophagus carcinomas) [19-21], in vascular reconstruction (anastomosing blood vessels, IMA re-implantation) [22] and in safely when performing laparoscopic surgery in the left-side colon and rectum [23]. It is essential thus, for all interventional practitioners to comprehend IMA anatomical branching pattern, as well as its variations [24].

CONCLUSION

Alternations in normal vascular patterns always cause trouble among clinicians. An unexpected origin of the IMA artery in a level below the aortic bifurcation, arising from the left CIA is such a case. Few are the cases reporting a similar anatomic variant, a fact demanding awareness for the unusual in order for complications to be avoided.

Conflicts of Interests: None

REFERENCES

[1]. Richard Drake, A. Wayne Vogl, Adam W. M. Mitchell. Gray's Anatomy for Students. Philadelphia: Elsevier Health Sciences; 2009.

[2]. Singh V. Textbook of Anatomy Abdomen and Lower Limb. Faridabad: Elsevier Health Sciences; 2014.

[3]. Natsis K, Paraskevas G, Panagouli E, Tsaraklis A, Lolis E, Piagkou M, Venieratos D. A morphometric study of multiple renal arteries in Greek population and a systematic review. Rom J Morphol Embryol 2014;55(3 Suppl):1111-1122

[4]. Murono K, Kawai K, Kazama S, Ishihara S, Yamaguchi H, Sunami E, Kitayama J, Watanabe T. Anatomy of the inferior mesenteric artery evaluated using 3-dimensional CT angiography. Dis Colon Rectum 2015;58(2):214-219.

[5]. Savchenko AP, Shendrik IG. X-ray anatomy of the inferior mesenteric artery according to findings of intravital angiography. Arkh Anat Gistol Embriol 1976;70(6):26-30.

[6]. Prakash, Mokhasi V, Rajini T, Shashirekha M. The abdominal aorta and its branches: anatomical variations and clinical implications. Folia Morphol (Warsz) 2011;70(4):282-286.

[7]. Ke J, Cai J, Wen X, Wu X, He Z, Zou Y, Qiu J, He X, He X, Lian L, Wu X, Zhou Z, Lan P. Anatomic variations of inferior mesenteric artery and left colic artery evaluated by 3-dimensional CT angiography: Insights into rectal cancer surgery - A retrospective observational study. Int J Surg 2017;41:106-111.

[8]. Kim DI, Han SH. A rare branching pattern of hindgut: absence of inferior mesenteric artery. Surg Radiol Anat 2017;39(7):803-806.

[9]. Nassar L, Atweh LA, Jurjus A, Al Kutoubi A. Unusual arterial pattern of the gastrointestinal tract: inferior mesenteric artery arising from the iliac artery and corkscrew external iliac. Vasc Endovascular Surg 2012;46(5):418-421.

[10]. Yi SQ, Li J, Terayama H, Naito M, Iimura A, Itoh M. A rare case of inferior mesenteric artery arising from the superior mesenteric artery, with a review of the literature. Surg Radiol Anat 2008;30(2):159-165.

[11]. Osawa T, Feng XY, Sasaki N, Nagato S, Matsumoto Y, Onodera M, Nara E, Fujimura A, Nozaka Y. Rare case of the inferior mesenteric artery and the common hepatic artery arising from the superior mesenteric artery. Clin Anat 2004;17(6):518-521.

[12]. Yoo SJ, Ku MJ, Cho SS, Yoon SP. A Case of the Inferior Mesenteric Artery Arising from the Superior Mesenteric Artery in a Korean Woman. J Korean Med Sci 2011;26:1382-1385.

[13]. Gwyn DG, Skilton IS. A Rare Variation of the Inferior Mesenteric Artery in Man. Anat Rec 1966;156(2):235-237.

[14]. Osawa T, Feng XY, Sasaki N, Nagato S, Matsumoto Y, Onodera M, Nara E, Fujimura A, Nozaka Y. Rare case of the inferior mesenteric artery and the common hepatic artery arising from the superior mesenteric artery. Clin Anat 2004;17(6):518-521.

[15]. Adachi B. Das Fehlen der A. mesenterica inferior bei einem Japaner. Anat Anz 1930;69:431-433.

[16]. Nonent M, Larroche P, Forlodou P, Senecail B. Celiac-bimesenteric trunk: anatomic and radiologic description—case report. Radiology 2001;220(2): 489-491.

[17]. Loukas M, Aparicio S, Beck A, Calderon R, Kennedy M. Rare case of right accessory renal artery originating as a common trunk with the inferiormesenteric artery: a case report. Clin Anat. 2005;18(7):530-535.

[18]. Petsche JZ. Sylloge anatomicarum selectarum observationum. Halae Magdeburgicae, litteris JC Hendelii; 1736.

[19]. Chaikof EL, Cambria RP. Atlas of Vascular Surgery and Endovascular Therapy: Anatomy and Technique. Philadelphia: Elsevier Health Sciences; 2014.

[20]. Hansdak R, Pakhiddey R, Thakur A, Mehta V, Rath G. Anatomical Description and Clinical Relevance of a Rare Variation in the Mesenteric Arterial Arcade Pattern. Journal of Clinical and Diagnostic Research 2015;9(8):AD01-AD02.

[21]. Yi SQ, Li J, Terayama H, Naito M, Iimura A, Itoh M. A rare case of inferior mesenteric artery arising from the superior mesenteric artery, with a review of the review of the literature. Surg Radiol Anat 2008;30(2):159-165.

[22]. Prakash, Mokhasi V, Rajini T, Shashirekha M. The abdominal aorta and its branches: anatomical variations and clinical implications. Folia Morphol (Warsz) 2011;70(4):282-286.

[23]. Murono K, Kawai K, Kazama S, Ishihara S, Yamaguchi H, Sunami E, Kitayama J, Watanabe T. Anatomy of the inferior mesenteric artery evaluated using 3-dimensional CT angiography. Dis Colon Rectum 2015;58(2):214-219.

[24]. Tsoucalas G. Anatomy: An Essential Course for Future Surgeons. J Universal Surg 2018;6(1):8.

How to cite this article:

Eleni Panagouli, Gregory Tsoucalas, Aliki Fiska, Dionysios Venieratos, Panagiotis Skandalakis. AN INFERIOR MESENTERIC ARTERY ARISING FROM THE LEFT COMMON ILIAC ARTERY. Int J Anat Res 2018;6(2.3):5351-5353. **DOI:** 10.16965/ijar.2018.205