

## A STUDY ON ANATOMICAL VARIATIONS IN THE FORMATION OF BRACHIAL PLEXUS AND ITS BRANCHES

Jyothi Jathavath <sup>1</sup>, A Vijaya Lakshmi <sup>\*2</sup>.

<sup>1</sup> Assistant professor in Anatomy, RIMS, Ongole, Andhra Pradesh, India.

<sup>\*2</sup> Assistant professor in Anatomy, Siddhartha Medical College, Vijayawada, Andhra Pradesh, India.

### ABSTRACT

**Background:** The variable course of the nerves may be the cause of many neuralgic pains of the superior extremity. The knowledge of percentage of variations may help the surgeons in treating the cases of trauma & entrapment neuropathies.

**Materials and Methods:** The present study in 70 upper limbs of 35 human cadavers over a period 1 year at the department of Anatomy at Siddhartha medical college and surrounding medical colleges around Vijayawada. The detailed examination of the following nerves that is musculocutaneous, median, ulnar, radial and axillary nerves was done in the arm and following variations were observed.

**Results:** Communication between musculocutaneous and median nerves in eleven limbs. Musculocutaneous nerve was absent in our limbs. Median nerve supplied muscles of front of arm where musculocutaneous nerve was absent in one limb. Musculocutaneous nerve did not pierce coracobrachialis muscle in seven limbs. The Communication between radial and ulnar nerve in one limb.

**Conclusion:** Lesions of communicating nerve may give rise to pattern of weakness that may impose difficulty in diagnosis. So it is important to be aware of the variations that are observed and discussed in our study. Knowledge of these variations is important for neurologists, orthopaedicians and traumatologists as these may give rise to variable clinical picture depending upon the variations present.

**KEY WORDS:** Musculocutaneous nerve, Median nerve, Coracobrachialis, Cadaveric study.

**Address for Correspondence:** Dr. A Vijaya Lakshmi. MD, Assistant professor in Anatomy, Siddhartha Medical College, Vijayawada, Andhra Pradesh, India. **E-Mail:** vldevi.athota@gmail.com

Access this Article online	Journal Information
<b>Quick Response code</b>  DOI: 10.16965/ijar.2018.209	<b>International Journal of Anatomy and Research</b> ICV for 2016 90.30 ISSN (E) 2321-4287   ISSN (P) 2321-8967 <a href="https://www.ijmhr.org/ijar.htm">https://www.ijmhr.org/ijar.htm</a> DOI-Prefix: <a href="https://dx.doi.org/10.16965/ijar">https://dx.doi.org/10.16965/ijar</a> 
	<b>Article Information</b> Received: 30 Mar 2018 Peer Review: 01 Apr 2018 Revised: None Accepted: 08 May 2018 Published (O): 05 Jun 2018 Published (P): 05 Jun 2018

### INTRODUCTION

Anatomical knowledge of brachial plexus, like nerve origin, course, branches and distribution as well as communication is of vital importance especially while dealing with trauma around shoulder girdle [1]. The relation of a particular nerve to surrounding structures is also important because any relation to major vessels have the risk of damage by trauma or disease, relation to a bone or joint where they are more prone to injury. In the brachial plexus the intricate

manner in which anastomotic connections are formed to give rise to nerves of extensive cutaneous and motor supply with succession of separations and conjugations accounts for the numerous variations in some instances striking. Variations in formation and branching pattern of the brachial plexus are common and have been reported by several investigators. Variations in connection between musculocutaneous nerve and median nerve have some significance in diagnostic neurophysiology [2]. Though many

studies have taken place involving major nerves of brachial plexus, they are still incomplete. This promoted us to carry the present work of studying the major nerves of upper limb in the arm.

The word variation means the different way of presenting of a structure in the body usually which does not produce any functional disturbances. During routine dissections of superior extremity given to the 1<sup>st</sup> year M.B.B.S., students, many variable communications were observed which created some inquisitiveness to study the details of formation of brachial plexus & variations in the cords and their branches. Upper limb is one of the most active parts of the body which receive both sensory and motor supply from brachial plexus. The nerves which give sensation and control the upper limb are all connected through the brachial plexus. Many scientists worked on this topic, most of them found variations at the level of formation of brachial plexus pre fixed, & post fixed Kerr [3], Hollenshed [4], Hasan et.al. [5]. Their clinical variations were also discussed at length in the text books of Anatomy & Clinical Anatomy.

Moore & Dally [6] said, the arrangement of terminal branches remain unchanged, according to Williams et. Al [7], the terminal branches of lateral & medial cords do not communicate in the arm [8]. In the present study it was observed that the Median nerve passes deep to the brachial artery in two cases. This inspired to take up this as a project work and add the knowledge of observations to the subject. Moreover the variable course of the nerves may be the cause of many neuralgic pains of the superior extremity. The knowledge of percentage of variations may help the surgeons in treating the cases of trauma & entrapment neuropathies.

**MATERIALS AND METHODS**

Our study was based on the dissection of the 60 upper limbs which belonged to 70 upper limbs of 35 human cadavers of either sex and over a period from July-2010 to August-2012 at the department of Anatomy at Siddhartha medical college and surrounding medical colleges around Vijayawada. In each cadaver, the axilla, pectoral region and arms of both the upper limbs were dissected and observed with naked eye


branches of cords of brachial plexus were selected because of their common involvement in disease, trauma and injuries and also lions share in nerve supply pertaining to the upper limb. These include Musculocutaneous nerve, Median nerve, Ulnar nerve, Radial nerve and Axillary nerve. All the variations in the formation of trunks and cords of brachial plexus and distribution of the branches were noted and the photographs were taken with the help of digital camera.

**Observations:** After meticulous dissection and naked eye examination of 60 upper limb Specimens following observations were made with respect to individual nerves. The Musculocutaneous nerve was present in all upper limbs except in four Limbs where it was absent. In the upper limbs where it was present it took origin from lateral cord of brachial plexus opposite to lower border of pectoralis minor. It pierced the coracobrachialis muscle in 52 limbs and descended laterally between biceps brachii and brachialis muscles.


SL No.	Particulars	Normal	Variation
1	Existence	Present – 56 [93.33%]	absent in 4 cases
2	Origin	Lateral root of LC-60 [100%]	High origin [5 cm] in 2 cases
3	Relation to III rd part of axillary artery.	Lateral – 60 [100%]	–
4	Piercing of coracobrachialis muscle .	54 cases [90% ]	2 cases
5	Communication with MN a) Before piercing coracobrachialis muscle. b) After piercing coracobrachialis muscle.		4 cases

The mean distance of origin of musculocutaneous nerve is 2.11 cm. High origin of Musculocutaneous nerve was found in two cases i.e. First case 3.9cm, and in second case 3.8cm. The distance from tip of coracoid process to point of entry into coracobrachialis was between 7.4 to 9.4cms, average length is 8.4cm, in right arms and 7.2 to 9.4cm average length is 8.3cm in left arms. Abnormal communication was seen from musculocutaneous to median nerve in 3 limbs just above middle of the arm and in 3 limbs the abnormal branch arose after piercing coracobrachialis muscle. In 3 cases the Musculocutaneous nerve not piercing coracobrachialis muscle but it gives the twig to the coracobrachialis muscle and it communicate with the median nerve.

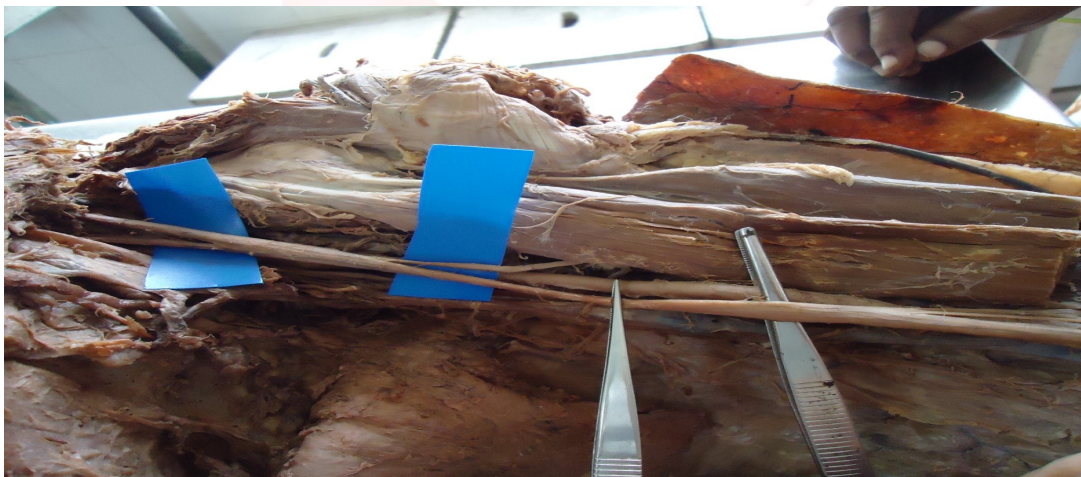
**Fig. 1:** Absent of Musculocutaneous nerve case – 1.



**Fig. 2:** Absent of Musculocutaneous Nerve case -2.



**Fig. 3:** Absent of Musculocutaneous Nerve case – 3.



**Fig. 4:** Absent of Musculocutaneous nerve case – 4.



**Fig. 5:** Musculocutaneous nerve communicate with Median nerve.



In one limb, a branch arose from lateral cord travelled for some distance along with median nerve and continued below as musculocutaneous nerve. In 3 limbs, the abnormal branch arose from musculocutaneous nerve after piercing coracobrachialis muscle at a distance of 13.2 to 15.2cm [average 14.2cms] from tip of coracoid process. In four limbs, the musculocutaneous nerve was absent. The muscles of front of arm that is coracobrachialis, biceps brachii and brachialis were supplied by median nerve from its lateral aspect. After supplying muscles of front of arm the nerve pierced the deep fascia at the level of elbow lateral to tendon of biceps and continued as lateral cutaneous nerve of forearm.

## DISCUSSION

The brachial plexus is formed with the anterior rami of C5, C6, C7, C8 and T1. It terminates with the formation of musculocutaneous, median, ulnar, axillary and radial nerves. The intermediate portions are displayed in sets of threes: three trunks are formed, followed by three divisions, then three cords. Each trunk gives rise to two divisions and each cord gives rise to two branches. The lateral cord divides into the musculocutaneous nerve and lateral root of the median nerve. The medial cord divides into medial root of median nerve and ulnar nerve. The posterior cord divides into axillary and radial nerve. The anatomy of brachial plexus can be confusing, especially because of frequent variations in length and caliber of each of its components [9].

In the present study of 60 upper limbs musculocutaneous nerve arose from lateral cord of brachial plexus. It was absent in four limbs

[6.66%]. This was already reported by several workers. Prasad Rao PV and Chaudhary SC observed two cases of absent musculocutaneous nerve in 24 upper limbs. This was found to be absent in 8% of cases. Median nerve took over the area of supply of the musculocutaneous nerve by giving both muscular and sensory branches [10]. Hayashi M has stated that very occasionally the musculocutaneous nerve is not found and its various branches arise from median nerve [11]. The absence of musculocutaneous nerve was noted by Le Minor et al. [12], Nakata et.al [13], Sud M et.al. [14] and Gumusburn [15]. After the formation of musculocutaneous nerve, it descended down to pierce coracobrachialis in 54 limbs [90%]. The distance from tip of coracoid process to point of entry into coracobrachialis varied from 7.4 to 9.4cms, average length is 8.4 cms, Study done by Joshi et al have found that point of entry of musculocutaneous nerve into coracobrachialis is variable which ranges from 1.5 to 9.5cms [16].

In 7 limbs [11.9%] of our study the musculocutaneous nerve passed between biceps brachii and brachialis muscles without piercing coracobrachialis. Hollinshed [17] quoting Rao et al has described that 9.3% musculocutaneous nerves did not pierce coracobrachialis muscle. The musculocutaneous nerve ordinarily enters coracobrachialis muscle from its medial aspect approximately 5cm distal to tip of coracoid process. It may run behind the coracobrachialis muscle or adhere for some distance to the median nerve or pass behind the biceps or may be accompanied by fibres from the median nerve as it transits coracobrachialis, less frequently the reverse occurs [10]. Anastomosis between musculocutaneous nerve and median nerve is by far the most common and frequent of the variations that are observed among the branches of brachial plexus. Le Minor JM [18] classified communications between musculocutaneous nerve and median nerve into 5 types.

Type I - No communication between musculocutaneous nerve and median nerve

Type II - Fibres of medial root of median nerve pass through musculocutaneous nerve and join the median nerve in the middle of the arm.

Type III - The lateral root fibres of median nerve pass along the musculocutaneous nerve and

after some distance, leave it to form lateral root of median nerve.

Type IV - The musculocutaneous nerve fibres join lateral root of median nerve and after some distance the musculocutaneous nerve arise from median nerve.

Type V- The musculocutaneous nerve is absent and entire fibres of musculocutaneous nerve pass through the lateral root and fibres to the muscles supplied by musculocutaneous nerve branch out directly from median nerve.

Choi et al [19] broadly classified the communications between musculocutaneous nerve and median nerve into three patterns.

Patterns I : Two nerves are fused.

Pattern II : One communicating branch between musculocutaneous nerve and median nerve.

Pattern III :Two communicating branches between musculocutaneous nerve and median nerve

Venieratos and Anagnostopoulou [20] classified the communication between two nerves into 3 types.

Type I - Communication between musculocutaneous nerve and median nerve is proximal to the entrance of musculocutaneous nerve into the coracobrachialis.

Type II - Communication is distal to the muscle.

Type III - The nerve or communicating branch did not pierce the muscle.

The variation in our study in relation to above classification include

Type I - 13.6%,

Type II – 5.1%,

Type III – 11.9%

A study done by Atkan et al showed connections between musculocutaneous nerve and median nerve were found in five arms. The connections were not bilateral in any cadaver. They left the musculocutaneous nerve  $0.95 \pm 0.42$ cms from the formation of this nerve. The point of entering the median nerve was  $10.25 \pm 2.32$ cms from the formation of median nerve. The mean length of this interconnection was  $5.50 \pm 2.50$ cms [21].

In our study abnormal communicating branch measured 1.5 to 10.3cms [average 5.3cms].

Communication between the musculocutaneous and median nerves in the arm is considered as remnant from the pylogenetic or comparative point of view. Kosugi et al. reported that there was one trunk equivalent to the median nerve in the thoracic limb of lower vertebrates [amphibians, reptiles, birds] [22]. In man, the forelimb muscles develop from the mesenchyme of the paraxial mesoderm during the fifth week of intrauterine life. The axons of spinal nerves grow distally to reach the mesenchyme.

The peripheral processes of the sensory and motor neurons grow in the mesenchyme, in different directions<sup>46</sup>. As the guidance of the developing axons is regulated by the expression of chemoattractants and chemorepulsants in a highly co-ordinated site specific fashion, significant variations in the nerve patterns may be a result of altered signalling between mesenchymal cells and neuronal growth cones or circulatory factors at the time of fusion of brachial plexus [23].

After supplying muscles of front of the arm, it continued below as lateral cutaneous nerve of forearm after piercing the deep fascia lateral to the tendon of biceps brachii.

**Median Nerve:** This nerve arose in the axilla by the union of medial root from medial cord and lateral root from lateral cord of brachial plexus. In our study, median nerve was present in all the 60 limbs. No variation was seen as far as the origin was concerned.

The combination from first thoracic nerve to the formation of median nerve may be missing. The site of union between the lateral and medial branches is quite variable and has been as far down as the elbow. The two branches may enclose the axillary vein as well as the axillary artery. In our study the site of union between two roots varied from 4.0 to 15.2cm from tip of coracoid process. The median nerve may pass either in front or behind the axillary artery. In the present study the nerve passed anterior in 56 limbs [93.3%], posterior in 2 limbs [3.3%] and medial in 2 limbs [3.3%]. In a study done by Pandey et al. on 172 cadavers, in 8 cadavers the median nerve was formed medial to the artery and travelled as such. The nerve usually passed lateral to brachial artery and crossed it from lateral to medial side near the insertion of

coracobrachialis muscle. In our study crossing of brachial artery was seen in 55 limbs [91.6%] and no crossing in 5 limbs [8.3%]. Many authors have reported abnormal communications between median and other nerves. Thomson J observed 4% communication between median nerve and ulnar nerve and 3% between medial root of median nerve and ulnar nerve [24].

In our study the median nerve received abnormal communicating branch from the musculocutaneous nerve in 11 limbs [18.3%]. In our study, in one limb where musculocutaneous nerve was absent, median nerve supplied muscles of front of arm. It entered the forearm by passing between two heads of pronator teres without giving any muscular branches in the arm.

**Ulnar Nerve:** This nerve arose from medial cord of brachial plexus. Variation in the origin was described by many workers. In our study in all the 60 limbs the nerve arose from medial cord of brachial plexus. The ulnar nerve was lying medial to third part of axillary artery in all the 60 upper limbs. No variation was observed in this regard. It ran distally through the axilla between axillary artery and vein and was lying medial to brachial artery as far as midarm in all the limbs. In one limb of our study, the nerve received an abnormal communicating branch from radial nerve. This variation is not well documented from previous investigators. In the middle of the arm the nerve pierced the medial intermuscular septa. It descended to the forearm by passing posterior to medial epicondyle of humerus.

**Radial Nerve:** Radial nerve is the continuation of posterior cord of brachial plexus. It was present in all the 60 limbs. No variation was observed with respect to its origin. Atkan Z et al [21] reported a case in which radial nerve arose from the union of posterior divisions of inferior trunk and middle trunk in the left upper extremity. In our study the nerve lied posterior to III part of axillary artery in all the limbs. In one limb it gave an abnormal communicating branch to ulnar nerve. This variation is not observed by previous workers. The nerve then descended behind the brachial artery and entered the spiral groove by passing through lower triangular space. On reaching the lateral side of humerus it pierced the lateral intermuscular septum and comes to lie in front of lateral

epicondyle of humerus in all the 60 limbs.

**Axillary Nerve:** This nerve arose from posterior cord of brachial plexus. It was present in all the 60 limbs of our study. In all the limbs it lied posterior to axillary artery and anterior to subscapularis muscle. The nerve along with posterior circumflex travelled in quadrangular space. The axillary nerve divided into two branches – anterior and posterior. The anterior branch supplied anterior part of deltoid and posterior branch supplied posterior part of deltoid and teres minor in all the limbs of our study. Bergman et al [25] described origin of nerve to teres major muscle from axillary nerve instead of lower subscapular nerve. No variation with respect to origin, course and branching pattern was observed in our study.

## CONCLUSION

Nervous system is very much essential for the survival of an individual. Thorough anatomic knowledge of the nerves is essential for assessing the functional loss and planned reconstructive surgeries. The brachial plexus lesions may occur following trauma, compression of nerves, shoulder dislocation, intraoperative nerve damages, and traumatic delivery in infants and malposition of the patient during general anaesthesia. Variations of brachial plexus apparently are not rare. Lesions of communicating nerve may give rise to pattern of weakness that may impose difficulty in diagnosis. So it is important to be aware of the variations that are observed and discussed in our study. Knowledge of these variations is important for neurologists, orthopaedicians and traumatologists as these may give rise to variable clinical picture depending upon the variations present.

**Conflicts of Interests: None**

## REFERENCES

- [1]. Fazan VPS, Amadeu AS, Caleffi AL, Rodrigues Filho OA. Brachial plexus variations in its formation and main branches. *Acta Cir Bras.* 2003;18:5.
- [2]. Babu PB, Roy AP, Bangera H. Communication between musculocutaneous and median nerves: a case report. *Int J Res Med Sci* 2014;2:1211-3.
- [3]. Kerr A.T. The brachial plexus of nerves in man, the variations in its formation and branches. *American Journal of Anatomy.* 1918;23:285-395.

- [4]. Hollinshead, W. H. 1958. Anatomy for surgeons In: General survey of the upper limb. Vol. 3 - The Back and Limbs. New York: A Hoeber Harper Book. p 225-245.
- [5]. Hasan, M., Narayan, D. A single cord human brachial plexus Journal of the Anatomical Society of India.1964;13:103-4.
- [6]. Moore K.L., Dalley A.F. 1999: Upper limb. In: Clinically Oriented Anatomy. 4th Ed. Philadelphia: Lippincott, Williams and Wilkins. p 714-715.
- [7]. Williams P.L.; Bannister L.H.; Berry M.M.; Collins P.; Dyson M.; Dussek, J.E. et al. 1995: Nervous system. In: Gray's Anatomy. 38th Ed. Edinburgh: Churchill Livingstone. p 1266-72.
- [8]. Gupta M, Goyal N, Harjeet. Anomalous communications in the branches of brachial plexus. J. Anat. Soc. India. 2005;54(1):22-5.
- [9]. Gopal K, Anurag, Singh O. Anatomical variations of brachial plexus: anomalous branching pattern. Int J Res Med Sci. 2016;4:3376- 80.
- [10]. Prasada Rao PV, Chaudhary SC. Absence of musculocutaneous nerve: two case reports. Clin Anat. 2001;14(1):31-5.
- [11]. Hayashi M, Shionoya K, Hayashi S, Hatayama N, Kawata S, Qu N, et.al. A novel classification of musculocutaneous nerve variations: The relationship between the communicating branch and transposed innervation of the brachial flexors to the median nerve. Ann Anat. 2017;209:45-50.
- [12]. Le Minor JM. A rare variation of the median and musculocutaneous nerves in man. Arch Anat Histol Embryol. 1990;73:33-42.
- [13]. Nakatani T, Mizukami S, Tanaka S. Three cases of the musculocutaneous nerve not perforating the coracobrachialis muscle. Kaibogaku Zasshi. 1997;72(3):191-4.
- [14]. Sud M, Sharma A. Absence of musculocutaneous nerve and the innervation of coracobrachialis, biceps brachii and brachialis from the median nerve. J Anat Soc India 2000;49(2):176-7.
- [15]. Gumusburun E; Adiguzel E. A variation of the brachial plexus characterized by the absence of the musculocutaneous nerve: a case report. Surg Radiol Anat. 2000;22(1):63-5.
- [16]. Joshi S.D., Joshi S.S., Athavale S.A. Hitch-Hiking Fibres Of Lateral Cord Of Brachial Plexus In Search Of Their Destination. J. Anat. Soc. India.2008;57(1):26-9.
- [17]. Hollinshead W H. 1982.The back and limbs: knee, leg, ankle and foot. In: Anatomy for surgeons. vol rd 3, 3 Ed. London : Harper and Row publishers, pp 797.
- [18]. Le Minor JM. A rare variant of the median and musculocutaneous nerve in man. Archives of Anatomy, Histology and Embryology. 1992; 73:33–42.
- [19]. Choi D.; Rodriguez-Niedenfuhr M.; Vazquez T.; Parkin I., Sanudo J. R. Patterns of connections between the musculocutaneous and median nerves in the axilla and arm. Clinical Anatomy.2002;15:11-7.
- [20]. Venieratos, D. and Anagnostopoulou, S.Classification of communications between the musculocutaneous and median nerves. Clinical Anatomy. 1998;11:327-31.
- [21]. Aktan Z, Oztunk L, Bilge O, Ozer M, Pinar Y. A cadaveric study of the anatomical variations of the brachial plexus nerves in the axillary region and arm. Turk J Med Sci. 2001;2:147–150.
- [22]. Kosugi K, S. Shibata, H. Yamashita. Supernumerary head of Biceps brachii and branching pattern of the musculocutaneous nerve in Japanese. Surge Radiol Anat. 1992;14:175-85.
- [23]. Caton A, Hacker A, Naeem A, Livet J, Maina F, Blatt F, et al. The branchial arches and HGF are growth-promoting and chemoattractant for cranial motor axons. Development. 2000;127(8):1751-66.
- [24]. Pandey SK, Shukla VK. Anatomical variations of the cords of brachial plexus and the median nerve. Clin Anat. 2007;2(2):150–156.
- [25]. Bergman RA, Thompson SA, Afifi AK, Saadeh FA. Compendium of human anatomic variation: catalogue, atlas, and world literature. Baltimore, Munich: Urban and Schwarzenberg. 1988:139- 43.

#### How to cite this article:

Jyothi Jatthavath, A Vijaya Lakshmi. A STUDY ON ANATOMICAL VARIATIONS IN THE FORMATION OF BRACHIAL PLEXUS AND ITS BRANCHES. Int J Anat Res 2018;6(2.3):5364-5370. DOI: 10.16965/ijar.2018.209