

STUDY OF WORMIAN BONES IN ADULT DRY SKULLS OF HUMAN CADAVER

Upendhar Reddy ¹. M. Venkateshwar Reddy ².

¹Tutor, Department Of Anatomy, S.V.S.M.C, Mahbubnagar, Telangana, India.

² Associate Professor, Department Of Anatomy, S.V.S.M.C, Mahbubnagar, Telangana, India.

ABSTRACT

Introduction: Wormian bones are islands of small bones found at the sutures and fontanelles of the skull. Commonly appears in the lambdoid suture. This study reporting the incidence, location and morphology of Wormian bones as it may give the false impression as fractures and lead to confusion to the radiologists, surgeons and traumatologists to deal during surgeries.

Materials and Methods: The study comprises the 100 human adult skulls. Measuring tape, Sliding calipers, sutural thread and scale were used for measuring the length of the suture, incidence, types, morphology and topography of sutural bones were observed and compared with the studies done by previous authors. The bones were obtained from the Department of Anatomy, Sri Venkata Sai Medical College Mahbubnagar, Telangana, India.

Results: Wormian bones were found in Lambdoid suture (28%), Lambda (12%), Parietomastoid suture (0%), Coronal Suture (0%), Asterion (8%), Sagittal suture (12%), Occipitomastoid suture (0%), Parietosquamous (0%) and Pterion (8%). Three different shapes of WBs was witnessed; Quadrangular (4%), Irregular (36%), Triangular (8%).

Discussion: the knowledge of wormian bones is important to radiologists, orthopedicians and traumatologists as it can imitate fractures and lead to confusion and eventually differential diagnosis.

KEY WORDS: Wormian bones, sutures, fractures, skull.

Address for Correspondence: Mr. Upendhar Reddy, Tutor, Department Of Anatomy, S.V.S.M.C, Mahbubnagar, Telangana, India. **E-Mail:** u.reddy2008@gmail.com

Access this Article online	Journal Information
Quick Response code  DOI: 10.16965/ijar.2018.298	International Journal of Anatomy and Research ICV for 2016 90.30 ISSN (E) 2321-4287 ISSN (P) 2321-8967 https://www.ijmhr.org/ijar.htm DOI-Prefix: https://dx.doi.org/10.16965/ijar 
	Article Information
	Received: 22 Jun 2018 Peer Review: 22 Jun 2018 Revised: None
	Accepted: 31 Jul 2018 Published (O): 05 Sep 2018 Published (P): 05 Sep 2018

INTRODUCTION

The Inca bone was common in the skull of Incas (South American Indians) and is still present in their Andean descendants (Standring et al, 2008)[1]. Wormian bones are found in both sexes in similar percentages as well as in both sides of the skull, being predominantly symmetrical (Jeanty et al, 2000) [1].

Wormian bones are irregular bones that appear along with regular centres of ossification of cranium. The first account of the sutural bones

was made by Paracelsus. However, they were named 'Wormian bones' after Olaus Wormian who was a Professor of Anatomy at Copenhagen and also a Danish Physician & Antiquary, described them in a letter to his colleague Thomas Bartholin, who later termed these sutural bones as Wormian bones [2].

These asymmetrical bones are also called as sutural bones as they usually occur along the sutures. They are also given the name Supernumerary bones or ossicles. Wormian bones occur

most frequently on the lambdoid suture [3].

They can also be present in anatomical landmarks on the skull like bregma, pterion, asterion or lambda. Sutural bones are inherited as autosomal dominant traits. Wormian bones are more prevalent in adults than in fetuses. When present in children, they attribute for some diseases and play a role in the primary diagnosis of congenital brittle bone disease called Osteogenesis Imperfecta [2].

A fourfold increased incidence of sutural bones are seen in mentally retarded group than the remaining population [4]. It is said that the number of wormian bones increases as the capacity of the skull increases and this increase in WBs is not associated with the cause of the enlargement of skull. Hence these Wormian bones are formed as an adaptation to enlargement of the cranium [5].

This study aims at reporting the incidence, location and morphology of Wormian bones as it can imitate fractures and lead to confusion to the radiologists and eventually differential diagnosis and hence it is important to surgeons and traumatologists to deal during emergencies.

MATERIALS AND METHODS

The present study was conducted in the Department of Anatomy, S.V.S.M.C, Mahbubnagar in 100 fully ossified adult skulls of unknown sex and age. A skull which exhibited no wormian bones is taken as control and the length of sagittal, coronal and lambdoid sutures were noted.

Table 1: Showing Different Shapes & Percentage Of WBS.

Shape of WBS	No of Skulls	Percentage
Quadrangular	4	8.33
Irregular	8	16.66
Triangular	36	75

All the skulls showing Wormian bones were examined and the following parameters were taken into consideration:

- Incidence of Wormian bones
- Sites of Wormian bones found in the present study
- different shapes of the Wormian bones
- types of edges of the Wormian bones
- Length of coronal, sagittal and lambdoid suture.

The data obtained was compared with the other studies and analysed and photos were taken.

RESULTS

The measurements taken in the control skull is as follows:

Sagittal suture 14 CM

Coronal suture 24 CM

Lambdoid suture 18 CM

In the present study, the length of the sagittal suture in all the skulls showing Wormian bones were a minimum of 10 cms to a maximum of 16cms. The length of the coronal suture was a minimum of 18 cms to a maximum of 26cms. The length of lambdoid suture was a minimum of 16 cms to a maximum of 26cms.

Incidence of wormian bones: Out of 100 skulls, 48 skulls exhibited WBs of various types, sizes and structure. Sites of WBs found in the present study

Table 2: Showing Location And Number Of Skulls Exhibiting WBS.

Sites	No of skulls
Lambdoid Suture	32
Lambda	12
Asterion	8
Sagittal Suture	12
Pterion	4

The most common location of WBs in the present study in lambdoid suture. It was found unilaterally in 20 skulls and bilaterally in 12 skulls. Totally, 32 skulls out of 100 examined skulls exhibited WBs in lambdoid suture [Fig1]. The second most common situation of WBs was in Lambda [Fig 2], where it was found in 12 skulls. The least common sites of WBs were situated in the pterion where it was found in 4 skulls.

Shape of wormian bones: Three different shapes of WBs were found; quadrangular, triangular & irregularly shaped WBs. Out of that, irregular type [Fig 5] was the most common and it was found in 36 skulls, the second most common type was the triangular shaped WBs [Fig 5] where it was found in 8 skulls and the least common type was the quadrangular shaped WBs [Fig 5] which was found in 4 skulls.

Edges Of The Wormian Bones: The first types of WBs are with irregular edges [Fig 7] where it

is wavy, but not compact. Two types of edges were exhibited by the WBs. The second type of WBs are with Serpigenous edges [Fig 6] when they exhibit compactly wavy pattern. Highest number was WBs with irregular edges where it was found in 33 skulls out of 100 skulls and it was followed by WBs showing Serpigenous edges in 12 skulls.

Table 3: Showing Types Of Edges & Percentage Of WBS Found.

Edges	No Of Skulls	Percentage
Irregular	33	33%
Serpigenous	12	12%

Fig. 1: Showing multiple Wormian bones at Lambdoid suture.




Fig. 2: Showing Wormian bone at Lambda.




Fig. 3: Showing Wormian bone at Occipitomastoid suture.

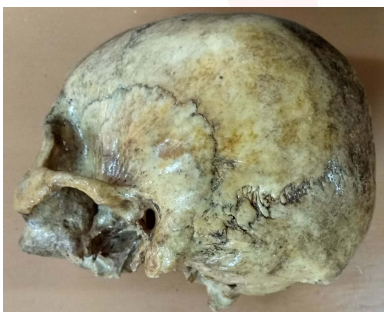

Fig. 4: Showing wormian bones at Asterion.

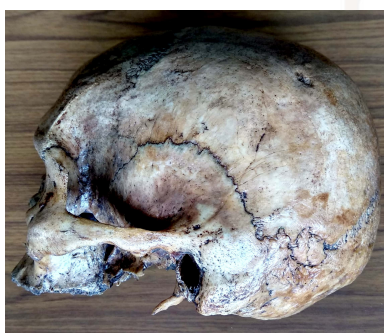

Fig. 5: Showing Different Shapes Of Wormian Bones.

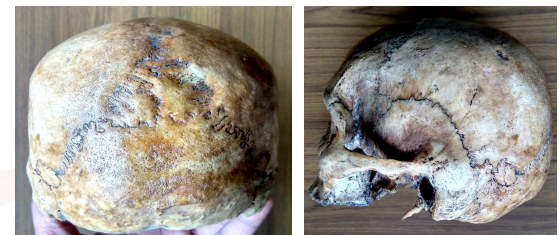
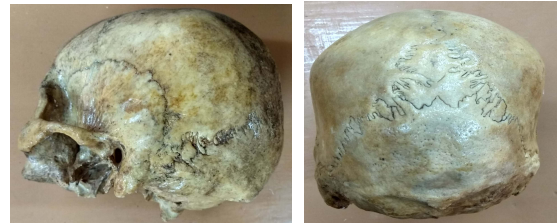
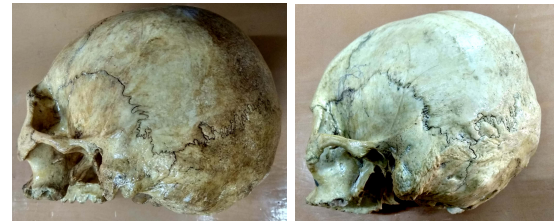Fig. 6: Showing sutures with Serpigenous edges

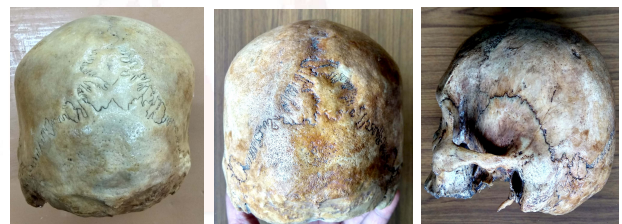
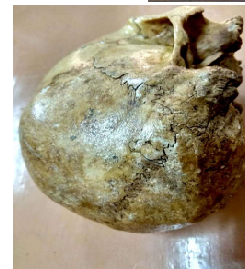
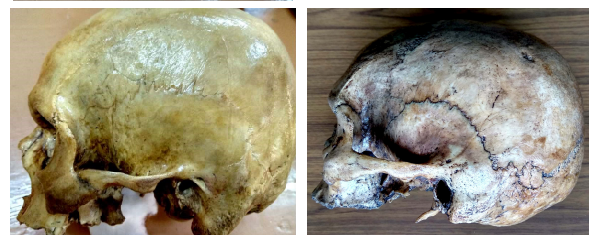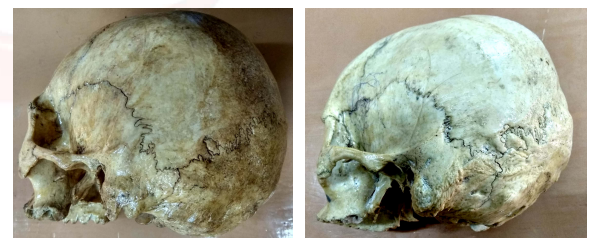Fig. 7: Showing sutures with Irregular edges



DISCUSSION

Mammals descend from primitive reptiles. In this evolution process, skull bones of mammals

undergo numerous changes. WBs are present in some carnivore mammals like dogs and cats. The cranial capacity is indirectly measured by measuring the sutural length. In the present study, there was no significant increase in the length of the sutures compared to the control. Presence of WBs and change in the sutural length are not associated with significant distortion of the skull.

Incidence of Sutural Bones: In the present study, sutural bones were found in 48 skulls out of 100 skulls examined. WBs are more frequently seen in Chinese population compared to western population due to their traditional supine infant sleep position causing brachycephalic deformations in their crania[9]. Some authors also found WBs in 80.3% Chinese skulls [5].

Table 4: Shows the different percentages of incidence of Wormian bones in various studies.

Marti et al [2]	53%
Murlimanju et al [10]	73.10%
Walulkar Sanjay [11]	34.22%
A.A Khan [12]	28%
SibelCirpan et al [15]	59.30%
Present Study	48%

Wormian Bones at Different Sutures: In the present study, highest number of WBs was found in the lambdoid suture (32%). Second highest number of WBs was found in Lambda (12%). and the least number of WBs were found in pterion (4%), Asterion (8%) and sagittal suture (12%). None were found in Bregma.

Lambdoid suture [Fig 1] – WBs in the present study was witnessed most frequently here than any other suture. Murlimanju et al [10] found the highest in lambdoid suture (56.4%) and WalulkarSanjay et al[11]noticed the same in 74.2% of their specimens. Literature mentions that WBs are most commonly found in lambdoid suture. But, in a study by A.A Khan[12], out of 25 skulls they were found in none. WBs are most common in lambdoid suture because of their rugged nature compared to all the other sutures[13].

Lambda [Fig 2] – The second most common site of WBs in the present study is in lambda (12%) and it correlates with Walulkar Sanjay's[11] study where the second most common site is also lambda (10.38%). Whereas the second most

common site of WBs in some studies was asterion [8,10]. If WBs are large in size and found near the lambda, they can be called as Inca bone or true interparietalbone[14].

Asterion [Fig 4] – In the present study, they were found in 8%. This data correlates with some studies[11, 8, 10] who found WBs in the region of Asterion in 9.09%, 6% &17.9% skulls respectively. A study by RajaniSingh[16] to check the incidence of sutural bones in asterion using 55 skulls led to finding WBs in asterion which were of two types, irregular and approximately triangular shapes. The present study also exhibited these types. It was also stated in this study that WBs in the asterion can lead to complications during cranial surgery via this point.

Shape of Wormian bones: In a study by Walulkar Sanjay et al[11], three shapes of WBs was found and it was irregular, oval and triangular [Fig 7] in decreasing percentage incidence respectively. But in the present study, the most common type was irregular followed by triangular and then quadrangular. Even though a study[18] was done exclusively to observe different shapes of WBs, it failed to report the reason for the different shapes and its significance.

Edges of Wormian bones: 33 skulls showing irregular edges [Fig 7] and 12 skulls showing serpigenuous edges [Fig 6]. This correlates with a study by A.Vasanthi[8], which showed 3 skulls with serpigenuous edges and 7 skulls with irregular edges.

Causes for the formation of WBs:

Embryological reasons are due to WBs formed due to extra ossification centres close to the sutures [11]. WBs can be considered only as supplementary centres of ossification and have no contribution to the solidity of the cranium [13].

Genetic reasons are also put forward by some authors and Liu et al[20] opined that it could be due to a gene called MSX2 which plays a role in fusion of sutures. It is also said that they are inherited as dominant trait with incomplete penetrance[21].

Hydrocephalic skulls have a large number of WBs which occur to compensate the additional cranial growth when the normal cranial capacity is

not sufficient [11].

Some authors also mention that some brain disorders lead to formation of WBs. But, Muralimanjuetal[10] states that WBs are formed in early membranous stage before formation of duramater and hence there is no correlation between brain disorders and WBs.

Artificial cranial deformation is another reason for formation of WBs[22].

CONCLUSION

The current study reports an incidence rate of 48% of WBs. Most of the skulls exhibited WBs in the lambdoid suture followed by lambda, parietomastoid, coronal, asterion, sagittal, occiptomastoid, parietosquamous and pterion. There was no correlation between the length of the sutures and the number of WBs. Three different shapes of WBs were witnessed; quadrangular, irregular and triangular, the highest of which was WBs of the quadrangular type and the least number of WBs exhibited the triangular type. Two types of edges were seen; more number of skulls exhibiting irregular edges, followed by serpigenous edges. Even though there is no true morphological significance for WBs, further investigations should be done to find the same. This study will be of great importance to orthopedicians, radiologists and traumatologists.

Conflicts of Interests: None

REFERENCES

- [1]. Henry Gray. Head and neck, Gray's Anatomy, The Anatomical Basis of Clinical Practice, 40th edition, Susan Standring (Ed) 2008; Section 4, 411-418.
- [2]. B. Marti, D. Sirinelli, L. Maurin, E. Carpentier. Wormian bones in a general paediatric population. Diagnostic and Interventional Imaging, 2013;94:428—432.
- [3]. Tejaswini M Pawar, Prakash B S ,Padmalatha K , Balachandra N, Prathap Kumar J, Ramesh B R. Incidence of OsInterparietaleWormian bones. Dr B R Ambedkar International Journal of Medical Sciences. 2014;1(1):44-46.
- [4]. Charles V.Pryles, Abdul J.Khan. Wormian bones: Radiological warning of abnormal nervous system. pediatric research 1974;8:463—463.
- [5]. Jeanty P, Silva SR, TurnerC.Prenatal diagnosis of wormian bones. J Ultrasound Med. 2000;19(12):863-9.
- [6]. P. SharmilaBhanu, K. Devi Sankar. Interparietal and pre-interparietal bones in the population of south coastal Andhra Pradesh, India. Folia Morphol. 2011;70(3):185-190.
- [7]. Fakhruddin S, Bhalerao UK. Interparietal bone in three pieces, a case report. Anatomical Society of India. 1967;16:146-147.
- [8]. A. Vasanthi, K. P. S. Adinarayana, S. Pujitha. Morphological study of wormian bones in cadaver skulls. Journal of Evidence based Medicine and Healthcare. 2015;2(12):1757-1762.
- [9]. Graham JM Jr,Kreutzman J, Earl D,Halberg A,Samayoa C,Guo X. Deformational brachycephaly in supine-sleeping infants. J Pediatr. 2005;146(2):253-7.
- [10]. Murlimanju BV, Prabhu LV, Ashraf CM, Kumar CG, Rai R and Maheshwari C. Morphological and topographical study of Wormian bones in cadaver dry skulls. J. Morphol. Sci. 2011;28(3):176-179.
- [11]. Sanjay Walulkar, D Ksheersagar, MadhaviWalulkar. The study of wormian bones in human skulls in Vidarbharegion.PJMS 2012;2(2):18-21.
- [12]. Khan AA, Asari MA, Hassan A. Unusual presence of wormian (sutural) bones in human skulls. Folia Morphol. 2011;70(4):291-294.
- [13]. Jean Cruveilhier.The Anatomy of the Human Body, Granville Sharp Pattison (Ed), 1844, page 50. http://www.archive.org/details/anatomy_of_human_bo_0/Ocruvrich
- [14]. A. Caroline Berry and R.J Berry. Epigenetic variation in the human cranium. J. Anat. 1967;101(2):361-379.
- [15]. Cirpan S,Aksu F, MasN.The Incidence and Topographic Distribution of Sutures Including Wormian Bones in Human Skulls.JCraniofac Surg. 2015;26(5):1687-90.
- [16]. Distribution of Sutures Including Wormian Bones in Human Skulls. Journal of Craniofacial Surgery. 2015;26(5):1687—1690.
- [17]. Rajani Singh. Incidence of sutural bones at asterion in adults Indians skulls. International journal of morphology. 2012;30(3):1182-1186.
- [18]. Hari Prasad, Anshu Mishra, Parmatma Prasad Mishra, N K Bezbaruah and Prerna Gupta. Study of variations of bony pattern and presence of wormian bone at pterion in dry human skulls. IJBR, 2014;05(11):668-670.
- [19]. BapatRuta, Umarji B. N.Study of the shapes of Sutural Bones in Western India. Int J Biol Med Res. 2012;3(3):2269-2270.
- [20]. Liu YH, Tang Z,Kundu RK, Wu L, Luo W, Zhu D,Sangiorgi F, Snead ML,Maxson REMsx2 gene dosage influences the number of proliferative osteogenic cells in growth centers of the developing murine skull: a possible mechanism for MSX2-mediated craniosynostosis in humans. Dev Bio., 1999;205(2):260-74.
- [21]. María Patricia Ordoñez Alvarez. The prevalence of Wormian bones in relation with Ancestry: A comparison between Caucasian and Mongoloid populations in the light of Artificial Cranial Deformation and Pathological conditions doctoral diss,CranfieldDefence and Security: Cranfield university, July- 2011.[22].
- [22].SreekanthTallapaneni, ChigurupatiNamrata, SwathiVeliginti, AbishekMogili, Shahzeb Zaman, FarazAdil Hashmi. Fourteen wormian bones in an adult Indian skull – A rare case report. Medical Science, 2013;1(3):55-59.