

MORPHOLOGICAL STUDY OF BRACHIAL ARTERY AND ITS VARIATIONS IN BRANCHING PATTERN

Sushma ^{*1}, Kavitha K ², Satheesha K S ³.

^{*1} Assistant Professor, Department of Anatomy, Srinivas Institute of Medical Sciences and Research Centre, Mukka, Mangalore, Karnataka, India.

² Lecturer, Department of Anatomy, K.L.E. Society's Institute of Dental Sciences, Bangalore, Karnataka, India.

³ Professor and HOD, Department of Anatomy, Srinivas Institute of Medical Sciences and Research Centre, Mukka, Mangalore, Karnataka, India.

ABSTRACT

Background: The brachial artery, a continuation of the axillary artery, begins at the distal (inferior) border of the tendon of teres major and ends distal to the elbow joint (at the level of the neck of the radius) by dividing into radial and ulnar arteries. The brachial artery is wholly superficial, covered anteriorly only by skin and superficial and deep fascia. In the present study we aimed to describe the high origin of brachial artery and its branching variations.

Materials and methods: The present study was conducted in 40 formalin fixed upper limbs selected by convenient sampling irrespective of age and sex over a period of 6 months. The brachial artery was exposed and the length of the brachial artery and the distance of the profunda brachii artery from the lower border of teres major were measured using a thread and a measuring tape. Variations of brachial artery and its branches were noted.

Results: In the present study, arterial variations can be classified as high division of brachial artery in five limbs, which is 12.5% of the 40 limbs dissected. Origin of profundabrachii artery is quite variable in 15% (6 limbs) of cases.

Conclusion: Variations of Brachial artery and its branches are common both in respect of formation and termination. Knowledge of the vascular variations will increase the success of the surgical and radiological procedures.

KEY WORDS: Brachial Artery, Radial Artery, Ulnar Artery, Profunda Brachii Artery.

Address for Correspondence: Dr.Sushma, Department of Anatomy, Srinivas Institute of Medical Sciences and Research centre, Mukka, Surathkal, Mangalore-574146, Karnataka, India.

E-Mail: sushmavasudev@gmail.com.

Access this Article online	Journal Information
Quick Response code  DOI: 10.16965/ijar.2018.385	International Journal of Anatomy and Research ICV for 2016 90.30 ISSN (E) 2321-4287 ISSN (P) 2321-8967 https://www.ijmhr.org/ijar.htm DOI-Prefix: https://dx.doi.org/10.16965/ijar 
Article Information	
Received: 14 Sep 2018	Accepted: 24 Oct 2018
Peer Review: 19 Sep 2018	Published (O): 05 Dec 2018
Revised: None	Published (P): 05 Dec 2018

INTRODUCTION

The brachial artery, a continuation of the axillary artery, begins at the distal (inferior) border of the tendon of teres major and ends distal to the elbow joint (at the level of the neck of the radius) by dividing into radial and ulnar

arteries. The brachial artery is wholly superficial, covered anteriorly only by skin, superficial and deep fasciae. At first it is medial to the humerus, but gradually spirals anterior to it until it lies midway between the humeral epicondyles [1].

Branches of the brachial artery are as follows:

Profunda brachii artery: The profunda brachii artery is a largest branch from the posteromedial aspect of the brachial artery, distal to teres major. It is accompanied by the radial nerve, at first posteriorly between the long and medial heads of triceps, then in the spiral groove covered by the lateral head of triceps. It supplies muscular branches, the nutrient artery of the humerus, and finally divides into terminal radial and middle collateral branches. The profunda brachii can originate from a common origin with the posterior circumflex humeral artery, from the axillary artery proximal to the tendon of latissimus dorsi or from the distal portion of the axillary artery [1].

Middle collateral (posterior descending) branch: The middle collateral artery is the larger terminal artery of profunda brachii artery. It arises posterior to the humerus and descends down the posterior surface of the lateral intermuscular septum to the elbow. Proximally, the artery lies between brachialis (anteriorly) and the lateral head of triceps (posteriorly) while distally it lies between brachioradialis (anteriorly) and the lateral head of triceps (posteriorly). It may pierce the deep fascia and become cutaneous or remain deep to the fascia until it anastomoses with the interosseous recurrent artery behind the lateral epicondyle [1].

Radial collateral (anterior descending) branch: The radial collateral artery is the continuation of the profunda brachii artery. It accompanies the radial nerve through the lateral intermuscular septum, descending between brachialis and brachioradialis anterior to the lateral epicondyle, anastomosing with the radial recurrent artery. It supplies brachialis, brachioradialis, the radial nerve and a few fasciocutaneous perforators [1].

Nutrient artery of Humerus: The nutrient artery of the humerus arises near the mid-level of the upper arm, and enters the nutrient canal near the attachment of coracobrachialis, posterior to the deltoid tuberosity [1].

Deltoid (ascending) branch: The deltoid branch ascends between the lateral and long heads of triceps, and anastomoses with a descending branch of the posterior circumflex humeral artery [1].

Nutrient artery of the humerus: It arises close to the insertion of coracobrachialis and enters the nutrient foramen of the humerus which is directed distally indicating that the upper end of humerus is the growing end [1].

Superior ulnar collateral artery: The superior ulnar collateral artery arises a little distal to the mid-level of the upper arm, usually from the brachial artery. It accompanies the ulnar nerve, piercing the medial intermuscular septum to descend in the posterior compartment and supply the medial head of triceps. It passes between the medial epicondyle and olecranon, ending deep to flexor carpi ulnaris by anastomosing with the posterior ulnar recurrent and inferior collateral arteries. A branch sometimes passes anterior to the medial epicondyle and anastomoses with the anterior ulnar recurrent artery [1].

Inferior ulnar collateral (supratrochlear artery): The inferior ulnar collateral artery begins 5 cm proximal to the elbow, passes medially between the median nerve and brachialis and, pierces the medial intermuscular septum, and runs posteriorly behind the humerus between the triceps and bone. It anastomoses with the middle collateral branch of the profunda brachii artery, proximal to the olecranon fossa. As it lies on brachialis it gives off branches which descend anterior to the medial epicondyle to anastomose with the anterior ulnar recurrent artery. Behind the epicondyle a branch anastomoses with the superior ulnar collateral and posterior ulnar recurrent arteries [1].

Middle ulnar collateral artery: If present, the middle ulnar collateral artery arises from the brachial artery between the superior and inferior ulnar collateral arteries. It passes anterior to the medial epicondyle and anastomoses with the anterior ulnar recurrent artery [1].

Muscular branches: Muscular branches are distributed to the coracobrachialis, biceps and brachialis.

Radial and ulnar arteries are the terminal branches of brachial artery.

MATERIALS AND METHODS

This was a cross sectional study conducted in the Department of Anatomy, Srinivas institute

of Medical Sciences and Research Centre, Mangalore in 40 consecutive formalin fixed upper limbs selected by convenient sampling irrespective of age and sex over a period of 6 months.

Method of Data Collection

1. For upper limbs: Longitudinal incision was taken through the deep fascia along the midline of arm and was dissected to display full length of biceps muscle. The brachial artery was exposed and the length of the brachial artery and the distance of the profunda brachii artery from the lower border of teres major was measured using a thread and a measuring tape. The following observations were made and noted:

(1) Length of the brachial artery:

For measuring its length, the following 2 points were taken:

(a) The point from where the artery begins i.e. at lower border of teres major.

(b) At the point of termination of the artery or the intercondylar line.

(2) Branches of brachial artery:

The sites of origin of all the branches were noted and the distance between proximal point of main trunk (lower border of teres major) and the origin of the branch was measured.

Statistical Analysis: Data collected was entered in Microsoft Excel and the statistical analysis was performed using SPSS 20. The analysis was performed to compare observations found in right versus left upper limbs. The following aspects were discussed, Anatomical variations and Classification of variations.

RESULTS

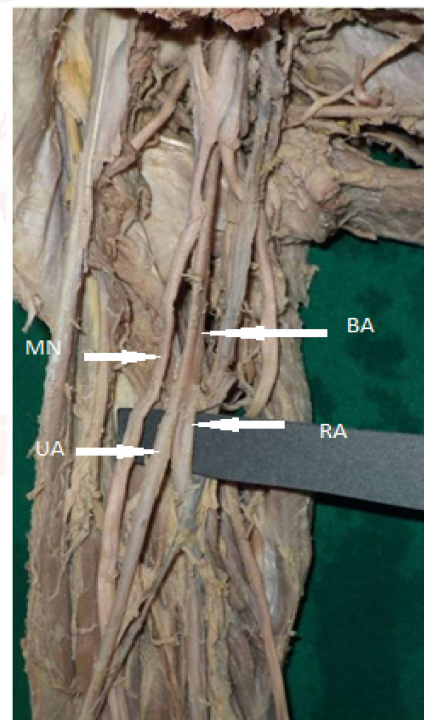
In all 40 limbs, brachial artery is continuation of axillary artery at the lower border of teres major muscle. The length of the brachial artery varied between 20.03 cm (± 4.64) in the right limbs, 18.75 cm (± 6.33) in left limbs. There was no significant difference in the length of brachial artery in both sides.

The values of the point of origin of the profunda brachii artery varied between 1.66cm (± 1.04) in right limbs and 1.44cm (± 0.86) in left limbs. (graph 2)

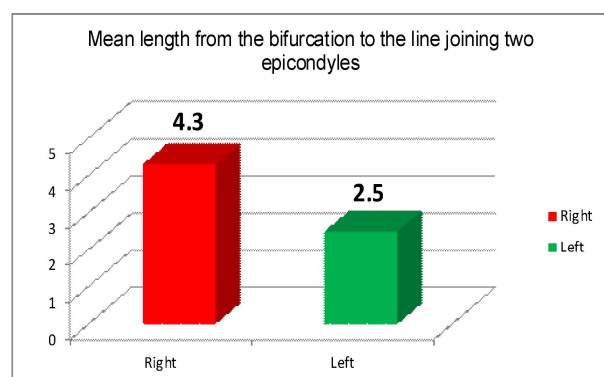
Mean distance of the variant brachial artery from the point of its bifurcation to the line joining medial and lateral epicondyles was 4.3 cms on right side and 2.5 cm on left side. (graph 1)

In the present study arterial variations can be classified as high division of brachial artery in five limbs, which is 12.5% of the 40 limbs dissected. In one case, axillary artery in its third part, 3 cm proximal to lower border of teres major bifurcated into superficial and deep branches which in the forearm continued as radial and ulnar arteries respectively. Here the distance between the lower border of teres major and intercondylar line was 23 cm while distance between point of bifurcation of axillary artery and intercondylar line was 26 cm.

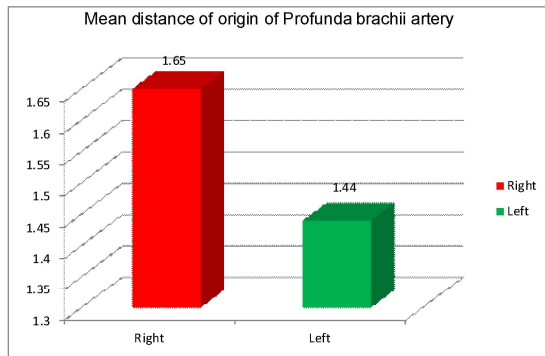
Fig. 1: Representing high bifurcation of brachial artery.



Graph 1: Showing mean distance (in cms) of right and left Brachial Arteries with high divisions from point of its bifurcation to the line drawn between medial and lateral epicondyles.



Graph 2: Mean distance (in cms) of origin of Profunda brachii artery from the lower border of Teres Major



Origin of profunda brachii artery is quite variable in 15% (6 limbs) of cases. The profunda brachii artery was arising as a common trunk with the posterior circumflex humeral artery before entry of posterior circumflex humeral artery into quadrangular space in two limbs (5%), as a common trunk with superior ulnar collateral artery in 2 limbs (5%), origin of profunda brachii artery by 2 separate branches in one limb (2.5%), as followed according to Type IV, Type V, Type VI, classification (Nakatani et al.). The profunda brachii artery arising from radial artery associated with high division of brachial artery is also found one limb (2.5%).

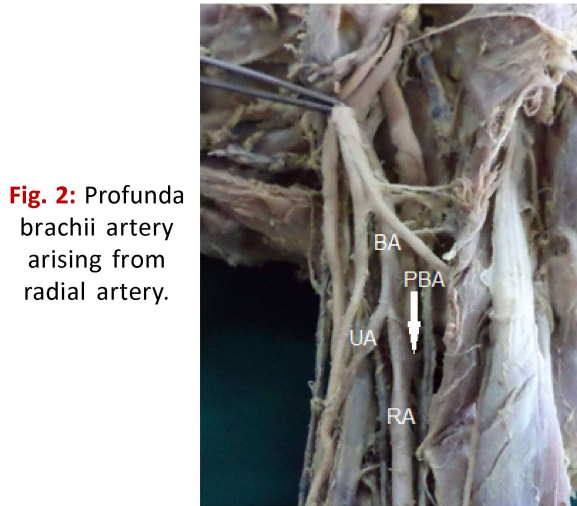


Fig. 2: Profunda brachii artery arising from radial artery.

Variations in Profunda Brachii Artery

Profunda brachii artery arising as a common trunk with posterior circumflex humeral vessels-Type 5 (Figure 3 and 4)

Profunda brachii artery arising as a common trunk with superior ulnar collateral artery-Type 2 (Figure 5 and 7)

Origin of profunda by two separate branches-Type 1A (Figure 6)

Profunda brachii artery arising from radial artery (Figure 2)

In 2 of the limbs (5%) superior ulnar collateral artery is not arising as a direct branch of brachial artery. Inferior ulnar collateral artery was found to be absent in two limbs out of 40 limbs (5%). According to Polanska(1932)'s statement that "the smaller branches of brachial artery specially those vessels that anastomose around the elbow to form collateral circulation, have no constant pattern" is justified.

Fig. 3: Profunda brachii artery arising as a common trunk with posterior circumflex humeral vessels.

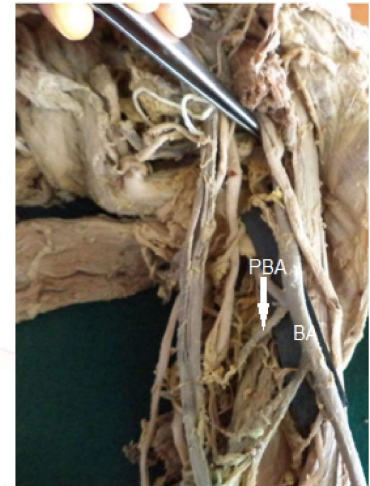


Fig. 4: Profunda brachii artery arising as a common trunk with posterior circumflex humeral vessels

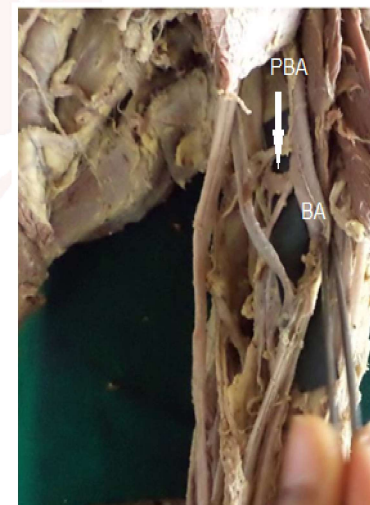

Fig. 5: Profunda brachii artery arising as a common trunk with superior ulnar collateral artery.

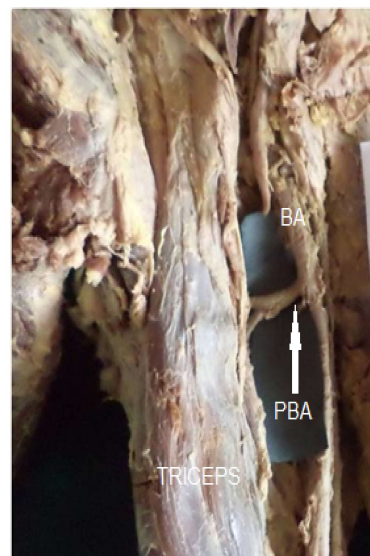


Fig. 6: Origin of profunda brachii artery by two separate branches.

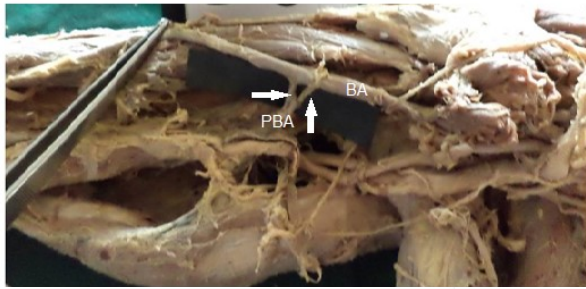



Fig. 7: Profunda brachii artery arising as a common trunk with superior ulnar collateral artery.



DISCUSSION

Anomalies of the forelimb arterial tree are fairly common. This is mainly because of their multiple and plexiform sources, the temporal succession of emergence of principal arteries, anastomoses and periarticular networks and functional dominance followed by regression of some paths[2]. High origin of radial and ulnar artery forms the highest percentage of variations of brachial artery.

High origin of radial artery occurrence is 3 to 15 %, as reported by different authors[3-5]. The parent trunk being axillary artery in 12.5%, proximal 1/3 of brachial artery in 62.5% and middle 1/3 of brachial artery in 25% [3]. They found high origin of ulnar artery in 1% cases only and compared it with similar reports by others [3, 4].

Arterial variation in the upper limb was noted for the first time by von Haller in 1813. He made embryological studies on the variation of arterial pattern of upper limb but the exact findings were not obtained. The arteries develop from the axial trunk and extend from the axilla to the fingers. The proximal segment regresses to form the inactive adult pattern (Rodríguez-Baeza et al) [5].

The anomalous blood vessels may be due to:

I. The choice of unusual paths in the primitive vascular plexuses.

II. The presence of vessels that are normally obliterated.

III. The disappearance of vessels that are normally retained

IV. Incomplete development.

V. Fusion and absorption of the parts which are usually distinct (Dorros & Lewin, 1986) [6].

McCoramack et al dissected 750 cadavers and found variations in respect of origin and course of the arteries of upper limb, the percentage of variations noticed by them was 18.53% [7]. In their study bilateral variation occurred in 6.32%, while in 24.45% there was unilateral variation. Most of these variations occurred more frequently on the right side by a ratio of 1.2:1, the variations of the axillary artery as compared with those of origin of brachial artery showed disparity. The variant vessels arising from left side of the axillary artery were found with a ratio of 3:1 (18 left and 6 right), while those from the brachial artery were found predominantly on the right side in a ratio of 1.5:1 (65 right and 43 left).

Classification of arm arterial variations [6]

I. Brachial artery passes in front of the median nerve and continues as:

- a. Arteria brachialis superficialis superior,
- b. Arteria brachialis inferior.

II. Double brachial artery i.e., superficial and deep:

- a. Brachialis superficial superior.
 - b. Brachialis inferior.
1. Superficial and deep reunite.
 2. Superficial continues as the radial: a) without anastomosis. b) with anastomosis.
 3. Superficial brachial continues as a) Ulnar b) Median c) Ulnar and Median
 4. Superficial brachial as the radial and superficial antebrachial (Ozcan et al.)

According to Adachi (1928) this superficial brachial artery is so called because it runs superficial to median nerve, whereas usually the brachial artery runs deep to median nerve. The superficial brachial artery may replace the main trunk or may be accompanied by equally important, less important or more important trunk running parallel and deep to median nerve in

normal position. In these cases superficially placed vessels may continue as radial or more rarely ulnar artery.

Keen (1961) subdivides superficial brachial artery (found in 12.3% dissections) into 3 types:

(a) Those superficial brachial arteries which continue in cubital fossa and bifurcate as usual into radial and ulnar arteries (3.6%).

(b) Superficial brachial artery continues as radial artery and known as 'High origin of radial artery' (5.9%).

(c) Superficial brachial artery continues as ulnar artery and known as 'High origin of ulnar artery' (2.8%).

Profunda brachii artery:

The profunda brachii (deep brachial) artery may arise from the third part of the axillary artery (16%, Anson in 1966, cited by İçten et al) or in common with one or more branches of that vessel, (19% of individuals, Poynter, cited by İçten et al.), or arise as a common trunk with superior ulnar collateral (22%, Anson), axillary (16%) or anterior and posterior circumflex humeral artery (7%, Anson, İçten et al) [6].

The origin of profunda brachii artery is quite variable. There are 7 types of origin for this artery.

Type I: Branch of brachial artery in 54.7% cases (55% by Anson in 1966- 67, cited by Nakatani et al., 1996).

Type Ia: Origin of arteria profunda brachii by 2 separate branches (seen in 0.7% dissections).

Type Ib: Origin of arteria profunda brachii by 3 separate branches (seen in 0.3% dissections).

Type II: Arising as a common trunk with superior ulnar collateral in 22.3% cases (22% by Anson).

Type III: Arising at lower border of teres major so can be considered to be arising from axillary or brachial in 8% cases.

Type IV: Branch of 3rd part of axillary artery in 8.7% cases (16.0% by Anson).

Type V: Arising as a common trunk with posterior circumflex humeral in 4% cases (13% by Keen, 1961 and 7% by Anson, both cited by Nakatani et al.). Former includes 6% cases before entry of posterior circumflex humeral into quadrangular space and 7% cases after its

entry into quadrangular space (Nakatani et al.).

Type VI: Arising as a common trunk with subscapular and both circumflex humeral from axillary artery in 0.7% cases.

Type VII: Absent arteria profunda brachii in 0.7% cases (Nakatani et al) [8].

In the present study arterial variations can be classified as high origin of radial artery in five cases, which is 12.5% of the 40 limbs dissected. Origin of profunda brachii artery is quite variable in 15% of cases. The profunda brachii artery was arising as a common trunk with the posterior circumflex humeral artery before entry of posterior circumflex humeral artery in quadrangular space in two limbs (5%), as a common trunk with superior ulnar collateral artery in 2 limbs (5%), origin of profunda brachii artery by 2 separate branches in one limb (2.5%). The profunda brachii artery arising from radial artery associated with high division of brachial artery is also found one limb (1.6%). There was no significant difference in the length of brachial artery in both sides. The unusual short segment brachial artery with its high up division into radial and ulnar arteries as observed in the present study can be explained in the light of embryological development.

Polanskaja (1932) pointed out that the smaller branches of brachial artery, especially those which anastomose around the elbow to form the collateral circulation, have no constant pattern. He further added that he was never able to find the same pattern even on the two sides of one body [9].

CONCLUSION

In the present study, the values of length, point of origin of the brachial artery and its branches in right and left upper limbs were compared and their variations were noted. In recent advances the radial artery is used in reconstructive micro vascular surgeries and also in plastic surgeries. The radial forearm flap is ideal for intra-oral reconstruction to replace oral mucosa. This study will be of help to the radiologists and surgeons in the correct diagnosis and treatment of the patients with arterial anomalies.

ABBREVIATIONS

BA- Brachial artery PBA- Profunda brachii artery

RA- Radial artery UA- Ulnar artery
SUC- Superior ulnar collateral artery
MN- Median nerve
BB- Biceps brachii

Conflicts of Interests: None

REFERENCES

- [1]. Susan Standring. Gray's anatomy. 39th edition-The Anatomical Basis of Clinical Practice; 2008; 855 – 56.
- [2]. Williams PL, Bannister LH, Berry MM, Collins P, Dyson M, Dussek JE, Ferguson MW, eds. Gray's Anatomy. 38th Ed., London, Churchill Livingstone. 1999; 319, 1539
- [3]. Karlsson S, Niechajev IA. Arterial anatomy of the upper extremity. Acta Radiologica.1982;23,115-121.
- [4]. Muller E. Beitrage zur Morphologie des Gefaßsystems.I. Die Arterien des Menschen. Anatomische Hefte 1903; 22,377-575.
- [5]. Rodriguez-Baeza A, Nebot, J, Ferreira, B, Reina F, Perez, J, Sanudo, J R. & Roig M. An anatomical study and ontogenetic explanation of 23 cases with variations in the main pattern of the human brachio-antebrachial arteries. J. Anat. 1995;187(2):473-9.
- [6]. Suresh B, Ramakrishna A, Arunachalam K. Primary Pattern of Arteries of Upper Limb with Relevance to their Variations. Int. J. Morphol. , 2011;29(4):1422-1428.
- [7]. McCormack, L. J. Caldwell, E. W. & Anson, B. J. Brachial and antebrachial arterial patterns; a study of 750 extremities. Surg.Gynecol. Obstet., 1953;96(1):43-54.
- [8]. Nakatani T, Tanaka S, Mizukami S. Superficial brachial artery continuing as the common interosseous artery. J. Anat. 1997;191(1):155-7.
- [9]. Patnaik, V.V.G; Branching pattern of Brachial artery- Morphological study, J Anat. Soc. India 2002;51(2):176-186.
- [10]. Susan Standring. Grays Anatomy 40th Edition. 2008.
- [11]. David B Jenkins. Hollinshead's Functional anatomy of the limbs and back. 9th ed, 2009. 107-121.
- [12]. Shewale SN, Sukre SB, Diwan CV. Bifurcation Of brachial artery at its commencement-A case report. Biomedical Research 2012;23(3):453-456.
- [13]. U.V.mane and S.R.Pandhare .Unusual Arterial Variation of Upper Limb – Case Report. IJRTST. 2011;1(2):61-64.
- [14]. Sharadkumar PS, Shaguphta TS, S. D. Lele, Shaheen R, S.R.Menon, R.Uma, Rakhi MM. A case report on two profundabrachii artery originating from the brachial and the posterior circumflex humeral arteries. IJRRPAS. 2012;2(6):1008-1013.
- [15]. Bojana K, Bijana SRDC, Dusica M, Radmila G, SasaMijatov, Sinisa SB. An anatomical study of double brachial arteries-a case report. IJAV. 2010;3:8-8.
- [16]. K.Ozisik, K.Dural, C.CemDenk, B.Kocer, U.Sakinci. Brachial artery occlusion in patients with b/l high origin of radial artery. Ejves. 2003;20-20.
- [17]. Bilodi AK and Sanikop MB Variations in termination of brachial artery – A case report. Kathmandu University Medical Journal 2004;2(1):49-51.
- [18]. Chandrika T, Nilesh NK, Paarhipan N. High division and variation in brachial artery branching pattern. IOSR Journal of Dental and Medical Sciences (IOSR-JDMS). Jan.- Feb. 2013;3(6):68-70.
- [19]. Sawant SP. A case report on cadaveric variation of trifurcation of the brachial artery and its developmental basis. World research journal of cardiology. 2013;1(1):01-03.
- [20]. Sharadkumar PS, Shaguphta TS, Rakhi MM, Shaheen R, S.R.Menon, R. Uma. A case report on variant termination of the brachial artery (GARJSHPS). Dec 2012; Vol. 1(1): pp. 007-010.
- [21]. Mehmet MC, Umut O, Yasemin K, Arzu H, Fatos BY, Levent S. Four-headed biceps brachii, three-headed coracobrachialis muscles associated with arterial and nervous anomalies in the upper limb. Anat Cell Biol 2012;45:136-139.
- [22]. T.W. Sadler. Langmans Medical Embryology: 8th Edition. pp180-183.
- [23]. Bergman RA, Thompson SA, Afifi AK. Catalog of human variation. Baltimore: Urban and Schwarzenberg; 1985; 108-14.
- [24]. Anson, B.J. & Morris. Human Anatomy in; the cardiovascular system-Arteries and veins. Thoms, M. E. Dr. Mc Grow Hill Book c. new York. 1966; 708-724.
- [25]. De Garis CF, Swartley WB. The axillary artery in white and Negro stocks. Am J Anat. 1928;41:353-97.
- [26]. Peter LW, Dyson B. Gray's Textbook of Anatomy – 37th edition. Elsevier Churchill Livingstone, London. 1993;299-300.
- [27]. Keen JA. A study of the arterial variations in the limb with special reference to symmetry of vascular patterns. Am J Anat, 1961;108:245-261.
- [28]. Adachi, B: Das Arteriensystem des japaner, Kyoto 1928;1:205-10.

How to cite this article:

Sushma,Kavitha K, Satheesha K S. MORPHOLOGICAL STUDY OF BRACHIAL ARTERY AND ITS VARIATIONS IN BRANCHING PATTERN. Int J Anat Res 2018;6(4.3):5963-5969. DOI: 10.16965/ijar.2018.385