

## STUDY OF BRACHIALIS MUSCLE: ADDITIONAL SLIP AND ITS CLINICAL SIGNIFICANCE

Jayakumar V R <sup>1</sup>, Paramasivam V <sup>\*2</sup>, Roshni Bajpe <sup>3</sup>.

<sup>1</sup> Assistant professor, Department of Anatomy, Coimbatore medical college, Coimbatore, Tamil Nadu, India.

<sup>\*2</sup> Assistant professor, Department of Anatomy, Government Mohan Kumaramangalam medical college, Salem, Tamil Nadu, India.

<sup>3</sup> Professor, Department of Anatomy, Kempegowda institute of medical sciences (KIMS), Bangalore, Karnataka, India.

### ABSTRACT

**Background:** Brachialis is a muscle of anterior compartment of arm. It has two heads. Superficial head inserting into ulnar tuberosity innervated by musculocutaneous nerve, the deep head inserts into coronoid process of ulna and supplied by radial nerve. Neuromuscular compression due to presence of additional slip of brachialis forms the basis of this study.

**Materials and methods:** Study was done in 60 adult human cadaveric upper limbs of both the sides irrespective of sex in the Department of Anatomy, Kempegowda institute of medical sciences (KIMS), Bangalore and other medical colleges nearby. Presence of additional slips of brachialis with important and interesting relations was found which were comparable with previous studies. As qualitative method was done, Descriptive statistics were utilized.

**Results:** Additional slips were present in 21.6%. It was found mainly in the left upper limbs in 69.2% and rest 30.7% are present in right side limbs. Among 13 specimens, additional slips originated mainly from the anteromedial aspect in 84.6% and in 15.3% it originated from the anterolateral aspect of main brachialis. Additional slips were innervated mostly by the musculocutaneous nerve in 69.2%, median nerve in 15.3% and radial nerve in 7.6%. No innervation was observed in one specimen.

**Conclusion:** Knowledge of additional slips and its origin and course is very important for identifying the cause for neurovascular symptoms due to compression of neurovascular structures

**KEY WORDS:** Brachialis muscle, additional slip, compression syndrome, reconstruction surgery

**Address for Correspondence:** Dr.V.Paramasivam MS, Assistant professor, Department of Anatomy, Government Mohan Kumaramangalam medical college, Salem, Tamil Nadu, India.

**E-Mail:** sakthiparamasivam.velu@gmail.com

Access this Article online	Journal Information
<b>Quick Response code</b>  DOI: 10.16965/ijar.2018.387	<b>International Journal of Anatomy and Research</b> ICV for 2016 90.30 ISSN (E) 2321-4287   ISSN (P) 2321-8967 <a href="https://www.ijmhr.org/ijar.htm">https://www.ijmhr.org/ijar.htm</a> DOI-Prefix: <a href="https://dx.doi.org/10.16965/ijar">https://dx.doi.org/10.16965/ijar</a> 
<b>Article Information</b>	
Received: 14 Sep 2018 Peer Review: 14 Sep 2018 Revised: None	
Accepted: 24 Oct 2018 Published (O): 05 Dec 2018 Published (P): 05 Dec 2018	

### INTRODUCTION

Brachialis is a muscle of anterior compartment of the arm. It arises from the lower half of the front of humerus, starting on either side of the insertion of deltoid muscle and also from the medial intermuscular septum. It crosses cubital

fossa and its fibers converge to a thick broad tendon which is attached to the ulnar tuberosity and to the rough impression on the anterior aspect of coronoid process of ulna. Muscle is related anteriorly to biceps, brachial vessels, musculocutaneous and median nerve,

posteriorly to humerus and capsule of elbow joint, medially to pronator teres, medial inter muscular septum, laterally to radial nerve, radial recurrent and radial collateral arteries, brachioradialis and extensor carpi radialis longus. It may be divided into two or more parts, which may fuse with brachioradialis, pronator teres or biceps. In some cases it sends tendinous slips to the radius or bicipital aponeurosis [1]. Presence of additional slip is important due to compression of vital structures leading to neurovascular symptoms. Knowledge of additional slip is useful for the surgeons because these muscle fibres are used to reconstruct annular ligament or medial collateral ligament of elbow joint also the fibres are used as a transposition flap in deformities of infraclavicular and axillary areas and in post mastectomy reconstruction.

## MATERIALS AND METHODS

Study was done on 60 formalin fixed intact upper limbs of 30 Adult human cadavers in the Department of Anatomy, Kempegowda institute of medical sciences (KIMS), Bangalore and from other medical colleges nearby. Study was done on Adult human cadavers irrespective of sex by dissection method. Presence of additional slips of brachialis was studied. Their origin, insertion, nerve supply and presence of any additional slips and its related neurovascular structures were noted.

## RESULTS

Present study done in 60 cadaveric upper limbs (24 right and 36 left) had additional slips in 13 specimens (21.6%). They were found mainly in the left upper limbs in 9 specimens (69.2%) and rest 4 (30.7%) are present in right side limbs. Among 13 specimens, additional slips mostly arose from the anteromedial aspect of main brachialis in 11 specimens (84.6%) and from anterolateral aspect in 2 specimens (15.3%). They were innervated by the musculocutaneous nerve in 9 specimens (69.2%), median nerve in 2 specimens (15.3%) and radial nerve in one specimen (7.6%). No innervation was observed in one specimen. 10 out of 13 specimens were related to some neurovascular structures while rest 3 specimens did not show any related neurovascular structures. Most common structures

related are musculocutaneous nerve and its branches in 4 specimens, ulnar artery in 2 specimens, brachial artery and median nerve in 2 specimens, radial nerve in one specimen and communicating branch between median nerve and musculocutaneous nerve in one specimen.

**Table 1:** Percentage of origin of additional slips.

Origin of additional slip	Total number of specimens	%
Anteromedial aspect	11	84.60%
Anterolateral aspect	2	15.30%

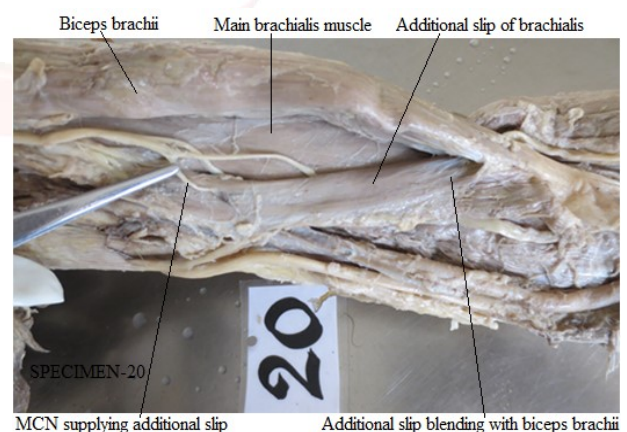
**Table 2:** Nerve supply of additional slips with percentage.

Nerves supplying additional slip	Number of additional slips supplied (Total 13 specimens)	%
Musculocutaneous nerve	9	69.20%
Radial nerve	1	7.60%
Median nerve	2	15.30%
Absent	1	7.60%

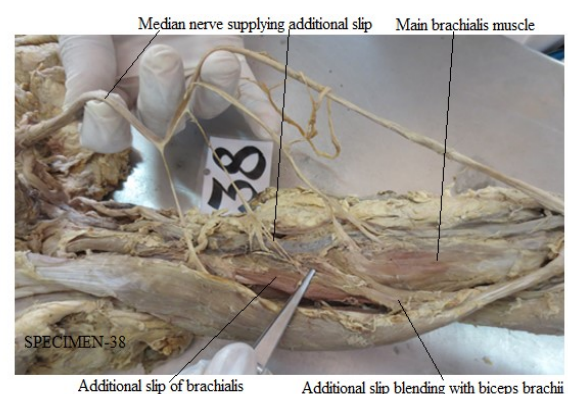
**Table 3:** Important structures related to the additional slips.

Structures related in 10 out of total 13 additional slips				
MCN and its branches	Ulnar artery	Brachial artery and median nerve	Radial nerve	Communicating branch between MN and MCN
4	2	2	1	1

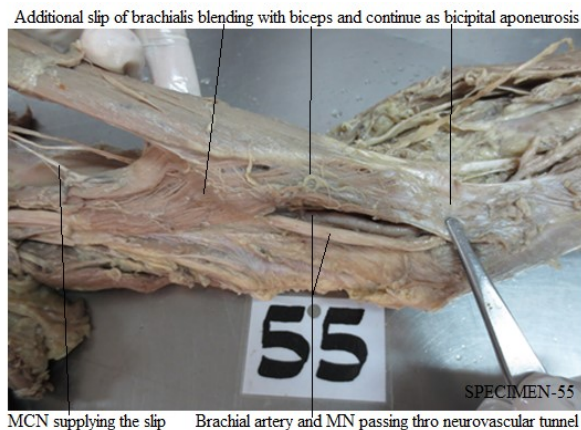
**Fig. 1:** Additional slip arising from anteromedial aspect and were supplied by musculocutaneous nerve (MCN).



**Fig. 2:** Additional slip with main brachialis muscle supplied by median nerve (MN).



**Fig. 3:** Additional slip forming a neurovascular tunnel and then blends with biceps to continue as bicipital aponeurosis.



## DISCUSSION

Nelluri et al, observed an accessory brachialis muscle (ABM) in the right arm which fused with the main brachialis muscle and originated from the lateral intermuscular septum at the fascia. ABM partially originates from the posterior compartment of the arm, crossing from the lateral side of the arm to the anterior compartment and lies lateral to the biceps brachii muscle, with the lateral cutaneous nerve of the forearm emerging between them and descends in front of the elbow joint to become part of the cubital fossa. The tendon of the ABM inserts to the medial surface of the radial shaft just below the radial tuberosity. An aponeurosis of the ABM is seen to emerge from the distal part of the ABM, arching over the radial artery, and with the other end attached to the deep fascia of the forearm [2].

Akhtar et al, found an additional slip from the anteromedial surface of the shaft along with the medial supracondylar ridge of the left humerus which merged with the fibres of pronator teres in the cubital fossa & finally inserted on the lateral surface of the shaft of the radius. This was supplied by the musculocutaneous nerve. In the upper arm, the median nerve lies along the lateral side of brachial artery but at the middle of the arm the nerve did not cross from lateral to medial side. In the lower part, they passed superficially to the brachialis muscle but lies deep to this additional slip of muscle. After separating the fibres of muscles it was found that median nerve was present just lateral to the brachial artery in the cubital fossa [3].

Khandey et al, found accessory slips in 4 specimens out of 115 specimens, which were mixed with main fibres at insertion point. Rarest of all was insertion of accessory brachialis muscle on radial tuberosity. The muscle originated from the lateral border of shaft of humerus and shared few fibres with main brachialis muscle. The muscle was inserted into the radius just below the radial tuberosity. It was supplied by radial nerve. 2 out of 115 specimens showed insertion of brachialis into bicipital aponeurosis [4].

Sirisinagandla et al, found a muscle variation in the left limb and was unilateral. From the distal third of brachialis muscle a few fleshy fibers descended downwards and medially in the form of a belly with the tendon crossing the cubital fossa contents and blended with the medial aspect of bicipital aponeurosis and it was attached on the sub cutaneous posterior margin of ulna. The median nerve and brachial artery were seen passing deep to the accessory slip of brachialis [5].

Misba et al, encountered a unilateral fibrous slip taking origin in the flexor compartment of left arm and merging with a flexor muscle of forearm. The fibrous slip was 3cm in length. The origin of fibrous slip was just 2cm above the muscle brachialis insertion to the coronoid process and ulnar tuberosity. This slip merged with brachioradialis just 4 cm below its origin in the proximal 2/3 of lateral supracondylar ridge of Humerus [6].

Sawant et al, observed an additional insertion of left brachialis muscle. The origin of the accessory muscle belly was from the antero-medial surface of the shaft and the medial supracondylar ridge of the lower end of the humerus. The accessory slip merged with the tendon of pronator teres and got inserted on to the upper one third of the lateral surface of the shaft of the radius. The accessory muscle belly of the brachialis muscle was innervated by musculocutaneous nerve. Median nerve and brachialis muscle travelled deep to the accessory muscle belly [7].

Muthukumar et al, found an accessory brachialis muscle taking origin from the anterolateral surface of the shaft of the lower humerus and also from the lateral intermuscular septum. The accessory brachialis muscle blended with main



brachialis muscle, it crossed the cubital fossa and both the main and accessory muscle blended with tendon of the biceps and got inserted into the posterior aspect of the radial tuberosity [8].

In present study, additional slips were present in 13 specimens (21.6%) found mainly in the left upper limbs in 9 specimens (69.2%). They mostly arose from the anteromedial aspect of main brachialis in 11 specimens (84.6%). They were innervated mostly by the musculocutaneous nerve in 9 specimens (69.2%). 10 out of 13 specimens were related to some neurovascular structures. Knowledge of additional slips and its origin and course is very important for identifying the cause for neurovascular symptoms due to compression of neurovascular structures.

**Embryological explanations:** The precursors of the musculoskeletal lineage are derived from the myotome of the somite. Myoblasts are stimulated to migrate into the developing limb buds by several growth factors produced by cells in the proximal limb bud. These premuscle cells express adhesion molecules that are important in properly distributing them throughout the limb. The presence of additional slip of brachialis muscle may indicate alterations in the formation and structure of the myotome or somite, or in the distribution of the cell adhesion molecules present on the premuscle cells. The interpretation of nerve anomaly of the arm requires consideration of the phylogeny and development of nerves of the upper limb. The axons of spinal nerves grow distally to reach the limb bud mesenchyme. As a guidance of the developing axons is regulated by expression of chemoattractants and chemorepulsants in a highly coordinated, site specific fashion any alteration in signal between mesenchymal cells and neuronal growth cones can lead to significant variations [6].

## CONCLUSION

Presence of additional slips in 21.6% specimens in our study was found to be highly significant. Knowledge about additional slip of brachialis is important for the anatomists, surgeons and orthopedicians who are operating in this area because these muscle fibres are used to reconstruct annular ligament or medial collateral ligament of elbow joint also the fibres are used as

a transposition flap in deformities of infraclavicular and axillary areas and in post mastectomy reconstruction.

## ABBREVIATIONS

MCN- musculocutaneous nerve

MN- median nerve

ABM- accessory brachialis muscle

**Conflicts of Interests: None**

## REFERENCES

- [1]. Standring S, Borley NR, Collins P et al. Gray's Anatomy: The Anatomical Basis of Clinical Practice. 40th ed. London: Elsevier Ltd;2008:826.
- [2]. Nelluri V, Swamy RS et al. Bulky accessory brachialis muscle with abnormal aponeurosis: A case report. Proceedings of Singapore Healthcare 2016;25(4):249–251.
- [3]. Akhtar MJ, Fatima N et al. An accessory brachialis muscle associated with abnormal arrangement of structures in the cubital fossa: A case report. International Journal of Research in Medical Sciences 2015;3(12):3907-10.
- [4]. Khandey S. Morphology of brachialis muscle: variations and clinical significance. International Journal of Anatomy and Research 2014;2(1):184–186.
- [5]. Sirasanagandla SR, Potu BK. Clinical and functional significance of accessory brachialis muscle: a unique anatomical variant. Int J Morphol 2013;31:1383–1385.
- [6]. Misba A, Rajasekar SS. A slip from brachialis muscle to Brachioradialis muscle: A case study. RGUHS J Med sciences 2013;3(4):222-224.
- [7]. Sawant SP, Shaikh ST et al. Additional insertion of brachialis muscle on the radius bone: A case report. Indian Journal of Basic and Applied Medical Research 2012;2(5):457-459.
- [8]. Muthukumar T, Srimathi et al. Anomalous Insertion of the Brachialis into the Radial Tuberosity: A case report. Journal of Clinical and Diagnostic Research 2012;6(1):116-17.

**How to cite this article:** Jayakumar V R, Paramasivam V, Roshni Bajpe. STUDY OF BRACHIALIS MUSCLE: ADDITIONAL SLIP AND ITS CLINICAL SIGNIFICANCE. Int J Anat Res 2018;6(4.3):5974-5977. DOI: 10.16965/ijar.2018.387