

A STUDY ON THE MORPHOLOGY OF ILEO-CAECAL REGION AND ITS CLINICAL CORRELATIONS

P.S. Chitra ¹, S. Kalaiyarasi ^{*2}.

¹ Professor of Anatomy, K.A.P.V.Govt.Medical College, Trichy, Tamil Nadu, India.

^{*2} Associate Professor of Anatomy, K.A.P.V.Govt.Medical College, Trichy, Tamil Nadu, India.

ABSTRACT

Background: The ileocaecal region is a juncture where the ileum enters the colon and the caecum is continuous proximally with terminal ileum and distally with the ascending colon. The ileocaecal orifice is guarded by ileocaecal valve. The caecum and the ileocaecal valve show significant variations in the shape and dimensions. The ileocaecal region is the common site for clinical conditions like polyps, diverticulae, volvulus & intussusception. Use of ileocaecal segment in bladder reconstruction surgery also makes anatomy of this region more important. The aim of our study was to elucidate the morphological variations of caecum and ileocaecal valve and their clinical importance.


Materials and Methods: The present study was conducted on 100 human cadaveric specimens, during routine dissection for the undergraduate students in the department of Anatomy, K.A.P.V. Government medical college, Trichy. The size & shape of the caecum, level of its peritoneal attachment, position & shape of the ileocaecal valve, its dimensions, the distance between the ileocaecal and appendicular orifices were noted and measured.

Results: The length of the caecum ranged from 2 to 7 cm. The breadth of caecum ranged from 4.5 to 7 cm. The shape of caecum was of Adult type in 97% of cases. The caecum was completely covered by peritoneum and not fused to the posterior abdominal wall in 75% of cases. The ileum terminates into the posteromedial aspect of caecum in 58% of cases. The shape of ileocaecal orifice was slit like in 49% of cases. The height of upper labia of ileocaecal valve was within the range of 0.5 cm-2.5 cm, and of lower labia ranged from 0.5 cm to 1 cm. The diameter of ileocaecal orifice varied from 1.1 to 2.5 cm. The distance between the ileocaecal and appendicular orifices ranged between 1.7 – 5 cm.

Conclusion: This study focused on normal and variant anatomy of caecum and ileocaecal junction. This study will be of help in radiological, ultrasonic and CT diagnosis of the ileocaecal region pathology and in planning for better therapeutic options.

KEY WORDS: Caecum, Ileocaecal Valve, Shape, Dimensions, Variations.

Address for Correspondence: Dr. S.Kalaiyarasi, M.S.(Anatomy), Associate Professor of Anatomy, KAPV Government Medical College, Tiruchirappalli, Tamilnadu. India. Mobile No: 99945 59046
E-Mail: arasitmc81@gmail.Com

Access this Article online	Journal Information
Quick Response code  DOI: 10.16965/ijar.2018.389	International Journal of Anatomy and Research ICV for 2016 90.30 ISSN (E) 2321-4287 ISSN (P) 2321-8967 https://www.ijmhr.org/ijar.htm DOI-Prefix: https://dx.doi.org/10.16965/ijar 
	Article Information
	Received: 19 Sep 2018 Peer Review: 19 Sep 2018 Revised: None
	Accepted: 24 Oct 2018 Published (O): 05 Dec 2018 Published (P): 05 Dec 2018

INTRODUCTION

Anatomically ileocaecal region is remarkably uncomplicated, though it is an imprecise anatomical region with an artificial boundary. The caecum, the proximal part of the colon, is a large blind pouch that lies in the right iliac fossa.

Proximally it is continuous with terminal ileum via ileocaecal orifice and distally with ascending colon. Its average length is 6 cm and breadth is 7.5 cm. Usually it is entirely covered by peritoneum. Occasionally it may be incomplete posterosuperiorly [1].

The caecum is morphologically classified into four types. I) Foetal type: Caecum is conical in shape, the vermiform appendix arises from the apex of conical caecum and the three taenia coli start from the appendix. This persists in about 2%. II) Infantile type: The conical caecum becomes quadrate by outgrowth of saccules of equal size on each side of anterior taenia. Appendix arises from the depression between them. This type occurs in 3%. III) Ampullary type (Adult type): The right saccule grows more rapidly than the left and form a new apex, pushing the appendix medially, accounts for 90%. IV) Exaggerated type: The right saccule grows more than the left resulting in the exaggeration of the ampullary form. This type occurs in 4%.

The ileum opens into the posteromedial aspect of the large intestine at the junction of caecum and ascending colon via the ileocaecal orifice. The ileocaecal valve has upper and lower flaps. The flaps (labia) fused with each other at their ends to form frenula of the valve. Either of the frenulum may be absent [2]. The shape of the ileocaecal orifice is commonly either a slit or oval and its diameter is about 2.5cm. The appendicular orifice is situated about 2cm below the ileocaecal orifice.

Familiarity with wide range of normal size, shape and location of the ileocaecal valve is necessary to arrive at correct radiological diagnosis. This study hopefully will be of help for a surgeon to acclimatize to the anatomical landmark of the ileocaecal region.

MATERIALS AND METHODS

The 100 specimens for this present study were obtained from the embalmed cadavers Of Anatomy Department, K.A.P.V. Government medical college, Trichy, during the period of study. The abdominal cavity was opened and the small intestine along with mesentery pushed medially. The shape of the caecum and its peritoneal relation were observed. The dimensions of caecum were measured. After applying ligatures around the ascending colon about 2.5cm above the ileocaecal junction and around the terminal ileum, 5 cm from the ileocecal junction, the caecum and appendix along with a portion of ileum removed. The lateral wall of caecum was incised; the shape & position of

ileocaecal valve, its dimensions and the distance between it and the appendicular orifice were observed and recorded.

RESULTS

The average length of the caecum was 4.8 cm (range 2-7cm). The average breadth of the caecum was 5.6cm (ranged from 4.5 - 7 cm). The shape of the caecum was of adult type in 97% of cases. Foetal type was seen in 3% of cases [Figure 1]. The caecum was entirely covered by peritoneum in 75% of cases, found to be fused with the posterior abdominal wall in 10% of cases, in 2% cases caecum was attached obliquely, in 13% of cases it was attached in a concave line [Table 1].

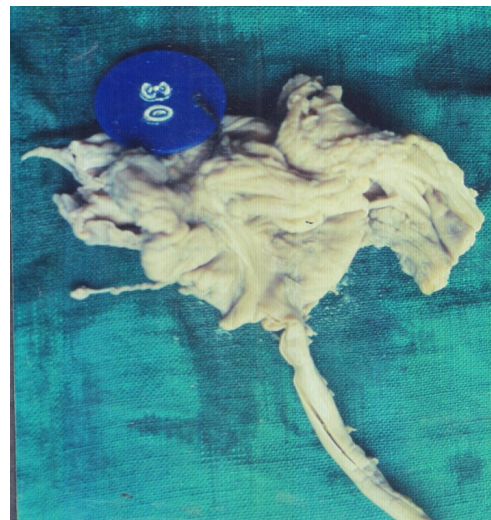Table 1: Shape and peritoneal attachment of Caecum

Shape	Percentage	Peritoneal attachment to posterior abdominal wall	Percentage
Type I (foetal)	3%	Unattached	75%
Type II (infantile)	---	Fused	10%
Type III (adult)	97%	Oblique	2%
Type IV (exaggerated)	--	Concave line	13%

Table 2: Pattern of ileocaecal opening & shape of the ileocaecal valve.

Pattern of ileocaecal opening	Percentage	Shape of the ileocaecal valve	Percentage
Posteromedially	58%	Slit	49%,
Medially	26%	Papilla	35%
Posteriorly	10%	Oval	16%.
Anteromedially	6%	---	---

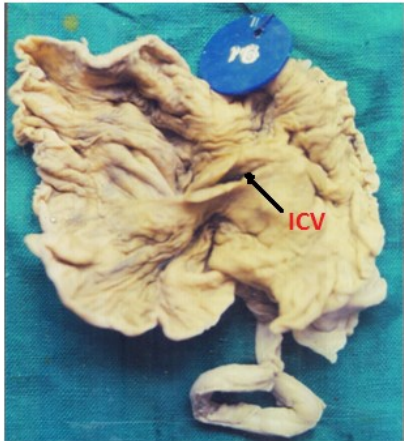
Fig. 1: Foetal type of Caecum.



ileum entered into the caecum posteromedially in 58%, medially in 26%, posteriorly in 10% and anteromedially in 6% of cases [Figure 2]. The shape of the ileocaecal valve was slit like in 49% [figure 3], papilla like in 35% [figure 4], and oval in 16% [Table 2]. The height of the upper labia

ranged from 0.5-2.5 cm. The average height was 1.03cm. Height of the lower labia varied from 0.5cm to 1cm, the average height was 0.74cm. The diameter of the ileo caecal orifice ranged from 1.1 to 2.5cm. The medial frenulum absent in 15%, lateral frenulum absent in 2%, both frenula absent in 1% of cases. The distance between the ileocaecal orifice and appendicular orifice ranged from 1.7 – 5 cm.

Fig. 2: Opening of terminal ileum into antero medial aspect of the caecum.



ICV-Ileo caecal valve

Fig. 3: Slit like ileocaecal orifice.

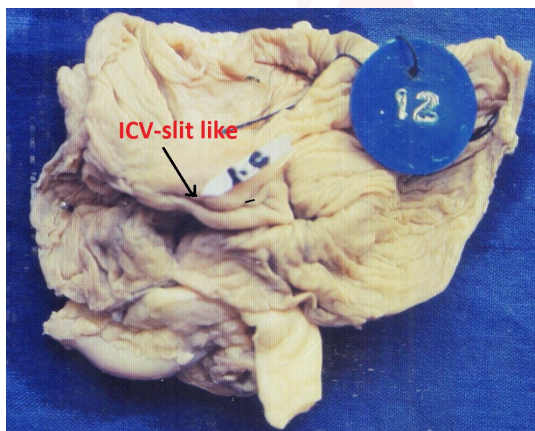
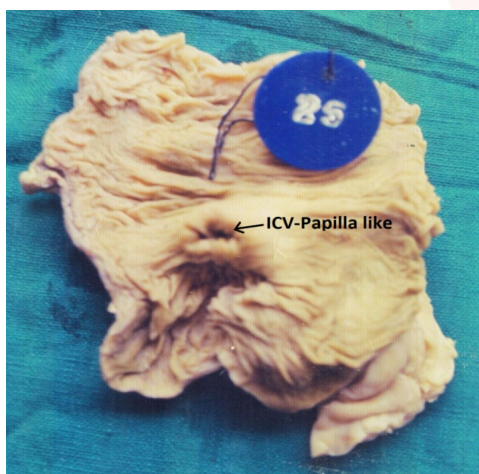


Fig. 4: Papilla like ileocaecal orifice.



ICV-Ileo caecal valve.

DISCUSSION

The caecum is greater in diameter than the rest of the colon & its wall is thinner. Because of its distensible nature and sac like morphology, it is more prone for rupture in cases of increased intra colic pressure as in intestinal obstruction [1].

Treves (1885), Berry's (1895) studied about the morphology of the caecum and reported that the average length was 6cm and the breadth was 7.5cm [3, 4]. Romanes (2007) described the length and breadth to be 5-7cm [5]. Shilpa Naik, Sangeetha.M(2017) reported the mean length of the caecum was 4.7 ± 0.42 cm & breadth was 5.69 ± 2.8 cm [6]. In the present study, the average length of the caecum was 4.8cm (range 2-7cm). The average breadth of the caecum was 5.6cm (range 4.5 -7 cm).

Normally in adults, the shape of the caecum is ampullary (adult type). Treves (1895)[3], Pavlov and Petrov (1968)[7], Vidya CS(2016)[8] reported that the common type of caecum was adult type, seen in majority of cases. According to Amrita Nidhi, the shape of the caecum in younger foetuses is conical, in older foetuses it is quadrangular or right saccular [9]. In our study foetal type was found in 3% and adult type in 97%. The quadrate type and the exaggerated type were not found.

The caecal bud appears as a small conical dilatation in the caudal limb of midgut at 5th week of intrauterine life. On midgut rotation, caecum is the last part to reenter the abdominal cavity. Its distal end forms a narrow diverticulum, the appendix [1]. Due to the differential growth of caecum, its shape and position of appendix vary. The reasons for the different shape of the caecum include the presence of content and internal pressure of caecum, the effect of gravity in relation to the two footed position adopted by the human beings [10,11,12].

The caecum is usually covered by peritoneum, but it may be incomplete[1]. Wolfer et al (1942) reported the caecum fused to posterior parietes in 5.6%, adherent over a 3rd of its posterior surface in 11.2 %, and no membranous attachment in the remainder[13]. Treves noted that the caecum completely covered by peritoneum in

94% of cases[3].

In the present study, the caecum was completely covered by peritoneum in 75% of cases, fused to posterior abdominal wall in 10%, line of attachment was oblique in 2% and it was in concave line in 13% of cases.

As the caecum is enveloped entirely by peritoneum, it may have considerable mobility. Due to this, a polyp may be misinterpreted as stool on CT colonography [14]. To a variable degree caecum may possess a mesentery and may rotate around it, resulting in caecal volvulus [1].

Caecal volvulus accounts for 2% cases of bowel obstruction and 11% cases of intestinal volvulus. A variant of caecal volvulus is known as caecal bascule, caused by rotational torsion of caecum along its own axis[15]. When the peritoneum is attached along a concave line, it may enclose retrocaecal recess which is the common location of appendix[2]. Hence awareness of variant anatomy of this region is useful in making correct diagnosis.

Normally the ileum opens into posteromedial aspect of the large intestine at the junction of caecum and ascending colon. Fleischner and Bernstein (1950) reported that the ileum mostly entered the colon posteromedially but may open medially or posteriorly[16]. In our study the ileum entered the colon posteromedially in 58%, medially in 26%, posteriorly in 10% and anteromedially in 6% of cases.

The ileocaecal valve has two flaps. Buirge (1943) reported the height of upper flap of the ileocaecal valve varied from 0.4 to 2.5 cm with an average of 1.5 cm and that of the lower fold, averaging only 0.6 cm. He found the medial frenulum to be absent in 22%, the lateral one in 2% and both in 2% of cases [17]. According to Shilpa Naik and Sangeeta.M (2017) the length of the upper flap ranged from 1.2 -2.2 cm and that of the lower flap varied from 1.5 to 3.5 cm. The diameter of ileocaecal orifice ranged from 0.5 to 1.6 cm[6].

In our study the height of the upper flap measured 0.5 to 2.5 cm with the average of 1.03 cm and the lower flap measured 0.5 to 1 cm with the average of 0.74 cm. and the diameter of ileocaecal orifice ranged from 1.1 to 2.5 cm. The medial frenulum was absent in 15% the lateral

frenulum in 2% and both in 1%.

The shape of ileocaecal orifice is either slit or oval [1]. Wakefield and Friedell (1941) found that the intracaecal tension makes the frenula taut and leading to slit-like ostium [18]. Endoscopically ileocaecal valve classified into slit, papillary, lipomatous types[14]. In our study the ostium was slit-like in 49%, papillary in shape in 35% and oval in 16% of cases.

The anatomical factors which predispose to intussusception of caecum include anterior insertion of the terminal ileum with respect to the caecum, decreased rigidity of the caecum, papillary arrangement of the ileocaecal valve, and participation of the longitudinal muscle fibers of the colon in the constitution of the valve [19]. Hence these factors should be borne in mind while treating the cases of intussusception.

The appendicular orifice is situated about 2 cm below the ileocaecal orifice. Berry reported that the distance between ileocaecal orifice and appendicular orifice was 1.7 cm [4], according to Shilpa Naik, Sangeetha M the distance ranged from 1.5 – 5 cm.[6]. In the present study the distance between appendicular and ileocaecal orifices ranged from 1.7 to 5 cm.

The identifiable landmarks in caecum are ileocaecal valve and appendicular orifice during colonoscopy. Bow and arrow sign is an endoscopic sign in which the curve of appendicular orifice is used to point towards the direction of ileocaecal valve, as if it were a bow guiding an arrow. The colonoscope can be passed in this direction to enter the terminal ileum. The identification of ileocaecal valve in colonoscopy indicates complete visualization of colon[20].

CONCLUSION

The diagnosis of diseases involving the caecum, appendix and ileocaecal valve can be challenging, even with advent of advanced radioimaging technology. Familiarity of morphological variations of this region is necessary to make correct diagnosis and to perform surgical procedures like urinary bladder reconstruction with ileocaecal segment in bladder diseases and ileocaecal anastomosis along with ileocaecal valve reconstruction in cases of terminal ileal

lesions. Our study which highlighted the anatomical variations in the ileocaecal region will be helpful to surgeons who perform advanced, complex surgical procedures in this region.

Conflicts of Interests: None

REFERENCES

- [1]. Susan Standring, Grey's Anatomy- the anatomical basis of clinical practice. 40th edition. London: Elsevier Churchill Livingstone; 2008;1141-1142.
- [2]. Hollinshead, W.H. Anatomy for surgeons Vol 2. 2nd ed. Hagerstown, M.D. Harper & Row, 1971. 280 – 283, 480-491.
- [3]. Treves F. Lecture on the anatomy of the intestinal canal and peritoneum in man. Brit. M. J. Lecture I, 1 : 415; Lecture II, 1: 470; Lecture III, 1: 527, 580.
- [4]. Berry, R.J.A. The anatomy of vermiform appendix, Anat. Anz 1895b;10:761.
- [5]. G.J. Romanes. Cunninghams Manual of Practical Anatomy Volume 2. 15th edition. New York: Oxford University Press; 2007;141-142.
- [6]. Shilpa Naik, Sangeetha.M. Anatomical variations of Caecum and Appendix: A Cadaveric study. Int J Anat Res 2017;5(3.1):4036-39.
- [7]. Pavlov S, Perov V. surl'anse sous clavier deroite retro Oesophageenne Folia med plovdiv 1968;10:73-78.
- [8]. Vidya CS. Anatomical variations of caecum and appendix: A cadaveric study in Mysore based population. Indian Journal of Clinical Anatomy and Physiology 2016;3(3):262-265.
- [9]. Amritha Nidhi, et al. Morphology of Caecum in Human Fetuses at Different Gestational ages. International Journal of Contemporary Medical Research. 2018;5(4): D1-D5.
- [10]. Smith, GM. A statistical review of the variations in the anatomic positions of the caecum and processus vermiformis in the infant. Anatomy Record. 1911;5:549-556.
- [11]. Wakeley CPG. The position of vermiform appendix as ascertained by an analysis of 10,000 cases. J Anat. 1933;67:277-283.
- [12]. Garis, C F. Topography and development of Caecum and appendix. Annals of Surgery. 1941;113:540-548.
- [13]. Wolfer J.A. Beatson, L.E., and Anson. B.J. Volvulus of the cecum Anatomical factors in its etiology; report of a case. Surg., Gynaec. & Obst 1942;74:882.
- [14]. Alvin C. Silva et al. Spectrum of normal and abnormal CT appearances of the ileocaecal valve and caecum with endoscopic and surgical correlation. Radio Graphics. <https://doi.org/10.1148/rg.274065164>.
- [15]. Carol E.H. Scott – Conner. Essential operative technique and anatomy. 4th edition. 2014: 508-511, 527-528.
- [16]. Fleischner, F.G., and Bernstein, C. Roentgen anatomical studies of the normal Ileocecal valve: Radiology. 1950;54:43-58.
- [17]. Buirge R.E, Dennis C, Vardo R I; et al, Histology of Experimental appendiceal obstruction (rabbit, ape, man). Arch Pathol 1940;30:481-503.
- [18]. Wakefield E.G and Friedell M.T. the structured significance of the ileocecal Valve J.A.M.A 1941;116:1889.
- [19]. Susan M. Cera. Intestinal intussusception. Clinics in Colon and Rectal Surgeries. 2008: May; 21(2):106-113.
- [20]. Cotton PB, Williams CB, Practical gastrointestinal endoscopy, London: Blackwell publishers. 1996;116-160.

How to cite this article:

P.S. Chitra, S. Kalaiyarasi. A STUDY ON THE MORPHOLOGY OF ILEO-CAECAL REGION AND ITS CLINICAL CORRELATIONS. Int J Anat Res 2018;6(4.3):5978-5982. DOI: 10.16965/ijar.2018.389