

# ANATOMIC STUDY OF THE CORACOID PROCESS: SAFETY MARGIN FOR OSTEOTOMY FOR SHOULDER SURGERY

Ayman Ahmed Khanfour <sup>1</sup>, Nehal Mohamed Nabil <sup>\*2</sup>, Bahaa Ahmed Motawea <sup>3</sup>.

<sup>1</sup> Anatomy and Embryology department, Faculty of Medicine, Alexandria University, Alexandria, Egypt.

<sup>\*2</sup> Anatomy and Embryology department, Faculty of Medicine, Alexandria University, Alexandria, Egypt.

<sup>3</sup> Orthopedic Surgery department, Faculty of Medicine, Alexandria University, Alexandria, Egypt.

## ABSTRACT

**Background:** Surgical procedures as coracoid osteotomy, transfer, and fixation are used for management of recurrent anterior shoulder instability. However, the peculiar anatomy of bony and soft tissue footprints of the coracoid, as they relate to these surgical procedures, need further detailed studies owing to its clinical importance.

**Aim of the work:** to obtain safety margin for osteotomy of the coracoid process.


**Materials and methods:** The material of this work included twenty upper limbs of formalin preserved specimens obtained from the dissecting room of anatomy department, faculty of medicine, Alexandria University. Dimensions of the coracoid process were recorded. Anatomical measurements between the tip of the coracoid process to the anterior and posterior margins of the tendon of pectoralis minor were recorded. Distances between the tip of the coracoid process and the anterior and posterior margins of coracoacromial ligament, coracohumeral ligament, and the most distal point of conoid and trapezoid ligaments were recorded.

**Results:** The mean length, width, and height of the coracoid were 4.25, 1.4, 1.16 cm respectively. The mean distance between the tip of the coracoid process to the anterior and posterior margins of pectoralis minor were 1.07 and 2.04 cm respectively. The mean distance between tip of coracoid process and coracoacromial ligament (anterior and posterior margins), coracohumeral, conoid and trapezoid ligaments were 1.32, 2.19, 1.11, 3.70 and 2.73 cm respectively.

**Conclusion:** A safety margin of 2.35 cm from the tip of the coracoid process is recommended to avoid injury of coracoclavicular ligament. This distance was correlated with the distance between the tip and the posterior margin of pectoralis minor muscle.

**KEY WORDS:** Coracoid process, Coracoclavicular ligament, Coracoid osteotomy.

**Address for Correspondence:** Nehal Mohamed Nabil, Anatomy and Embryology department, Faculty of Medicine, Alexandria University, Alexandria, Egypt. **E-Mail:** [nehalnabil895@gmail.com](mailto:nehalnabil895@gmail.com)

Access this Article online	Journal Information
<b>Quick Response code</b>  DOI: 10.16965/ijar.2018.397	<b>International Journal of Anatomy and Research</b> ICV for 2016 90.30 ISSN (E) 2321-4287   ISSN (P) 2321-8967 <a href="https://www.ijmhr.org/ijar.htm">https://www.ijmhr.org/ijar.htm</a> DOI-Prefix: <a href="https://dx.doi.org/10.16965/ijar">https://dx.doi.org/10.16965/ijar</a> 
Article Information	
Received: 30 Sep 2018 Peer Review: 01 Oct 2018 Revised: None	Accepted: 01 Nov 2018 Published (O): 05 Dec 2018 Published (P): 05 Dec 2018

## INTRODUCTION

The characteristic anatomical features of the shoulder joint makes it susceptible to various diseases, including instability and dislocation. During management of glenohumeral bone loss,

intervention and procedures as bone block with modifications play an important role as treatment options in such cases [1].

Coracoid process of the scapula has a significant importance in shoulder biomechanics,

being the site of attachment of important muscles and ligaments around the shoulder joint. It is also determined as a bone tunnel in operations for management of acromioclavicular dislocations [2, 3].

The coracoid process is a hook-shaped bone projecting superiorly, anteriorly and laterally. It is referred as the “lighthouse of the shoulder” as it is a very important anatomical landmark for the nearby brachial plexus and the axillary vessels during surgical procedures [4].

The Latarjet and Bristow procedures are used for management of recurrent anterior shoulder instability in cases of significant bony defect [5]. In coracoid osteotomy, the deltopectoral approach is now recommended as it gives a safer and wider access to the surgeon than the posterior approach; however, there is a debate in the literature on the appropriate level and location of coracoid process osteotomy that does not compromise the coracoclavicular ligament; this ligament is crucial for shoulder stability. Such a standardized osteotomy level is referred as a safety margin [6,7].

The peculiar bony anatomy and soft tissue footprints of the coracoid, as they relate to coracoid transfer procedures, need further detailed study owing to their clinical importance.

**AIM:** The aim of this work was to obtain safety margin for osteotomy of the coracoid process.

## MATERIALS AND METHODS

The material of this work included twenty upper limbs of formalin preserved specimens obtained from the dissecting room of anatomy department, faculty of medicine, Alexandria University. Specimens with scars about the shoulder were excluded to ensure the determination of proper measurements.

The coracoid process was determined with palpation. An incision was done in the deltopectoral groove (Fig. 1). The skin, subcutaneous tissue, deltoid and overlying soft tissue were removed, exposing the coracoid process, lateral clavicle and acromion process. With more dissection we exposed the trapezoid and conoid ligaments. Also identification of the tendon of pectoralis minor was done as a landmark in addition to exposure of the coracoacromial

arch and coracohumeral ligaments (Fig. 2).

The length of the coracoid process and its width and height at the tip were recorded. Length was measured in the long axis from tip (the distal point) to base (where the superior surface orientation changes from horizontal to vertical). In addition, the following parameters were recorded: the distances between the tip and the following anatomical landmarks: anterior and posterior margins of pectoralis minor, anterior and posterior margins of coracoacromial ligament, coracohumeral ligament, and the distal point of conoid and trapezoid ligaments. Different parameters were measured using non-digital Vernier caliper, accurate up to 0.1 mm (Fig. 3). All measurements were taken twice and the reported value is the average of the two measurements.

The safety margin in our study was the distance between the tip of the coracoid process to the distal point of the trapezoid ligament (TTL). We correlated this safety margin with another measurement which is the distance between the tip of coracoid process to the posterior margin of pectoralis minor muscle (TPMp), which could be accessed easily during surgery.

Linear regression was performed to predict the value of the TTL distance as a function of the TPMp distance; accordingly, the safety margin was estimated.

Values were expressed as means, standard deviations. A level of statistical significance was established at  $P < .05\%$ . Statistical analysis was performed using SPSS version 19.

## RESULTS

By dissection of twenty upper limbs of formalin preserved specimens, the following anatomical measurements were obtained:

**Dimensions of the coracoid process:** The average length of the coracoid process was  $4.25 \pm 0.62$  cm. The width and height at the tip were  $1.4 \pm 0.18$  cm and  $1.16 \pm 0.19$  cm respectively (Chart 1; Table 1; Fig. 3).

**Measurements between the tip of the coracoid process to pectoralis minor attachment:** The mean distance between the tip of the coracoid process to the anterior margin of pectoralis minor at its site of insertion was

1.07± 0.24 cm and that to its posterior margin was 2.04±0.27cm (Table 2; Fig.4)

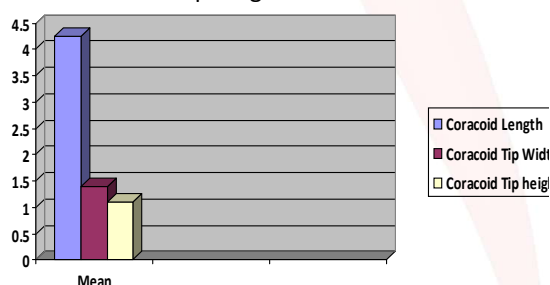
**Measurements between the tip of the coracoid process to other ligaments:** The mean distance between the tip of the coracoid process to the anterior margin of the coracoacromial ligament was 1.32±0.36 cm while that to the posterior margin was 2.19±0.38 cm.

The mean distance between the tip of the coracoid process to the coracohumeral ligament was 1.11±0.91cm.

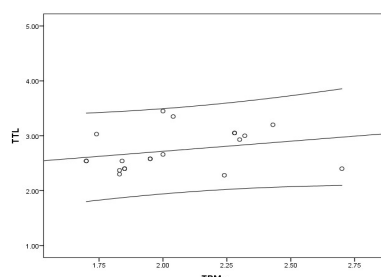
The mean distances between the tip of the coracoid process to the distal point of trapezoid and conoid ligaments were 2.73±0.36 cm and 3.70±0.49cm respectively (Table 2; Fig. 5-8).

The safety margin (the distance between the tip of the coracoid process to the distal point of the trapezoid ligament) was correlated with the posterior margin of pectoralis minor. According to the performed linear regression model, it was found that if the average distance of the TPMp was 2.04 cm, the average distance of TTL (safety margin) will be 2.35 cm. It was found also that for every 1 cm increase in the distance of TPMp, a constant value of 0.37 cm increase was obtained for the TTL (this is the coefficient of the TPMp measure), for the coracoid osteotomy (Graph 1; Table 3).

**Chart 1:** The mean measurements of the coracoid length, width and coracoid tip height in cm.



**Graph 1:** Linear regression graph according to TTL and TPMp.

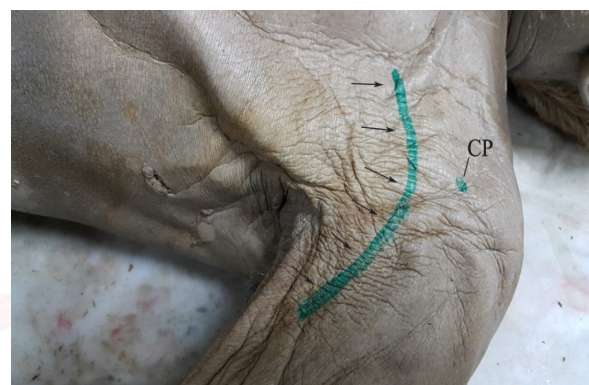

**TTL:** Tip of coracoid process to the distal point of trapezoid ligament

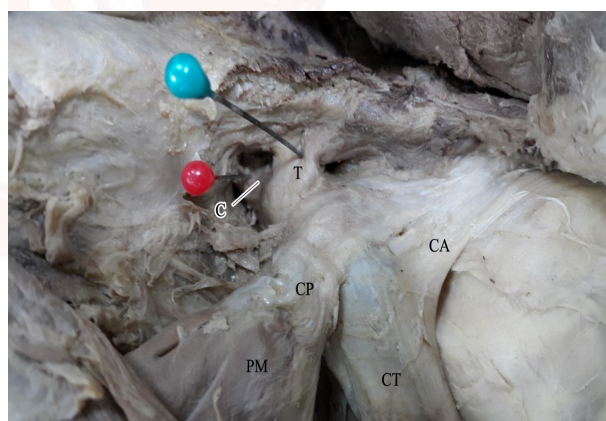
**TPMp:** Tip of coracoid process to posterior margin of pectoralis minor

**Variation at the site of insertion of pectoralis minor:** Out of the twenty specimens there was extension of the insertion of pectoralis minor in one specimen (5%). It was partially attached to coracoid process then its tendon passed deep to coracoacromial arch and blended with supraspinatus muscle (Fig. 9).

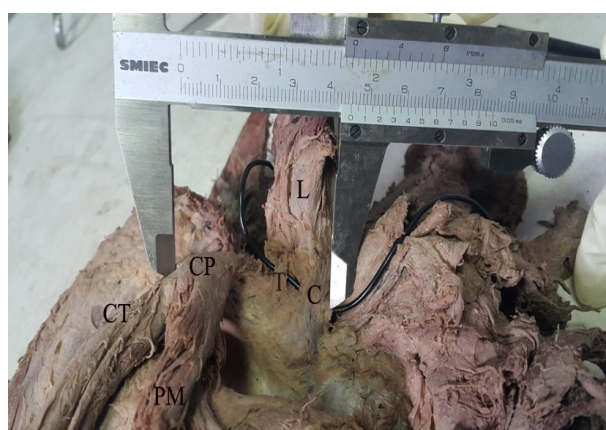**Fig. 1:** A photograph for the left shoulder region showing the site of palpation of the coracoid process (CP) and the line of incision at the deltopectoral groove (arrows).



**Fig. 2:** A photograph of left shoulder region showing coracoid process (CP); trapezoid ligament (T) (blue pin); conoid ligament (C) (red pin); pectoralis minor (PM); coracoacromial arch (CA); conjoint tendon (CT).

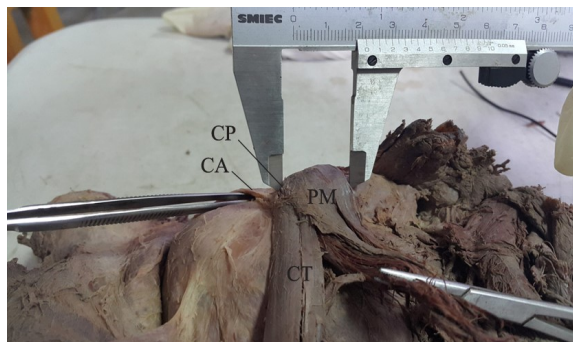


**Fig. 3:** A photograph of a right sided specimen showing the length of the coracoid process (CP) measured by vernier caliper. CP: Tip of coracoid process; CT: conjoint tendon; C: conoid ligament; T: trapezoid ligament; L: clavicle - PM: pectoralis minor).



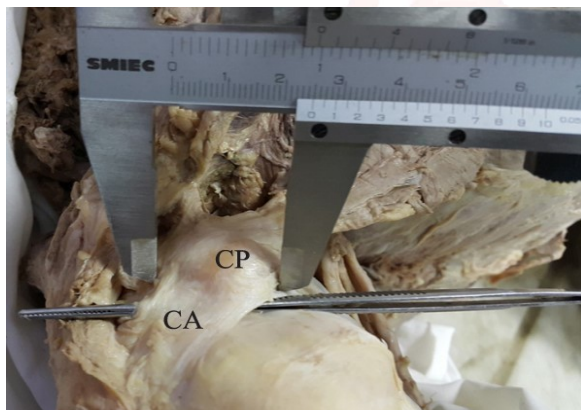


**Fig. 4:** A photograph of right shoulder region showing the distance between the tip of coracoid process (CP) to the posterior margin of pectoralis minor (PM).

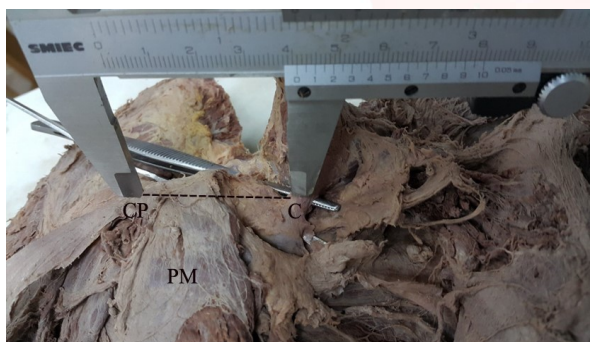


(CT: conjoint tendon - CA: coracoacromial arch).

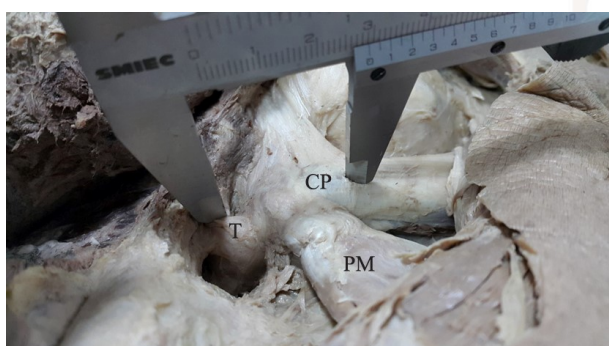
**Fig. 5:** A photograph of right shoulder region showing the distance between the tip of coracoid process (CP) to the posterior margin of coracoacromial arch (CA).



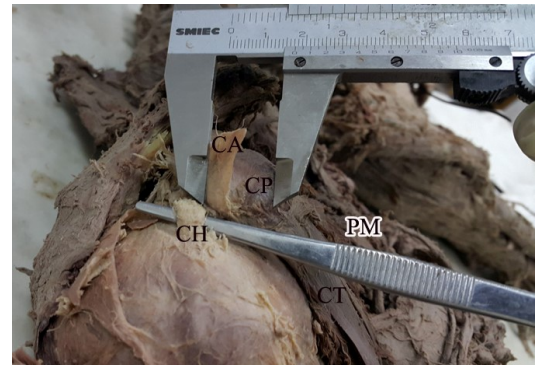
**Fig. 6:** A photograph of right shoulder region showing the distance between the tip of coracoid process (CP) to the distal point of conoid ligament (C). (PM: pectoralis minor).



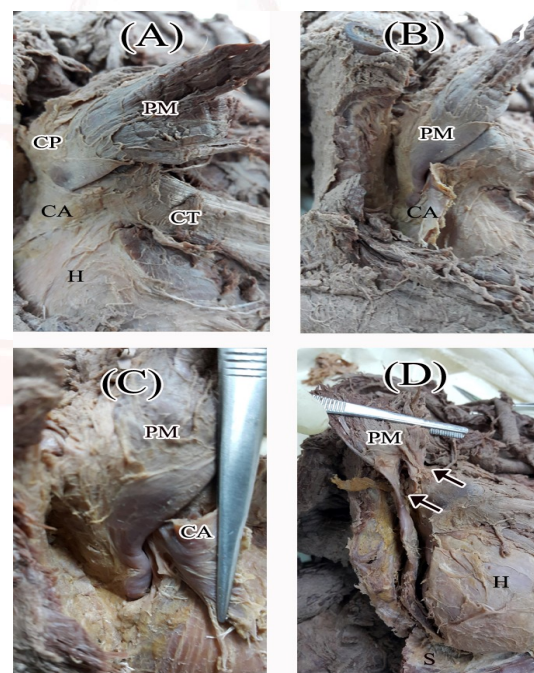
**Fig. 7:** A photograph of left shoulder region showing the distance between the tip of coracoid process (CP) to the distal point of trapezoid ligament (T). (PM: pectoralis minor).



**Fig. 8:** A photograph of right shoulder region showing the distance between the tip of the coracoid process (CP) to the coracohumeral ligament (CH). (PM: pectoralis minor – CT: conjoint tendon – CA: coracoacromial arch which is cut and reflected).

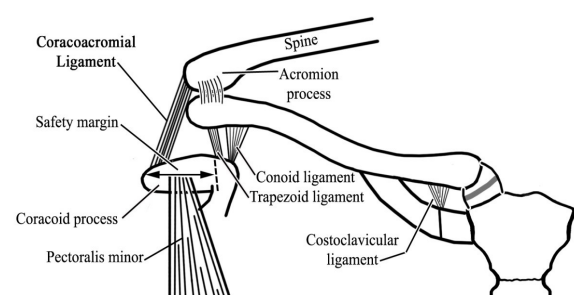


**Fig. 9:** A photograph of right shoulder region showing an anatomical variation in the insertion of pectoralis minor muscle [PM]. It is partially attached to coracoid process [CP] (A); then its tendon passes deep to coracoacromial arch (B). The arch is cut to expose the pectoralis minor tendon (C). The tendon of pectoralis minor blends with supraspinatus muscle [S] (D).



CT: conjoint tendon – CA: coracoacromial arch – H: head of humerus – Upper arrow: partial insertion of pectoralis minor into coracoid process - Lower arrow: blending of the tendon of pectoralis minor with supraspinatus).

**Fig. 10:** Showing the safety margin for coracoid osteotomy.



**Table 1:** Shows the measurements (cm) of the coracoid length, width and coracoid tip height.

Variable	Mean (cm)	Std. Deviation (cm)	Minimum (cm)	Maximum (cm)
Coracoid Length	4.25	0.62	3	5.05
Coracoid Tip Width	1.4	0.18	1.08	1.65
Coracoid Tip Height	1.16	0.19	0.7	1.46

**Table 2:** Shows the distances between tip of coracoid process and the surrounding structures

Variable	Mean (cm)	Std. Deviation (cm)	Minimum (cm)	Maximum (cm)
TPMa	1.07	0.24	0.62	1.5
TPMp	2.04	0.27	1.7	2.7
TCAa	1.32	0.36	0.77	2.2
TCaP	2.19	0.38	1.53	2.76
TCHL	1.11	0.91	0	2.46
TTL	2.73	0.36	2.28	3.45
TCL	3.7	0.49	2.6	4.61

**TPMa:** Tip of coracoid process to anterior margin of pectoralis minor

**TPMp:** Tip of coracoid process to posterior margin of pectoralis minor

**TCAa:** Tip of coracoid process to anterior margin of coracoacromial ligament

**TCaP:** Tip of coracoid process to posterior margin of coracoacromial ligament

**TCHL:** Tip of coracoid process to coracohumeral ligament

**TTL:** Tip to the distal point of trapezoid ligament

**TCL:** Tip to the distal point of conoid ligament

**Table 3:** Variables used for Linear Regression.

Factor	Coefficients	Std. Error	R <sup>2</sup>	t	.Sig
Constant	1.981	0.621	0.274	3.192	0.005
TPMp	0.37	0.301		1.22	0.238

Dependent Variable: TTL (Tip to the distal point of trapezoid ligament)

TPMp: Tip of coracoid process to posterior margin of pectoralis minor

## DISCUSSION

The average amount of bone available for use in coracoid transfer is considerably dependent on the attachment of the surrounding soft structures. Moreover, incidence of coracoid fracture and pull out of implants intraoperatively depends on the morphometric measurements of coracoid process. The incision level for coracoid osteotomy is a subject of debate varying from one to three cm from the tip of the coracoid process; it could be also referred to an anatomical landmark such as the posterior margin of pectoralis minor tendon [8-11].

Terra et al. conducted an anatomic study of the coracoid process to determine its dimensions.

They reported a mean length, width, and height of the coracoid of  $4.26 \pm 0.26$  cm,  $2.11 \pm 0.2$  cm, and  $1.49 \pm 0.12$  cm respectively [1]. Dolan reported a value for coracoid length, tip width, and tip height of 4.56, 1.83 and 1.15 cm respectively [5].

The previous measurements are in agree with the present study; they just give an idea as regards the gross anatomy of the coracoid process, to be correlated with its soft tissue footprints which are manipulated during surgery. However, study of the morphometry of these soft tissue footprints is essential for coracoid process fixation procedures to avoid injury of important structures as coracoclavicular ligament which will affect shoulder stability.

Terra et al. established a safety margin of 2.64 cm for the osteotomy of the coracoid process which was correlated with surgical procedures for coracoid transfer in the Latarjet-Patte surgery, where 2 screws are used for coracoid fixation [1].

A previous study also concluded that osteotomies of 3.0 cm can injure the trapezoid ligament [11].

Sella et al. conducted another tool using computed tomography for evaluation of coracoid process in treatment of acromioclavicular dislocations; reconstruction of the coracoclavicular ligament was performed using transosseous tunnels in the coracoid process. Measurements were done to determine the convergence point between the clavicle and the coracoid process; it was about 2.9 cm [3].

In the present study the mean of TPMp was 2.04cm and the mean of TTL was 2.73 cm. Because of inter-individual variations, a linear regression model was conducted to correlate TTL to TPMp statistically. According to the results of the linear regression model, it was found that if the average distance of TPMp was 2.04, the average distance of TTL (safety margin) will be 2.35 cm. It was also found that for every 1 cm increase in the distance of TPMp, a constant value of 0.37 cm increase was obtained for the TTL (safety margin) (Fig. 10).

Knowing the safety margin allows the surgeon to perform a safe osteotomy without direct visualization of the coracoclavicular ligaments'



attachments, thereby making procedures safer. Consequences of injury to the coracoclavicular ligament and the consequent morbidity were reported before [12-15], but future researches may provide the consequences and clinical implications of manipulating other structures (e.g., the pectoralis minor, coracohumeral ligament, and coracoacromial) in the transfer procedures of the coracoid process.

Variations in the attachment of pectoralis minor were reported in previous literatures [16-18]. Orientation with these ectopic attachments is important clinically, as it has its implications especially for plastic surgeons because the muscle is frequently used for free flaps. Moreover, precise knowledge of its attachment is crucial for orthopedic surgeons to manage restricted movements of shoulder joint. Lim et al. reported tendinous extension of the pectoralis minor tendon reaching supraspinatus tendon as 11% prevalence, and it was preoperatively detected on MRI [16]. Tubbs and Salter reported an unusual bony attachment of pectoralis minor in an adult cadaver where the left pectoralis minor had no attachment to the coracoid process of scapula, but attached directly to fibrous capsule of the glenohumeral joint [18]. Gregory et al. described a case of shoulder stiffness, in which an ectopic insertion of pectoralis minor over supraspinatus tendon was found; in such case complete restoration of external rotation movement was obtained after release of pectoralis minor from the supraspinatus [19].

Lee et al. concluded that patients with ectopic insertion of pectoralis minor tendon show a high tendency for fibrotic scar tissue proliferation in the rotator interval. This variation could be the cause of pain during certain shoulder movements as a result of neurovascular compression, and may alter the dynamics of the shoulder [20].

Concerning the present work, pectoralis minor tendon showed extension of its insertion deep to coracoacromial arch blending with supraspinatus muscle in (5%) of the cases. Depending on these findings, it is recommended to do MRI preoperatively before arthroscopic rotator cuff repair as the presence of such variation could affect supraspinatus tendon mobilization.

## CONCLUSION

Knowledge and orientation of the different anatomical structures and their distances from the tip of the coracoid process is crucial for osteotomies that use coracoid graft, transfer, or fixation. A safety margin of 2.35 cm from the tip of the coracoid process is recommended to perform a safe osteotomy in order to avoid injury of coracoclavicular ligament. This distance was correlated with the attachment of posterior border of pectoralis minor tendon.

**Conflicts of Interests: None**

## REFERENCES

- [1]. Terra BB, Eijnisman B, de Figueiredo EA, Cohen C, Monteiro GC, de Castro Pochini A, Andreoli CV, Cohen M. Anatomic study of the coracoid process: safety margin and practical implications. *Arthroscopy* 2013; 29 (1):25-30.
- [2]. Fathi M, Hussin P, Nizlan N M, See C P, Ahmad U, San A A, AbdulRahim E, Othman F. Easy, fast and accessible dissecting approach to coracoid process of human scapula. *Research Journal of Pharmaceutical, Biological and Chemical Sciences* 2015; 6 (2):1279- 1283.
- [3]. Sella GDV, Miyazaki AN, Nico MAC, Filho GH, Silva LA, Checchia SL. Study on the anatomic relationship between the clavicle and the coracoid process using computed tomography scans of the shoulder. *Journal of shoulder and elbow surgery* 2017; 26(10):1740-1747.
- [4]. Mohammed H, Skalski MR, Patel DB, Tomasian A, Schein AJ, White EA, Hatch GF 3rd, Matcuk GR Jr. Coracoid Process: The Lighthouse of the Shoulder. *Radiographics* 2016; 36 (7):2084-2101
- [5]. Dolan CM, Hariri S, Hart ND, McAdams TR. An anatomic study of the coracoid process as it relates to bone transfer procedures. *J Shoulder Elbow Surg* 2011; 20(3):497-501
- [6]. Evensen C, Kalra K. Coracoid Process Transfer for Recurrent Instability of the Shoulder: A Critical Analysis Review. *JBJS Rev.* 2014; 18; 2 (2).
- [7]. Gökkuş K, Unal MB, Aydın AT. A Novel Surgical Approach to Coracoid-based Eosinophilic Granuloma and the Technical Trick. *Tech Hand Up Extrem Surg* 2016; 20(3):99-103.
- [8]. Lian J, Dong L, Zhao Y, Sun J, Zhang W, Gao C. Anatomical study of the coracoid process in Mongolian male cadavers using the Latarjet procedure. *Journal of Orthopaedic Surgery and Research* 2016; 11:126.
- [9]. Imma II, Nizlan NM, Ezamin AR, Yusoff S, Shukur MH. Coracoid Process Morphology using 3D-CT Imaging in a Malaysian Population. *Malays Orthop J.* 2017; 11(2): 30–35.

- [10]. Fathi M, Cheah P S, Ahmad U, Nizlan N M, San A A, AbdulRahim E, Hussin P, Mahmud R, Othman F. Anatomic Variation in Morphometry of Human Coracoid Process among Asian Population. *BioMed Research International*, vol. 2017, Article ID 6307019, 10 pages.
- [11]. Terra BB, de Figueiredo EA, Marczyk CSF, Monteiro GC, Pochini AC, Andreoli CV, Ejnisman B. Osteotomies of the coracoid process: an anatomical study. *Rev Bras Ortop* 2012; 47(3): 337–343.
- [12]. Harris RI, Wallace AL, Sonnabend DH, Harper GD, Goldberg JA, Jerome A., David H, William R W. Structural Properties of the Intact and the Reconstructed Coracoclavicular Ligament Complex. *Am J Sports Med* 2000; 28, (1): 103-108.
- [13]. Mazzocca AD, Santangelo SA, Johnson ST, Rios CG, Dumonski ML, Arciero RA. A biomechanical evaluation of an anatomical coracoclavicular ligament reconstruction. *Am J Sports Med* 2006; 34(2):236-246.
- [14]. Rios C A, Mazzocca AD. Anatomy of the clavicle and coracoid process for reconstruction of the coracoclavicular ligaments. *Am J Sports Med* 2007; 35:811-817.
- [15]. Boileau P O, Gastaud O, Brassart N, RoussanneY. All arthroscopic Weaver-Dunn-Chuinard procedure with double-button fixation for chronic acromioclavicular joint dislocation. *Arthroscopy* 2010; 26:149-160.
- [16]. Lim TK, Koh KH, Yoon YC, Park JH, Yoo JC. Pectoralis minor tendon in the rotator interval: arthroscopic, magnetic resonance imaging findings, and clinical significance. *J Shoulder Elbow Surg* 2015; 24 (6):848-853.
- [17]. Goldman E, Vasan C, Lopez-Cardona H, Vasan N. Unilateral ectopic insertion of the pectoralis minor: Clinical and functional significance. *Morphologie* 2016; 100 (328):41-44.
- [18]. Tubbs RS, Salter EG. Unusual attachment of the pectoralis minor muscle. *Clinical Anatomy* 2005; 18(4):302-304.
- [19]. Gregory MAC, Christophe T, Pascal B. Ectopic insertion of the pectoralis minor: implication in the arthroscopic treatment of shoulder stiffness. *Knee Surgery Sports Trauma Arthroscopy* 2008; 16:869-871.
- [20]. Lee CB, Choi SJ, Ahn JH, Ryu DS, Park MS, Jung SM, Shin DR. Ectopic insertion of the pectoralis minor tendon: interreader agreement and findings in the rotator interval on MRI. *Korean J Radiol* 2014; 15 (6):764-770.

#### How to cite this article:

Ayman Ahmed Khanfour, Nehal Mohamed Nabil Bahaa Ahmed Motawea. ANATOMIC STUDY OF THE CORACOID PROCESS: SAFETY MARGIN FOR OSTEOTOMY FOR SHOULDER SURGERY. *Int J Anat Res* 2018;6(4.3):6018-6024. DOI: 10.16965/ijar.2018.397