

CROSS SECTIONAL ANALYSIS OF OCCURRENCE OF ACCESSORY MANDIBULAR FORAMINA AND THEIR POSITIONAL VARIATIONS IN DRY MANDIBLES

Urvi H. Dave ¹, Sunita Gupta ², Rajesh B. Astik ^{*3}.

¹ Tutor, Department of Anatomy, GCS Medical College, Ahmedabad, Gujarat, India.

² Professor and Head, Department of Anatomy, AMC MET Medical College, Maninagar, Ahmedabad, Gujarat, India.

^{*3} Professor and Head, Department of Anatomy, GMERS Medical College, Himmatnagar, Gujarat, India.

ABSTRACT

Background: During lower jaw surgeries, inferior alveolar nerve block is given at mandibular foramen level. However, additional foramina are found on medial surface of ramus of mandible, through which branches of inferior alveolar nerve and vessels pass. Location of accessory foramina varies widely which could lead to iatrogenic injuries to neurovascular structures in this region.

Aim and objective: Precise information of variations in number of mandibular foramen and position of these accessory foramina relative to mandibular foramen help dental surgeons to avoid injuries to inferior alveolar nerve and vessels. Hence, this study aimed at analyzing position of accessory foramina osteologically in Gujarat's population.


Materials and Methods: Three hundred dry mandibles of unknown sexes, and bearing all teeth or intact alveolar margin were included in the study. Numerical variations in the form of accessory foramina were found in 42% of the mandibles; 17% on the right side; 17.66% on the left side; and in 7.33% mandibles accessory foramina were present on both sides. The laterality distribution of accessory mandibular foramina was found to be insignificant statistically. More number of accessory foramina was located antero-superior to mandibular foramen. Retromolar foramina were found in 15% mandibles; however, laterality distribution of retromolar foramina was statistically insignificant.

Conclusion: Iatrogenic injuries of inferior alveolar neurovascular structures could better be avoided with precise idea of position of accessory foramina, which may ease the work of dental surgeon.

KEY WORDS: Dry mandibles, Mandibular foramen, Anaesthesia, Anatomical variation.

Address for Correspondence: Dr. Rajesh B. Astik, Professor and Head, Department of Anatomy, GMERS Medical College, Near Government Polytechnic College, Gadhoda Road, Himmatnagar, Gujarat. 383001. India. Telephone: +91-9687336803; +91-9106387517

E-Mail: astikrajesh@yahoo.co.in

Access this Article online	Journal Information
Quick Response code  DOI: 10.16965/ijar.2018.398	International Journal of Anatomy and Research ICV for 2016 90.30 ISSN (E) 2321-4287 ISSN (P) 2321-8967 https://www.ijmhr.org/ijar.htm DOI-Prefix: https://dx.doi.org/10.16965/ijar 
	Article Information
	Received: 03 Oct 2018 Peer Review: 03 Oct 2018 Revised: None
	Accepted: 06 Dec 2018 Published (O): 05 Jan 2019 Published (P): 05 Jan 2019

INTRODUCTION

The mandibular foramen is bordered by lingula that could be palpated intra-orally, and forms

useful guide to locate mandibular foramen correctly. The inferior alveolar nerve and vessels enter the mandibular canal through mandibular

foramen. Within the canal, inferior alveolar nerve bifurcates into mental and incisive nerve; the later is supplying sensory fibers to lower anterior teeth and their associated gingivae via dental plexus. Inferior alveolar nerve block at the level of mandibular foramen is gold line maneuver in many dental and oral surgeries. Additional foramina are found on medial surface of ramus of mandible above or below mandibular foramen, which are usually associated with additional mandibular canals through which branches of inferior alveolar nerve and vessels pass. Presence of such accessory mandibular foramina would interfere to inferior alveolar nerve block [1].

As mandible is composed of dense cortical bone, infiltration nerve blocks at areas near apices of lower teeth are less effective than upper teeth. So, complete anaesthesia of lower teeth could be achieved by giving nerve block at mandibular foramen. Approximately four million nerve blocks are administered daily by dentists globally and failure of achieving effective nerve block could better be avoided with precise information of distribution of accessory mandibular foramen [2]. Though these foramina are described in literature, number and position are varied widely amongst race [3].

Occasionally accessory mandibular foramen found in the depression called retromolar fossa which is lying behind the last molar tooth. This accessory foramen may be terminal end of accessory mandibular canal which arises from mandibular canal and consists of neurovascular structures supplying the third molar. Varied frequency of occurrence of accessory mandibular foramina in retromolar fossa could be one of the reasons of failed inferior alveolar nerve block in extraction of third molar tooth [1].

MATERIALS AND METHODS

In this cross sectional study we included three hundred dry mandibles of unknown sexes, and bearing all teeth or intact alveolar margin. The source of the study material is anatomy departments of different medical colleges of the Gujarat. Exclusion criteria were set at mandibles without teeth or eroded alveolar margin. The bones were numbered serially. The number and position of accessory mandibular foramina, and

laterality distributions were noted on the medial aspect of the mandibular ramus. The significance of laterality distribution was evaluated by Chi-square test with significance for the analysis was set at the level of $p < 0.05$.

Fig. 1: Arrows show bilateral presence of accessory mandibular foramina.

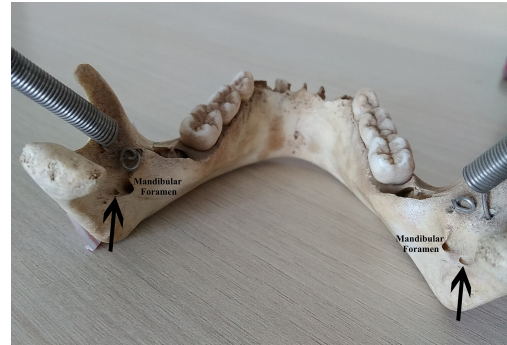


Fig. 2: More than three accessory mandibular foramina (circled).

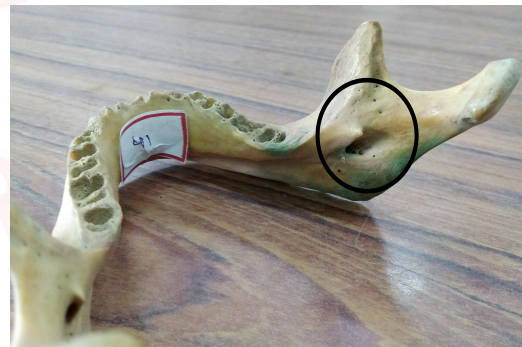

Fig. 3: Presence of accessory mandibular foramen within mandibular foramen.

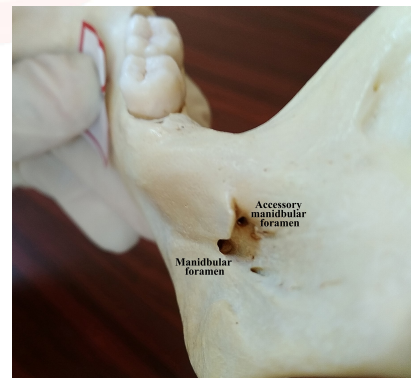


Fig. 4: Retromolar foramina present bilaterally.

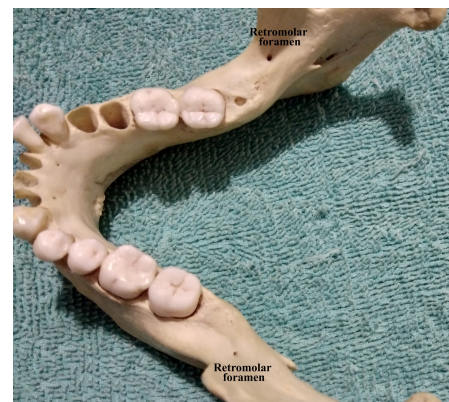


Fig. 5: Position of retromolar foramen is antero-superior to mandibular foramen.

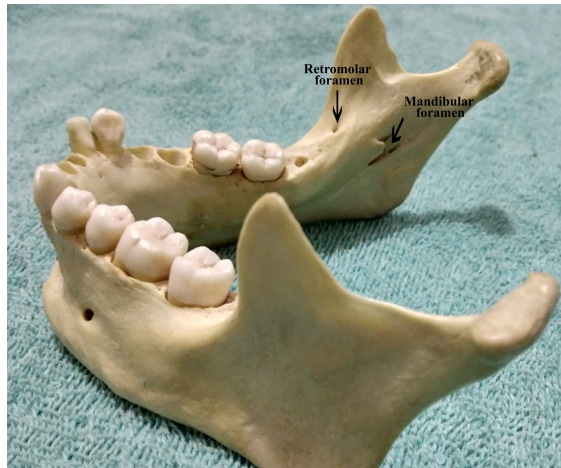


Table 1: Laterality distribution of accessory mandibular foramina (AMF).

AMF	Number of mandibles	Percentage (%)
On Right side	51	17
On Left side	53	17.66
Bilateral	22	7.33
Absent	174	58

Table 2: Number of accessory mandibular foramina in relation to each mandibular foramen.

No. of foramen	On Right side	Percentage (%)	On left side	Percentage (%)
1	30	10	33	11
2	25	8.33	18	6
3	12	4	15	5
More than 3	6	2	9	3

Table 3: Position of accessory mandibular foramina (AMF) in relation to mandibular foramen.

Position of AMF	Number of AMF On Right side	Number of AMF On Left side
Anterosuperior	74	80
Posterosuperior	61	62
Within mandibular foramen	5	8

We had found retromolar foramen in 45 (15%) mandibles studied; 24 on the right side; 18 on the left side, and bilateral retromolar foramina were found in 3 mandibles (Fig. 4). The positions of retromolar foramen were antero-superior to mandibular foramen (Fig. 5). On applying Chi-square test, p-value for laterality distribution of retromolar foramen was 0.152; showing laterality distribution was statistically insignificant.

DISCUSSION

The position of the mandibular foramen is usually midway between anterior and posterior

borders of ramus of the mandible at the level of occlusal surface of teeth, is used for administration of inferior alveolar nerve block in surgeries of lower teeth, gums and lower lip [4]. However, accessory mandibular foramina are commonly found in human mandibles above or below the mandibular foramen. These foramina are clinically important as branches of inferior alveolar nerve and vessels pass through them. [5]. The success rate of inferior alveolar nerve block lies on precise knowledge of accessory foramina and their position in relation to mandibular foramen [6].

In the present study, out of 300 mandibles, accessory mandibular foramina were found in 42% of mandible (Table 1); 17% on the right side, 17.66% on left side and in 7.33 mandibles on both sides (Fig. 1). The calculated p-value of 0.42 suggesting laterality distribution of AMF was insignificant statistically. The occurrence of accessory mandibular foramina in present study is in accordance with that in previous studies (Table 4) [7-9]. However, Ossenberg found higher incidence of occurrence of accessory mandibular foramina among Native Americans than European, Asian or Indian population [10].

Table 4: Incidence of presence of accessory mandibular foramina (AMF) in different studies.

AMF	Present study	Padmavathi [7]	Gupta S [8]	Freire [9]
Percentage of mandibles	42	41.50%	48%	43.24%
Unilateral	34.66	29.20%	30%	25.22%
Bilateral	7.33%	12.30%		18.02%

More than three accessory mandibular foramina were found in 15 mandibles studied (Fig. 2). Triple AMF were found in 27 mandibles; double AMF in 43 mandibles and single AMF were found in 63 mandibles studied (Table 2). Samanta found single accessory mandibular foramina in 10% and double accessory mandibular foramina in 6.66% mandibles studied [11]. In one mandible we had found accessory mandibular foramen within the mandibular foramen, which had not been noted in previous studies (Fig. 4). The presence of accessory mandibular foramina within the mandibular foramen and mandibular canal leading from such accessory mandibular foramen, lead to failed inferior alveolar nerve block and unexpected hemorrhage. During early fetal life, the mandibular teeth are supplied by

three inferior alveolar nerves, which pass in their own canals in the mandible; fusion of these canals occurs during infantile period. Incomplete obliteration of these canals could be genesis of double or triple mandibular canals and accessory mandibular foramina as their point of entry [12]. Such bifid mandibular nerve could be responsible for inadequate nerve block [13].

The most common position of accessory mandibular foramina in this study was antero-superior to mandibular foramen (Table 3). Position of AMF in relation to mandibular foramen in dry mandible was reported sparsely. Freire et al. found 43.24% AMF superior to mandibular foramen and in 27.93% below the mandibular foramen [9]. We had not found any accessory mandibular foramen below the main mandibular foramen, suggesting racial variations in the distribution of accessory mandibular foramina. The second most common position of accessory mandibular foramina was found to be postero-superior to the mandibular foramen (Table 3). Such foramina were usually followed by a canal, known as Serres canal which is directed antero-inferiorly [13].

Accessory Innervation to the third lower molar tooth from early accessory branches of the inferior alveolar nerve is a clue to bifid inferior alveolar canals which indicate presence of retromolar foramen [10]. Presence of retromolar foramina is common variant in population (Table 5).

Table 5: Comparison of frequency of occurrence of retromolar foramen with previous studies.

Retromolar foramen	Shantaram [14]	Potu [15]	Suazo [13]	Present study	Senthil [16]	Narayana [17]
Total	5 (4.35%)	11 (11.7%)	38 (12.9%)	45 (15%)	26 (17.3%)	53 (21.9%)
Right side	2 (1.74%)	5 (5.3%)	14 (4.8%)	24 (8%)	8 (5.3%)	26 (10.7%)
Left side	2 (1.74%)	3 (3.2%)	13 (4.4%)	18 (6%)	6 (4%)	17 (7.1%)
Bilateral	1 (0.87%)	3 (3.2%)	11 (3.7%)	3 (1%)	12 (8%)	10 (4.1%)

The frequency of occurrence of retromolar foramina was 4.35% to 21.9% in different population. However, there is no statistically significant difference in the incidence of retromolar foramina between the sexes, but it was more prevalent among Native Americans than among subjects of European, Asian, African or Indian descent [10].

As retromolar foramen is frequently found and usually associated with additional mandibular

canals, complete inferior alveolar nerve block could be achieved by direct deposition of anaesthetic solution into the tissue of retromolar area [18].

CONCLUSION

Inferior alveolar nerve blocks are widely used in dental surgeries. Numerical variations of mandibular foramen, associated accessory canals with these additional foramina could lead to incomplete nerve block, which may lead to painful surgeries and prolonged operative time to achieve complete nerve block. Precise knowledge of presence of accessory mandibular foramina, their location in relation to mandibular foramen and study of associated mandibular canals reduces risk of incomplete nerve block, prevents iatrogenic injury to neurovascular structures, and may ease the work of dental surgeons.

Conflicts of Interests: None

REFERENCES

- [1]. Williams PL, Bannister LH, Berry MM, Collins P, Dyson M, Dussek JE, et al. The retromolar foramen. In: Williams PL, Bannister LH, Berry MM, Collins P, Dyson M, Dussek JE, et al., eds. Gray's anatomy 39th ed. London, UK: Churchill Livingstone: 2000: 481-483.
- [2]. Wong MK, Jacobsen PL. Reasons for local anesthesia failures. J Am Dent Assoc 1992;123(1):69-73.
- [3]. Claey's V, Wackens G. Bifid mandibular canal: literature review and case report. Dentomaxillofac Radiol 2005;34(1):55-58.
- [4]. Standring S. Gray's Anatomy: The Anatomical Basis of Clinical Practice. 41st ed. Elsevier. 2016: 539
- [5]. Jeyaseelan N, Sharma JK. Morphological study of unnamed foramina in North Indian human mandibles and its possible role in neurovascular transmission. Int J Oral Surg 1984;13(3):239-242.
- [6]. Potocnik I, Bajrovic F. Failure of inferior alveolar nerve block in endodontics. Endod Dent Traumatol 1999;15(6):247-251.
- [7]. Padmavathi G, Suman T, Varalakshmi KL, Roopashree R. An Anatomical Study of Mandibular and Accessory Mandibular Foramen in Dry Adult Human Mandibles of South Indian Origin. IOSR Journal of Dental and Medical Sciences 2014;13(4):83-88.
- [8]. Gupta S, Soni A, Singh P. Morphological study of accessory foramina in mandible and its clinical implication. Indian J Oral Sci 2013;4(1):12-16.
- [9]. Freire AR, Rossi AC, Prado FB, Caria PHF, Botacin PR. Incidence of the mandibular accessory foramina in Brazilian population. J Morphol. Sci 2012;29(3):171-173.

- [10]. Ossenberg NS. Retromolar foramen of the human mandible. *Am J Phys Anthropol* 1987;73(1):119-128.
- [11]. Samanta PP, Kharb P. Morphometric analysis of mandibular foramen and incidence of accessory mandibular foramen in adult human mandibles of an Indian population. *Rev Arg de Anat Clin* 2013;5(2):60-66.
- [12]. Chavez-Lomeli ME, Mansilla Lory J, Pompa JA, Kjaer I. The human mandibular canal arises from three separate canals innervating different tooth groups. *J Dent Res* 1996;75(8):1540-1544.
- [13]. Suazo GIC, Zavando MDA, Smith RL. Is the conduct of Serres an anatomical variation in adults? *Int J Morphol* 2009;27(1),43 47.
- [14]. Shantharam V, Manjunath KY, Aruna N, Shastri D. Retromolar foramen in South Indian mandibles. *Anatomica Karnataka* 2013;7(1):34-37.
- [15]. Potu BK, Kumar V, Salem AH, Abu-Hijleh M. Occurrence of the retromolar foramen in dry mandibles of South-Eastern part of India: a morphological study with review of the literature. *Anat Res Int* 2014;2014:1-5.
- [16]. Senthil Kumar S, Kesavi D. A study on the incidence of retromolar foramen and canal in Indian dried human mandibles and its clinical significance. *Int J Anatom Sci* 2010;1:14-16.
- [17]. Narayana Nayak UA, Ahmed WN, Bhat JG, Devaiah BA. The retromolar foramen and canal in south Indian dry mandibles. *Eur J Anat* 2002;6(3):141-146.
- [18]. Loizeaux AD, Devos BJ. Inferior alveolar nerve anomaly. *J Hawaii Dent Assoc* 1981;12(2):10-11.

How to cite this article:

Urvi H. Dave, Sunita Gupta, Rajesh B. Astik. CROSS SECTIONAL ANALYSIS OF OCCURRENCE OF ACCESSORY MANDIBULAR FORAMINA AND THEIR POSITIONAL VARIATIONS IN DRY MANDIBLES. *Int J Anat Res* 2019;7(1.1):6035-6039. **DOI:** 10.16965/ijar.2018.398