

Original Research Article

A CADAVERIC STUDY INDICATING CLINICAL SIGNIFICANCE OF RELATION BETWEEN AREA OF MENISCI WITH CORRESPONDING TIBIAL PLATEAU AND THAT OF DISTANCE BETWEEN ANTERIOR HORN AND POSTERIOR HORN OF MENISCI

Shital Bhishma Hathila ¹, Bharat J. Sarvaiya ^{*2}, V.H.Vaniya ³, Maitreyee Kulkarni ⁴.

¹ Assistant Professor, Anatomy Department, Medical College, Baroda, Gujarat, India.

^{*2} Associate Professor, Anatomy Department, P.D.U. Govt, Medical College, Rajkot, Gujarat, India.

³ Professor, Anatomy Department, Medical College, Baroda, Gujarat, India.

⁴ M.Sc. Medical Anatomy Part-2, Medical College, Baroda, Gujarat, India.

ABSTRACT

Background: Menisci play a pivotal role in functioning of knee joint. It contributes to the smooth movements of the joint by improving congruence, weight distribution and proprioception. The injuries of the menisci can disable as they lead to degenerative changes. Meniscal transplantation is latest of the adopted procedures in orthopedic surgeries. Therefore a thorough anatomical knowledge of the meniscal parameters is an essential need.

Objectives: The aim of the research was to study the variation in distance between anterior horn and posterior horn of menisci and to find out relation between area of the menisci and area of corresponding tibial plate.

Materials and Methods: The study was conducted on 60 Menisci (30 Lower Limbs) from donated dead bodies to Department of Anatomy, Medical college, Baroda. Data was analyzed statistically using student's t- test. P value < 0.05 is considered significant. Data is presented as mean \pm SD and analyzed with the help of Microsoft Excel.

Result: In the study it was observed that on the medial side the distance between anterior and posterior horns is 28.87 ± 1.06 mm whereas on the lateral side, is 12.60 ± 0.35 mm. The ratio between the areas of the menisci to the tibial plate was observed as 58% for medial and 54% for lateral menisci.

Conclusion: The anatomical knowledge of the dimensions of the menisci would prove to be helpful in guiding meniscal transplantation with allografts. It will be useful to various orthopedic surgeons, radiologists, forensic experts, anatomists and physiotherapists alike.

KEY WORDS: Medial Menisci, Lateral Menisci, Tibial Plateau, Horn of menisci, Meniscal transplant, Area of medial menisci, Area of lateral menisci.

Address for Correspondence: Dr. Bharat J. Sarvaiya, Associate professor, Anatomy department, P.D.U. Government Medical College, Rajkot, Gujarat, India. Mob No.9374284950

E-Mail: dr.bharatsarvaiya@yahoo.in

Access this Article online	Journal Information
Quick Response code  DOI: 10.16965/ijar.2018.441	International Journal of Anatomy and Research ICV for 2016 90.30 ISSN (E) 2321-4287 ISSN (P) 2321-8967 https://www.ijmhr.org/ijar.htm DOI-Prefix: https://dx.doi.org/10.16965/ijar 
	Article Information
	Received: 09 Dec 2018 Peer Review: 10 Dec 2018 Revised: None
	Accepted: 20 Jan 2019 Published (O): 05 Feb 2019 Published (P): 05 Feb 2019

INTRODUCTION

The anatomy is not a dead subject, it is living material out of which man, builds for the future

medicine. Knee joint is the largest of all the synovial joints in the body. It is a compound joint comprising of condylar Tibio-femoral articula-

tion separated by menisci and a saddle Patello-femoral articulation [1]. Tibia with shallow concave articulating surface receives femoral condyles, making an unequal approximation at the knee joint. Therefore any deviation in the insertion, shape and form among the lateral and medial menisci [Figure 1] automatically assume importance while considering the mechanisms of injury [2].

The strong bony insertion of anterior and posterior horns of menisci is significant to its function of load distribution. The importance of the intra-articular structures of the knee as well as its anatomical variations and abnormalities demand even more attention with the advent of newer techniques such as computed tomography (CT), arthroscopy and magnetic resonance imaging (MRI). Absence of the menisci can have devastating effects on the normal functioning of knee joint [3]. As the inability of a joint system to absorb shock has been implicated in the development of osteoarthritis, the meniscus would appear to play an important role in maintaining the health of the knee joint [4].

Therefore, today different approaches such as allografts, autografts, biodegradable collagenous scaffolds and permanent prosthesis are widely used and so adequate size, appropriate replacement material and anatomically correct position become crucial in determining success rate of such procedures involved in meniscal replacement. Even after meniscal transplantation improving contact mechanics, biomechanical function might not return to normal levels as obtaining a perfect size match allograft may become challenging [5]. So the aim of present study was to find out variation in distance between anterior horn and posterior horn of menisci, to find out relation between area of the menisci with area of corresponding tibial plate, to compare data among medial & lateral menisci and also to compare data among medial & lateral tibial plateau.

MATERIALS AND METHODS

The present study was conducted after having permission from the Institutional Ethics Committee for Human Research (IECHR) of Medical College Baroda in the department of anatomy, Medical College Baroda, Gujarat, India.

Total 60 Menisci from donated dead bodies to department were taken. All embalmed cadavers available were included in the study except the ones having history of prior surgeries of lower limb region and with musculoskeletal abnormalities in lower limb region. Data entry was done in Microsoft excel. Data was analyzed statistically using student's t- test. P values < 0.05 are considered significant. Data is presented as mean \pm SD and analyzed with the help of Microsoft Excel. The Menisci were removed after exposing the joint cavity [6] and collected in previously prepared formalin solution. Parameters of menisci were measured as mentioned below.

1. Distance between anterior & posterior horns (DAP): Distance between anterior and posterior horns (DAP) was measured by using digital vernier caliper with an accuracy of 0.01 mm which was placed between apex of anterior horn & apex of posterior horn [Figure 2]. Measurement was recorded in mm.

2. Area of menisci and area of tibial plateau: To calculate the area of menisci and tibial plates, the adopted method was the graph paper method. Draws of contours of the menisci and tibial plateau were obtained by using litmus paper. Then this area was measured using graph paper. Numbers of the small squares in the graph paper gives the area in mm².

Fig. 1: Dissected Menisci

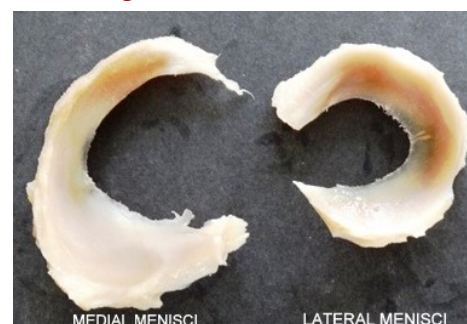

Fig. 2: Method To Measure Distance Between Anterior Horn And Posterior Horn Of Menisci.



OBSERVATIONS AND RESULT

In the present study total no of 60 menisci were studied, out of which 30 menisci were medial menisci and 30 menisci were lateral menisci. Data were presented as Mean \pm SD. Details of the observations made during the study are as follows.

In present study DAP of medial meniscus is 28.87 ± 1.05 mm and DAP of lateral meniscus is 12.6 ± 0.35 mm [Figure 3]. The observations were tested statistically by t- test and value is 80.13 with $P < 0.0001$ which shows highly significant difference between distance between anterior & posterior horn of medial and lateral menisci. It shows that anterior horn and posterior horn of lateral meniscus lies nearer to each other, which is responsible for round (four-fifth of a circle) shape of lateral menisci [Table 1].

In present study area of medial meniscus is 444.07 ± 37.22 mm² and area of lateral meniscus is 477.63 ± 36.42 mm² [Figure 4]. The observations were tested statistically by t- test and t-test value is 3.506 with $P < 0.0009$ which shows significant difference between area of medial and lateral menisci [Table 2].

Table 1: Comparison of DAP Of Medial And Lateral Menisci.

Observation	Medial menisci	Lateral Menisci
Mean	28.873	12.597
Standard Deviation	1.055	0.352
Statistical Parameter	t-test - 80.13, $P < 0.0001$	

Table 2: Comparison of Area Of Medial And Lateral Menisci.

Observation	Area of medial menisci (AMM)	Area of lateral menisci (ALM)
Mean	444.07	477.63
Standard Deviation	37.22	36.42
Statistical Parameter	t- test - 3.506, $P < 0.0009$	

Table 3: Comparison of Area Of Medial And Lateral Tibial Condyle.

Observation	Area of medial tibial condyle (AMTC)	Area of lateral tibial condyle (ALTC)
Mean	761.57	640.93
Standard Deviation	70.55	46.15
Statistical Parameter	t-test -17.65, $P < 0.05$	

In present study area of medial tibial condyle is 761.57 ± 70.55 mm² and area of lateral tibial condyle is 640.93 ± 46.15 mm² [Figure 5]. The

observations were tested statistically by t- test and t-test value is 17.65 with $P < 0.05$ which shows significant difference between area of medial tibial condyle and lateral tibial condyle [Table 3]. In present study medial menisci occupy 37% of medial tibial plate, while 63% tibial plate was not covered by menisci [Figure 6]. In present study lateral menisci occupy 43% of lateral tibial plate, while 57% tibial plate was not covered by menisci [Figure 7].

Fig. 3: Graph Showing Relation Of Distance Between Anterior And Posterior Horn Of Medial And Lateral Menisci.

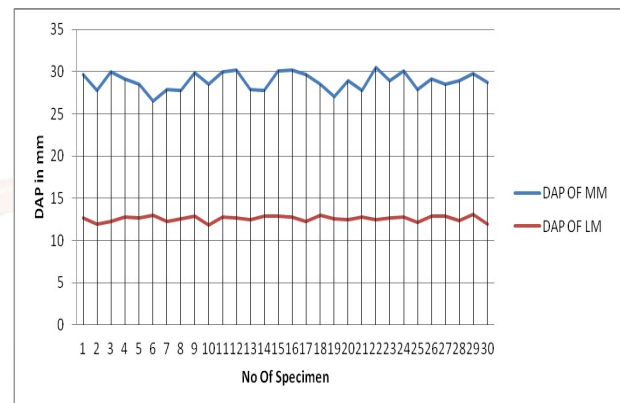


Fig. 4: Graph Showing Relation Between Area Of Medial And Lateral Menisci.

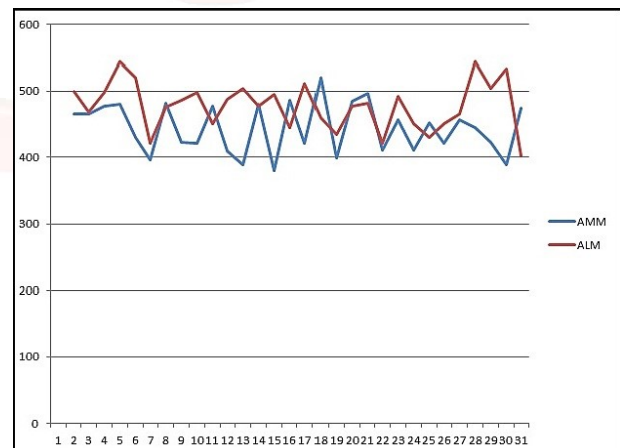


Fig. 5: Graph Showing Area Of Medial And Lateral Tibial Condyle.

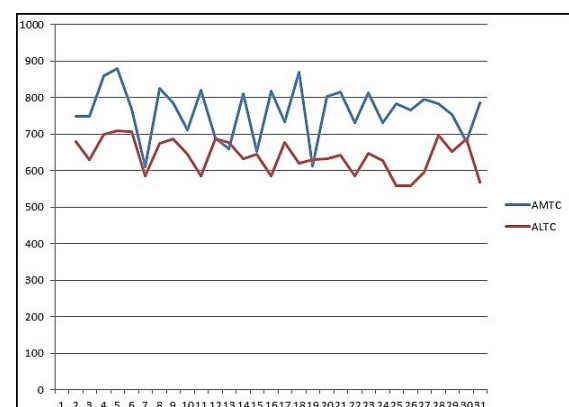


Fig. 6: The Ratio Of Area Of Medial Menisci Over Medial Tibial Plate.

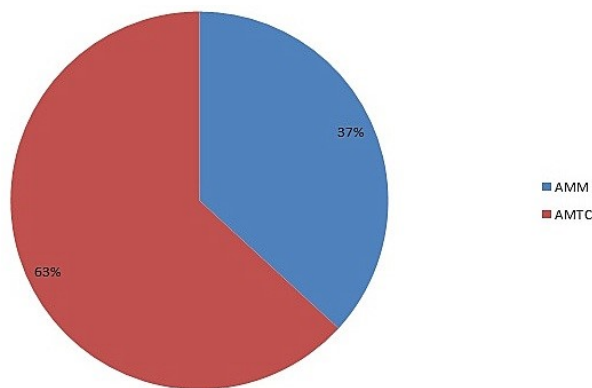
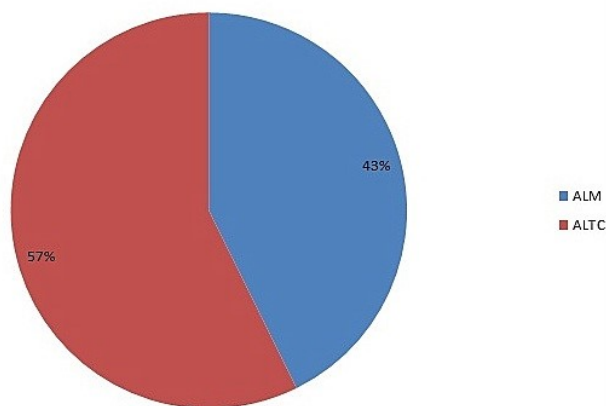


Fig. 7: The Ratio Of Lateral Menisci Over Lateral Tibial Condyle.



DISCUSSION

The incidence of osteoarthritis of knee as a consequence of sedentary lifestyle that often results in obesity has been growing in recent years. Thus, the morphological variations in menisci in particular the area of menisci with respect to corresponding tibial plateau and the distance between the anterior and posterior horns assumes greater significance and thus a study in this sense is need of hour.

Time and again different authors have studied the morphological parameters of menisci of the knee. The noteworthy among them are Veeresh Itagi et al in 2017 [2], Sonia Arunkumar Gupta et al in 2015 [3], Jyoti Rohila et al in 2017 [7], Gopal Chandra Mondal et al in 2017 [8], Rashmi B.N. et al in 2016 [9], Dr. Bharti Prabhakar Nimje et al in 2014 [10] and Wang Yong-jian et al in 2009 [11]. Present study compared the morphological parameters of menisci of knee joint with those of other authors and their observations are as mentioned.

In the present study, on the medial side [Tab. 4]

the distance between anterior and posterior horns is 28.87 ± 1.06 mm and on the lateral side [Table 5], is 12.60 ± 0.35 mm.

Wang et al [11] also report a similar observation the distance between the two horns on lateral side being 13.68 ± 2.19 mm. Likewise, the results of Rohila et al [7] are close to our observations as the distance between the anterior and posterior horn of the medial meniscus (32.5 ± 3.7 mm) was considerably more than that of the lateral meniscus (17.1 ± 4.0 mm).

The lateral meniscus forms an almost complete ring as compared to medial one which is crescent shaped. As there is a larger interruption between the horns of medial meniscus, it can be explained why the outer circumference measures showed no significant difference. Since the medial meniscus being apparently higher due to larger size of medial condyle of tibia, the menisci also has greater distance between its horns. On the other hand, the lateral meniscus has a smaller distance between its horns thus compensating for the difference in size of the tibial plateau, which is bordered by the menisci. The closeness of the horns thus protects the lateral menisci from frequent injuries [12].

Moreover, our current study indicates ratio of the area of the menisci and the tibial plate to be higher on the medial side (63%) as compared to the lateral (57%). This observation is consistent with that of Chintan et al [13] who reported it to be 72.62% on medial side and on lateral as 60.69% this discrepancy in the areas substantiates the frequent occurrence of medial meniscal injuries as it undergoes more exertion of femoral condyle.

Morphological characteristics of medial and lateral menisci are important for size matching method of allograft and also the positioning of the horns in allograft transplantation. However, there still is dearth of well accepted methods to choose a correct size matched allograft. Most tissue banks size the meniscus based on radiographic tibial plateau measurements. The most frequently employed method for preoperative sizing includes taking landmarks of meniscal horn insertions as the respective intercondylar eminence peak [11].

Table 4: Medial Menisci Morphological Study & Compare With Other Study.

	Sample size	Ratio of area of medial menisci & tibial plate	Distance between anterior and posterior horn(in mm)
Present study	30	63%	28.87 \pm 1.06
Braz et al [12]	20	Not Observed	25.88 \pm 3.33
Almeida et al [14]	22	54.70 \pm 7.32 %	29.70 \pm 4.12
Chintan et al [13]	50	72.62%	Not Observed
Narayan Rao et al [15]	100	Not Observed	31.8 \pm 0.33
Rohila et al [7]	100	Not Observed	32.5 \pm 0.37
Gopal et al [8]	50	Not Observed	29.02 \pm 0.9
Nimje et al [10]	30	88-90%	Not Observed

Table 5: Lateral Menisci Morphological Study & Compare With Other Study.

	Sample size	Ratio of area of lateral menisci & tibial plate	Distance between anterior and posterior horn (in mm)
Present study	30	54%	12.60 \pm 0.35
Braz et al [12]	20	Not Observed	12.55 \pm 1.98
Almeida et al [14]	22	48.67 \pm 4.43 %	12.71 \pm 1.84
Chintan et al [13]	50	60.69%	Not Observed
Narayan Rao et al [15]	100	Not Observed	12.6 \pm 0.98
Rohila et al [7]	100	Not Observed	17.1 \pm 0.40
Gopal et al [8]	50	Not Observed	12.72 \pm 0.748
Nimje et al [10]	30	80-83%	Not Observed

A properly placed graft will restore a sound knee biomechanics, thus ensuring better endurance of the allograft. Studies have found in the past positioning medial meniscal posterior horn tunnel more than 5 mm medial and 5 mm posterior to the designated location greatly changes the load distribution of the medial articular surface of the tibia [11]. Accurate measurements would aid judgment in meniscal replacement and regeneration procedures taken up in orthopedic surgeries [2].

CONCLUSION

Menisci play a significant role in knee biomechanics and are often injured leading to degenerative changes. The present study brings forth the significance of proper geometric size matching of tibial meniscal graft to the host knee after meniscectomy to evade graft failure due to mismatches in replacement surgeries. It can be easily assessed that a smaller sized graft runs a risk of getting trapped beneath oversized femoral condyle. Moreover, an oversized one will also not serve the function as it will fit loose around the femoral condyle and thus will be rendered ineffective. Present study has provided

a comprehensive set of quantitative measures of menisci and tibial plateau which may be of help for the construction of meniscal prostheses.

ABBREVIATION

AMM- Area of medial menisci

ALM- Area of lateral menisci

AMTC- Area of medial tibial condyle

ALTC- Area of lateral tibial condyle

DAP- Distance between anterior horn and posterior horn

ACKNOWLEDGEMENTS

The authors are heartily thankful to respected head of anatomy department and Institutional Ethics Committee for Human Research, Medical College, Baroda for allowing us to do study in department. We are also thankful to all faculties and supporting staff of anatomy departments as they help us in this study.

Conflicts of Interests: None

REFERENCES

- [1]. Gray's Anatomy – The anatomical basis of Clinical Practice by Susan Standring; 40th Edition; 1393-1410.

- [2]. Veeresh Itagi, Jayasudha Katralli, Veeresh kumar Somalingappa Shirol et al. Morphometric study of medial menisci of the adult knee joint. Indian Journal of Clinical Anatomy and Physiology, April-June, 2017;4(2):231-234.
- [3]. Soniya Arunkumar Gupta, Saiprasad Prabhakar Bhavsar, Medha V Ambiyee. Correlation of tibial meniscus with tibial plateau and its clinical significance: a cadaveric study . Int j anat res 2015;3(2):1073-1078.
- [4]. Alice J.S.Fox , Asheesh Bedi & Scott A Rodeo ; The Basic Science of Human Knee Menisci ; Structure ,Composition & Function ; Orthopaedic Surgery – Sport health 2012;4(4):340-351.
- [5]. Michael Dienst, Patrick E. Greis, Benjamin J. Ellis, Kent N. Bachus, Robert T. Burks et al. Effect of Lateral Meniscal Allograft Sizing on Contact Mechanics of the Lateral Tibial Plateau -An Experimental Study in Human Cadaveric Knee Joints. The American Journal of Sports Medicine, 35(1):34-42.
- [6]. Cunningham's Manual of Practical Anatomy Volume I (Upper limb and Lower limb); Fifteenth edition; 214-221.
- [7]. Rohila J, Rathee SK, Dhatarwal SK, Kundu ZS. Morphometric analysis of menisci of adult human knee joint in North Indian population. Int J Res Med Sci 2017;5:569-73.
- [8]. Dr. Gopal Chandra Mondal, Dr. Rajarshi Datta ,Dr. Asis Kumar Ghosal, Dr. Alipta Bhattacharya, Dr. Iman Sinha, Dr. Ratnadeep Poddar. Morphometric study of Menisci of Knee joints: A cadaveric study in an Eastern Indian Medical College. Indian Journal of Basic and Applied Medical Research; September 2017: Vol.-6; Issue- 4;172-182.
- [9]. Rashmi B.N, Dakshayani K.R, Vadiraja N. Morphometric Study Of Menisci Of Knee Joints In Adult Cadavers. Int J Anat Res 2016;4(4):2973-2978.
- [10]. Bharati Prabhakar Nimje & Bhuiyan. A Morphometric Study of Menisci of Knee Joint in Human Cadavers Int J Biol Med Res. 2014; 5(1): 3807-3809.
- [11]. WANG Yong-jian, YU Jia-kuo, LUO Hao, YU Chang-long, AO Ying-fang, XIE Xing, JIANG Dong and ZHANG Ji-ying. An anatomical and histological study of human meniscal horn bony insertions and perimeniscal attachments as a basis for meniscal transplantation. Chin Med J 2009;122(5):536-540.
- [12]. Braz, PRP and Silva, WG; Meniscus Morphometric Study in humans; J. Morphol. Sci. 2010; 27(2):62-66.
- [13]. Chintan R. Bhatt, Bhadrash Prajapati, Kuldeep Suthar, C. D. Mehta; Morphometric study of menisci of knee joint in the west region; International journal of basic and applied medical sciences 2014;4(1):95-99.
- [14]. Katiucia Samara da silva Almeida, Silva Regina Arruda de Moraes, Tetsuo Tashiro, Elizabeth da Silveria Neves, Ana Elisa Toscano, Roseanne Maria Rocha de Abreu; Morphometric study of menisci knee joint; Int. J. Morphol 2004;22(3):181-184.
- [15]. Narayan Rao, Anirban Das Gupta, A.V.Raju; Morphometric analysis of the menisci of the knee joint in population of east Godavari region of Andhra Pradesh; J. of Evolution of Med & Dent Sci 2014; 3(34):8972-8979.

How to cite this article:

Shital Bhishma Hathila, Bharat J. Sarvaiya, V.H.Vaniya, Maitreyee Kulkarni. A CADAVERIC STUDY INDICATING CLINICAL SIGNIFICANCE OF RELATION BETWEEN AREA OF MENISCI WITH CORRESPONDING TIBIAL PLATEAU AND THAT OF DISTANCE BETWEEN ANTERIOR HORN AND POSTERIOR HORN OF MENISCI. Int J Anat Res 2019;7(1.2):6198-6203. DOI: 10.16965/ijar.2018.441