

SHAPES OF MENISCI OF KNEE JOINT: A HUMAN CADAVERIC STUDY

Shashidhar *¹, Sridevi N.S ².

¹ Assistant Professor, Dept of Anatomy, Sri Devaraj Urs Medical College, Tamaka, Kolar, Karnataka, India.

² Professor, Dept of Anatomy, Sri Devaraj Urs Medical College, Tamaka, Kolar, Karnataka, India.

ABSTRACT

Background: The Medial and Lateral Menisci have very important roles in knee joint stability, functioning and dynamic loading and are thus important in maintaining proper joint health and stability.

Purpose: To estimate the incidence of various shapes of the Lateral and Medial Menisci which can throw light on its clinical significance on ligament injuries of knee joint.

Results: 50% Of the Medial Menisci were crescent- shaped, 37% were sided V-shaped and the remaining 13% were sided U-shaped. 72% of the Lateral Menisci were found to be C-shaped and 26% were crescent-shaped. One partial discoid lateral meniscus (2%) was observed.

Conclusion: The various morphological variants of Menisci determined in the study revealed that most common subgroup of the Medial Meniscus was crescentic type and that of Lateral Menisci was C shaped. A single specimen of partial Discoid Lateral Meniscus was observed which is of rare occurrence.

Implications: The present study contributes to proper understanding of anatomy of both Medial and Lateral Menisci which can be helpful in planning various surgical procedures including meniscal transplantation. This knowledge also helps in understanding degenerative diseases affecting knee joint Menisci. Discoid Lateral Meniscus, a rare anomaly which was reported in the present study is clinically important because of its higher incidence of meniscal tears.

KEY WORDS: Medial Meniscus, Lateral Meniscus, Crescentic, Sided V, Sided U, Knee Joints.

Address for Correspondence: Dr. Shashidhar, Assistant Professor, Dept of Anatomy, Sri Devaraj Urs Medical College, Tamaka, Kolar, Karnataka, India. **E-Mail:** shashik1304@gmail.com

Access this Article online	Journal Information
Quick Response code  DOI: 10.16965/ijar.2018.451	International Journal of Anatomy and Research ICV for 2016 90.30 ISSN (E) 2321-4287 ISSN (P) 2321-8967 https://www.ijmhr.org/ijar.htm DOI-Prefix: https://dx.doi.org/10.16965/ijar 
Article Information	
Received: 24 Dec 2018	Accepted: 20 Jan 2019
Peer Review: 25 Dec 2018	Published (O): 05 Feb 2019
Revised: None	Published (P): 05 Feb 2019

INTRODUCTION

The Menisci of knee joint are crescentic laminae of fibrocartilage on the articular surface of the tibia that deepen the articulation of tibial surface of femur. The Menisci are thicker and convex at their outer margins while the inner free margins are thin and concave. The Medial Meniscus is broad and semicircular in shape. The Lateral Meniscus is nearly circular and more freely movable than the Medial

Meniscus. The Medial and Lateral Menisci serve very important roles in knee stability, function and dynamic loading and are thus important in maintaining proper joint health[1]. The menisci also facilitate nutrition, provide lubrication and shock absorption for articular cartilage and promote knee proprioception.

The Medial and Lateral Menisci although similar in function have minor differences in their shape and thus their biomechanical role in the

knee. The function of stabilization, mainly the rotational, is one of the most important and is directly related to the meniscal injuries. There are marked differences in the contour and insertion between the Lateral and the Medial Menisci which are important in relation to the injury mechanisms. The present study was carried out to estimate the incidence of various shapes of the lateral and medial Menisci as this knowledge on variations in shape of Menisci has its clinical significance in determining the possibility and the kind of knee joint injuries.

MATERIALS AND METHODS

This is a Descriptive study in which 100 menisci from 50 adult cadaveric knee joints, preserved in formaldehyde solution were included in the study. The knee joint was opened by turning the patella downwards. The ligaments of knee joint were identified and the fibrous capsule was opened. The synovial membrane and surrounding connective tissue was removed. The Cruciate ligaments (anterior and posterior) were identified and divided. The proximal surface of the tibia and the menisci were visualized by cutting the remains of the fibrous capsule and surrounding connective tissues. The anterior and posterior horns of the Medial and Lateral Menisci were identified and their attachments to the tibia defined. The Medial and Lateral Menisci were dissected out intact by dividing their attachments to the tibia. The morphological variants of the shapes of Medial and Lateral menisci were noted and classified.

RESULTS AND DISCUSSION

The position and attachment of the Meniscus to the tibial surface was studied and the Medial and Lateral Menisci was sub grouped accordingly. The following subgroups were classified based on Kale A et al [2]. The Medial Menisci were subgrouped as crescentic, sided U, sided V and C shaped. The Lateral Menisci were subgrouped as C shaped, Crescentic and Discoid types. The complete occupancy of the tibial plateau by the Meniscus in circular fashion was noted as Discoid type of Meniscus. The other types (Cshaped, sided U, Sided V, crescentic, etc.) were indicated as they occupied the tibial articular surface.

The observations made in the present study are given below. Table 1 shows subgroups of medial menisci and photographs of the medial and lateral menisci showing various shapes of the medial menisci are shown in Fig 1, Fig 2 and Fig 3. There is also a graphical representation of subgroups of medial menisci (graph 1).

Table 1: Sub groups of Medial Menisci.

Shape	Number
Crescentic	24
Sided U	7
Sided V	19
C shaped	Nil
Total	50

Fig. 1: Medial and Lateral Menisci of Left Knee with Crescentic Medial Meniscus.

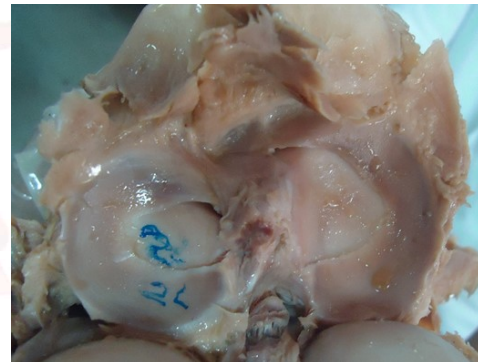


Fig. 2: Medial and Lateral Menisci of Left Knee with sided U Medial Meniscus.

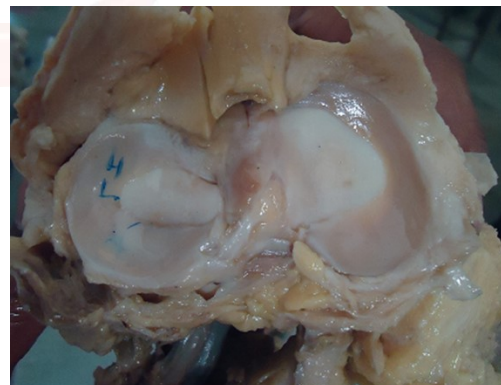
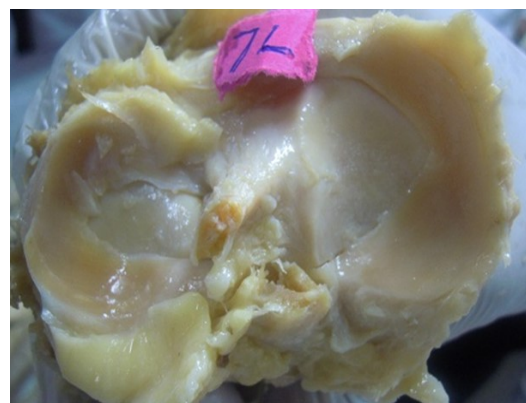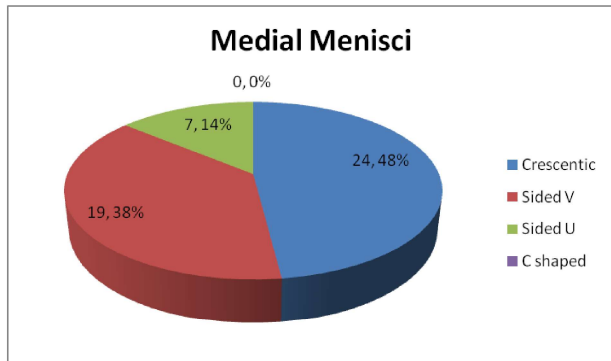


Fig. 3: Medial and Lateral Menisci of Left Knee with sided V shaped Medial Meniscus.

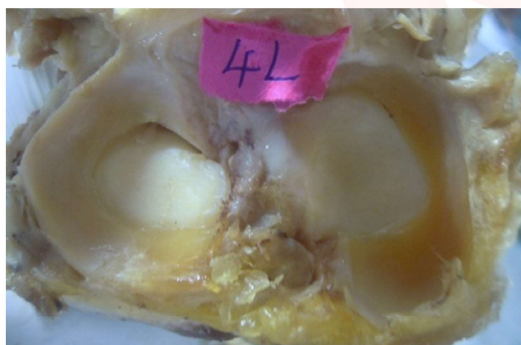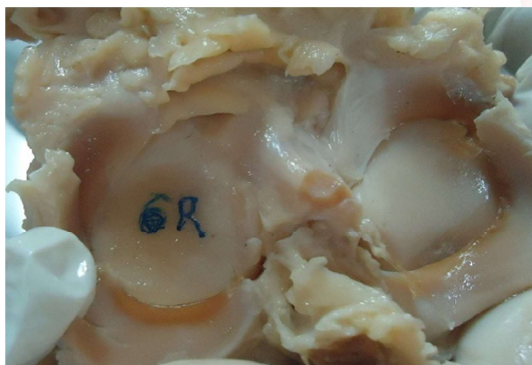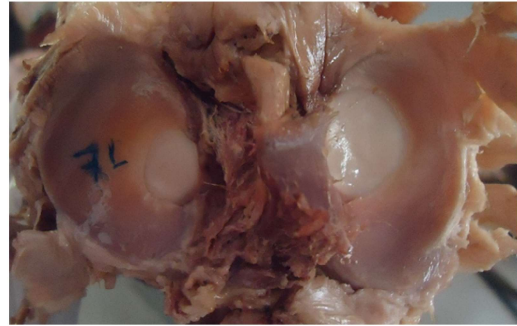
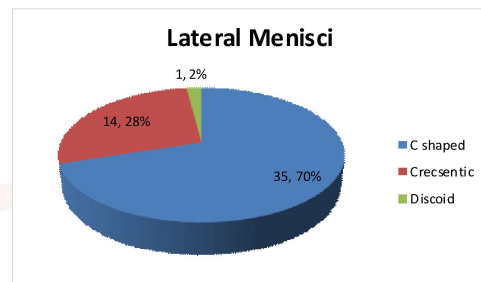


Graph 1: Piechart showing subgroups of Medial Menisci.

In the present study, the subgroups of Medial Menisci observed were Crescentic type in 24 (48%), Sided V in 19(38%) and Sided U in 7(14%). Table 2 shows subgroups of lateral menisci and photographs of the medial and lateral menisci showing various shapes of the lateral menisci are shown in Fig 4, Fig 5 and Fig 6. There is also a graphical representation of subgroups of lateral menisci (graph 2).

Table 2: Subgroups of Lateral Menisci.

Shape	Number
C shaped	35
Crescentic	14
Discoid	1
Total	50

Fig. 4: Medial and Lateral Menisci of Left Knee showing C shaped Lateral Meniscus.**Fig. 5:** Medial and Lateral Menisci of Right Knee showing Crescentic Lateral Meniscus.**Fig. 6:** Medial and Lateral Menisci of left Knee showing incomplete Discoid Lateral Meniscus.**Graph 2:** Pie Chart showing distribution of subgroups of Lateral Menisci.

The Lateral Menisci were subgrouped as C shaped in 36(72%), Crescentic in 14(28%) and Discoid in 1 (2%).

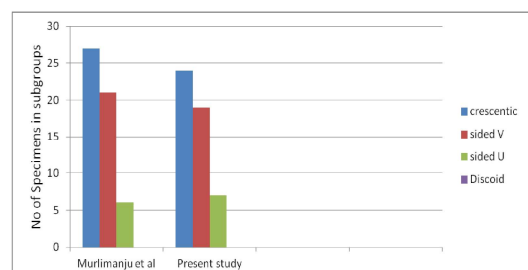
Murlimanju et al in 2010 studied shapes of Menisci and reported Medial Menisci as Crescentic in 50%(27) specimens, Sided V in 38.9%(21), Sided U in 11.1%(6) and no Discoid Medial Meniscus out of 54 specimens[3].

The table below (table 3) shows the comparison of the present study with that of Murlimanju et al study.

Table 3: Comparison of shapes of Medial Menisci.

Study	Crescentic	Sided V	Sided U	Discoid	Total (n)
Murlimanju et al 2010 [3]	27(50%)	21(38.9%)	6(11.1%)	Nil	54(100%)
Present study	24(48%)	19(38%)	7(14%)	Nil	50(100%)

As evident in the table above, the incidence of different shapes of medial menisci seen in both the studies were similar and thus the findings in the present study were in accordance with Murlimanju et al. study (as depicted in graph 3).

Graph 3: Comparison of subgroups of Medial Menisci.

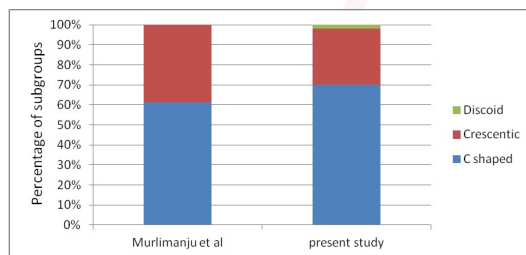
Similarly, Murlimanju et al also reported the sub groups of Lateral Menisci as C shaped in 61.1% (33) specimens, Crescentic in 38.9% (21) specimens. However, there were no Discoid Menisci out of 54 specimens [3].

Table 4 shows the comparison of the present study with that of Murlimanju et al study.

Table 4: Comparison of shapes of Lateral Menisci.

Study	C shaped	Crescentic	Discoid
Murlimanju et al 2010 [3]	33(61.1%)	21(38.9%)	0 (0%)
Present study	35(70)	14(28%)	1(2%)

Graph 4: Comparison of subgroups of Lateral Menisci.



As evident in the graph 4, although the incidence of C shaped and crescentic shaped lateral menisci were similar in both studies, 1 Discoid Lateral Meniscus was noted among 50 cadavers (2%) in the present study unlike Murlimanju et al study. Another study conducted by Rashmi in 2016 also had no discoid shaped menisci among 50 cadavers studied [4]. However, Kaplan in 1957 also had found that only one cadaver had bilateral discoid menisci among 6 cadaveric knee joints studied [5].

Young in 1889 first described the Discoid Lateral Meniscus [6]. Dickhaut and DeLee in 1982 described Discoid Lateral Meniscus as a morphological variable and concluded that Discoid type of Lateral Meniscus had a role in causation of abnormal mobility and caused symptoms in patients. [7]

Ibertsson and Gillquist in 1988 studied 7,056 knee arthroscopies, 30 of which had discoid menisci, 29 Discoid Lateral Menisci and one Discoid Medial Meniscus [8]. Ashwini et al in 2012 studied a case of unilateral Discoid Lateral Meniscus in an adult cadaver and reported that Discoid Lateral Meniscus is a rare anomaly which is clinically important because of its higher incidence of meniscal tears [9].

CONCLUSION

The present descriptive research was carried out

to study the shapes of menisci of knee joint. It was found that crescentic shape was the commonest among medial menisci. Further the Lateral Menisci were found to have C shaped as the most common type. The characteristic finding observed was incomplete Discoid Lateral Menisci in one specimen of Left sided Lateral Meniscus which is a rare occurrence.

The study provides information on the different shapes of the Medial and Lateral Menisci which contributes to proper understanding of anatomy of both Medial and Lateral Menisci. The anatomical variations of the structures of the knee joint have recently become significant because of recent imaging techniques such as arthroscopy, computed tomography and magnetic resonance imaging. Further this study can be helpful for the Orthopedicians in the understanding of degenerative diseases affecting knee joint Menisci as these diseases affect the shapes of the Menisci.

The emergence of Meniscal transplantation in meniscal injuries has revolutionized the treatment modalities, the size and shape of the meniscus being very important. There are tissue banks available for selecting donor Menisci for transplantation. Meniscus allograft transplantation is an established surgical treatment for patients with subtotal or total meniscectomized knees, providing both pain relief and functional improvement which requires knowledge about the shapes of menisci and their variations. Normal anatomic features, such as the meniscotibial ligament and popliteo-meniscal fascicle, are inherent limitations of meniscus allograft transplantation. Both structures function to anchor the meniscus, reducing the risk of graft extrusion [10]. Hence it is important to be aware of the normal shapes of menisci and its variations.

As this is a cadaveric study it can be recommended that clinicians can use arthroscopy of knee joint to assess the dimensions of the Menisci in the cases attending the outpatient department.

ACKNOWLEDGEMENTS

I am grateful to the Department of Anatomy Sri Devaraj Urs Medical College, Kolar for allowing me to conduct this study. I would like to acknowl-

edge Dr Sridevi N S, Prof and HOD, Dept of Anatomy, Sri Devaraj Urs Medical College, Kolar for support and guidance.

Conflicts of Interests: None

REFERENCES

- [1]. Susan Standring. Gray's Anatomy, The Anatomical Basis of Clinical Practice. 40th ed. Elsevier Churchill Livingstone Publications; 2008: Chapter 82
- [2]. Aysin Kale, Cem Kopuz, Mete Edýzer, MennanEce Aydin, Mehmet Demýr,YenerYnce. Anatomic variations of the shape of the menisci: a neonatal cadaver study. Knee Surg Sports TraumatolArthrosc. 2006 Oct; 14(10):975-81.
- [3]. B.V. Murlimanju, Narga Nair, Shakuntala Pai, Mangala Pai, Chethan P, Chandni Gupta. Morphological study of the Menisci of the Knee joint in adult cadavers of the South Indian population. Marmara Medical Journal 2010;23(2);270-275.
- [4]. Rashmi B.N, Dakshayani K.R, Vadiraja N. Morphometric study of menisci of knee joints in adult cadavers. Int J Anat Res 2016;4(4):2973-2978.
- [5]. Kaplan EB. Discoid lateral meniscus of the knee joint. J Bone Joint Surg Am 1957; 39A: 77-87.
- [6]. Young R. The external semilunar cartilage as a complete disc. In: Cleland J, Young R, eds. Memoirs and Memoranda in Anatomy. London: Williams and Norgate 1889:179.
- [7]. Dickhaut SC, DeLee JC. The discoid lateral meniscus syndrome. J Bone Joint Surg Am 1982; 64: 1068-1073.
- [8]. Albertsson M, Gillquist J. Discoid lateral menisci: a report of 29 cases. Arthroscopy 1988; 4: 211-214.
- [9]. C Ashwini, CM ,Nanjaiah, GS Saraswathi. Complete Unilateral Discoid Lateral
- [10]. Meniscus in an Adult Cadaver: A Case Report. International Journal of Current Research and Review 2012;4(16).
- [11]. Dae-Hee Lee. Incidence and Extent of Graft Extrusion following MeniscusAllograft Transplantation. Hindawi BioMed Research International Volume 2018, Article ID 5251910, 11 pages. <https://doi.org/10.1155/2018/5251910>

How to cite this article:

Shashidhar, Sridevi N.S. SHAPES OF MENISCI OF KNEE JOINT: A HUMAN CADAVERIC STUDY. Int J Anat Res 2019;7(1.2):6239-6243.
DOI: 10.16965/ijar.2018.451